

# A Case Report for a Mortality Following Kyphoplasty: Suggested Method of Prevention

Anthony R Oddo<sup>1\*</sup>, Jessica Lee<sup>2</sup>, and James T Lehner<sup>2</sup>

<sup>1</sup>Boonshoft School of Medicine, Wright State University, Dayton, USA

<sup>2</sup>Department of Orthopaedic Surgery, Wright State University, Dayton, USA

## Abstract

**Study design:** A case report and review of literature.

**Objective:** To discuss the implementation of a bilateral cannula venting technique to prevent perioperative mortality and morbidity related to kyphoplasty.

**Summary of background data:** Several authors have suggested various recommendations for techniques to lower complications related to kyphoplasty, such as specific cement types, consistencies, volumes, and intravertebral pressures. However, there are few commentaries regarding venting during kyphoplasty as a method to reduce complications, such as embolism.

**Methods:** A 69-year-old male suffered acute cardiac decompensation and arrest during a kyphoplasty procedure, ultimately resulting in his death.

**Results:** Autopsy report from the coroner's office revealed the cause of death as a pulmonary fat and bone marrow embolism. In response to this event, the attending physician and his partners began venting during the kyphoplasty procedure, using a bilateral cannula technique.

**Conclusion:** The bilateral venting modification has been adopted as the standard of practice with the senior author and his local colleagues. Since implementing this technique, the group of surgeons has successfully performed over 1000 kyphoplasty surgeries without any resulting in perioperative mortality or morbidity.

**Keywords:** Kyphoplasty; Mortality; Compression fracture; Transpedicular approach; Complications; cement; Intravertebral pressure; Venting; Embolism; Perioperative

## Introduction

Kyphoplasty is the standard of care to increase vertebral height, reduce pain, improve mobility and function in the treatment of osteoporotic vertebral compression fractures [1-3].

Although successful outcomes are reported well over 90%, complications reported in the literature include cement leakage, infection, neurologic complication, hemorrhage, and pulmonary embolism [4,5].

New strategies have been employed to reduce complication rates, such as more viscous cement, specifically with an altered monomer-to-powder [6,7]. Overall, kyphoplasty restores vertebral height well, and the complication rates are low [8].

## Case Presentation

A 69-year-old male has a known past medical history of chronic obstructive pulmonary disorder, carcinoma of the lung surgically treated with partial left lung resection, and acute inferolateral myocardial infarction managed conservatively with aspirin and beta blockers. He underwent uncomplicated multilevel kyphoplasty from vertebral compression fractures at the levels of T9 to L1, and the patient went home the same day without complication.

Two weeks after his procedure, the patient experienced a traumatic back pain when he was rising from a commode. A MRI demonstrated a L4 compression fracture and a decision was made to perform kyphoplasties from L2-L4 (Figure 1).

During the procedure, the patient was positioned prone under general anesthesia and standard transpedicular approach has been utilized to access the vertebral bodies posteriorly. Balloon reduction for all six sites accommodated 6 cc of volume with low recorded pressures

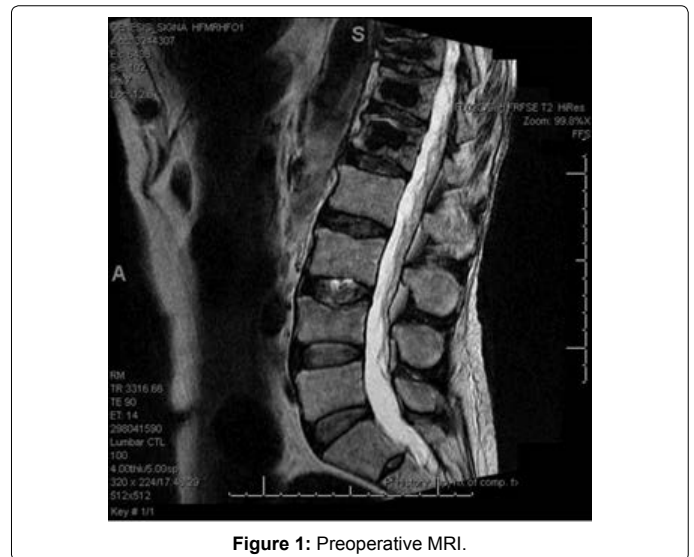

Figure 1: Preoperative MRI.

(Figure 2). A minimal amount of cement (estimated <3cc on each side) was injected at L3 and L4 whereupon the surgeons were notified of acute cardiac decompensation and arrest by the anesthesiologists (Figure

**\*Corresponding author:** Anthony Oddo, Wright State University, Boonshoft School of Medicine, 3640 Colonel Glenn Highway Dayton, 35 S. St. Clair Street Apt 207, Dayton OH 45402, USA Tel: 704-995-6661; E-mail: [Oddo.2@wright.edu](mailto:Oddo.2@wright.edu)

**Received** April 17, 2017; **Accepted** May 05, 2017; **Published** May 10, 2017

**Citation:** Oddo AR, Lee J, Lehner JT (2017) A Case Report for a Mortality Following Kyphoplasty: Suggested Method of Prevention. *Surgery Curr Res* 7: 295. doi: [10.4172/2161-1076.1000295](https://doi.org/10.4172/2161-1076.1000295)

**Copyright:** © 2017 Oddo AR, et al. This is an open-access article distributed under the terms of the Creative Commons Attribution License, which permits unrestricted use, distribution, and reproduction in any medium, provided the original author and source are credited.

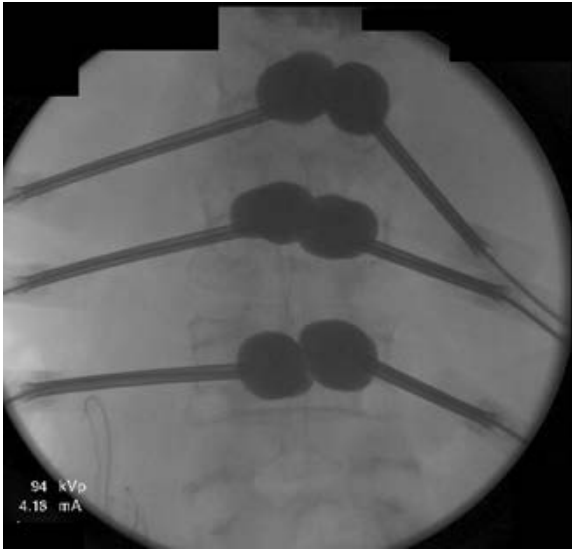


Figure 2: Inflating the balloons.

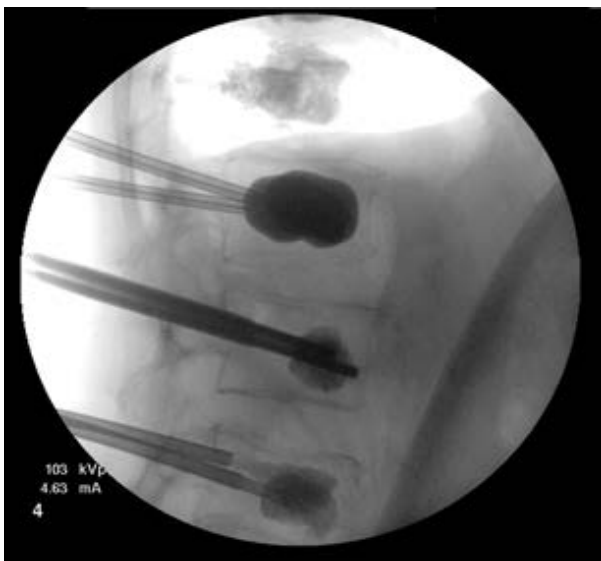

Figure 3: Injecting from both sides.

3). The patient had all 6 cannulas removed; the wounds were dressed and the patient turned for immediate cardiopulmonary resuscitation. Despite best efforts to revive the patient, he was declared dead after 20 minutes of attempted cardiopulmonary resuscitation.

## Results

Autopsy report obtained from the coroner's office cited the cause of death as a pulmonary fat and bone marrow embolism. Upon gross examination of the lung sections, the pulmonary arteries were noted to be free of thromboemboli and patent, and no cement emboli were found. Microscopic examination revealed a fat and bone marrow embolism. This suggests that a majority of the embolism passed and/or dissolved.

## Discussion

In a study identifying 858,978 vertebral compression fracture

patients in a Medicare population, the operative cohort, comprised of 119,253 kyphoplasty patients and 63,693 vertebroplasty patients, respectively, demonstrated a 37% higher survival rate at four years follow up. Within the operative cohort, the kyphoplasty group demonstrated a 7.29% higher adjusted survival rate at 3 years compared to the vertebroplasty group [9]. Increased survivorship of patients who have undergone operative management of vertebral compression fractures suggests that the benefits of kyphoplasty outweigh the minimal risks the procedure yields.

In a cadaveric study specifically measuring the intravertebral pressures, it was noted that central vertebral pressure was significantly higher in vertebroplasty compared to kyphoplasty. However, a relative increase was consistently reported at the late phase when the injected volume was noted to exceed volume of the cavity created with the balloon tamps [10,11]. In contrast, Ryu et al. suggests that the etiology of cement leakage is multifactorial and not only related to increasing intravertebral pressure [12]. Although restoration of vertebral height and the creation of a potential space in balloon kyphoplasty decreases the needed pressure to inject cement, leakage may occur once the intravertebral pressures approach the endpoints achieved by the end of the procedure.

The suggested method of avoiding increased end injection pressure is to leave cannulas in both pedicles during cement injection. The cement is injected through the "inlet" cannula on one side, allowing the blood and fat to escape through the second "outlet" cannula on the opposite side. This venting is reminiscent of the older venting technique used with early style cementing of the femoral prosthesis in early total hip arthroplasty procedures [13]. When cement creeps up the outflow cannula, the surgeon recognizes the endpoint of cement injection and withdraws both cannulas; allowing the cement to cure in situ. It is thought that an "outlet cannula" prevents intravertebral pressure gradients from approaching the maximums yielded by Wiesskopf et al. [10].

## Conclusion

Control of cement extravasation and prevention of embolism is especially important in a medically tenuous population with minimal cardiopulmonary reserve. The venting modification has since been adopted as the local standard of practice, and the authors, combined with their local colleagues, have collectively performed in total over 1000 kyphoplasties without any resulting in perioperative mortality or morbidity.

## Conflict of Interest

No conflict of interest.

## References

1. Xing D, Ma JX, Wang J (2013) A meta-analysis of balloon kyphoplasty compared to percutaneous vertebroplasty for treating osteoporotic vertebral compression fractures. *J Clin Neurosci* 20: 795–803.
2. Goz V, Koehler SM, Egorova NN, Moskowitz AJ, Guillaume SA, et al. (2011) Kyphoplasty and vertebroplasty: trends in use in ambulatory and inpatient settings. *Spine J* 11: 734–744.
3. Garfin SR, Reilly MA (2002) Minimally invasive treatment of osteoporotic vertebral body compression fractures. *Spine J* 2: 76–80.
4. Daramond H, Depriester C, Galibert P (1998) Percutaneous vertebroplasty with polymethylmethacrylate: technique, indications, and results. *Radiol Clin North Am* 36: 533-546.
5. McArthur N, Kasperk C, Baier M, Tanner M, Gritzach B, et al. (2009) 1150 Kyphoplasties over 7 years: Indications, techniques, and intraoperative complications. *Orthopedics* 32: 2.

6. Radcliff KE, Reitman CA, Delasotta LA, Hong J, Dilorio T, et al. (2010) Pulmonary cement embolization after kyphoplasty: A case report and review of the literature. *Spine J* 10: 1–5.
7. Monticelli F, Meyer HJ, Tutsch-Bauer E (2005) Fatal pulmonary cement embolism following percutaneous vertebroplasty (PVP). *Forensic Sci Int* 149: 35–38.
8. Truumees E (2008) Vertebroplasty and kyphoplasty: Complications and their management. *Spine Surgery* 20: 53–66.
9. Edidin AA, Ong KL, Lau E, Kurtz SM (2011) Mortality risk for operated and nonoperated vertebral fracture patients in the medicare population. *J Bone Miner Res* 26: 1617-1626.
10. Weisskopf M, Ohnsorge JA, Niethard FU (2008) Intravertebral pressure during vertebroplasty and balloon kyphoplasty: An *in vitro* study. *Spine* 33: 178-182.
11. Reidy D, Ahn H, Mousavi P (2003) A biomechanical analysis of intravertebral pressures during vertebroplasty of cadaveric spines with and without simulated metastases. *Spine* 28: 1534-1539.
12. Ryu KS, Huh HY, Jun SC, Park CK (2009) Single-balloon kyphoplasty in osteoporotic vertebral compression fractures: Far lateral extrapedicular approach. *J Korean Neurosurg Soc* 45: 122-126.
13. Johnes RH (1975) Physiologic emboli changes observed during total hip replacement arthroplasty. *Clin Orthop Relat Res* 112: 192-200.