Surgery: Current Research

Sanches. Surgery Curr Res 2015, 5:2
DOI: 10.4172/2161-1076.1000230

Case report

Open Access

Case Report: Moderately Differentiated Ulcerated Gallbladder Squamous Cell Carcinoma

Karina Prado Sanches, Anderson Kaio Bento Gil, Victor Herling da Costa and Fernando Leal Pereira*

UNESC University, Brazil

Abstract

Objectives: To enrich the scant scientific evidence existing on this subject. Rationale: Because of this rarity of information, works like this one are indispensable for the scientific, academic and professional community by dealing with an uncommon theme with unique features.

Methodology: This study was done with access to the BIREME database, as well as reviewing the patient's chart. **Case description:** woman, 71 years old, morbidly obese with of BMI 42, complaining of pain in the right hypochondrium for ten days, positive Murphy's sign, but without peritonitis markings. An ultrasonography of the abdomen showed gallstones with wall thickening suggestive of neoplasia. Underwent surgery after clearing the infection. During surgery, discovered the gallbladder was covered by omentum, blocked by the transverse colon and duodenum. Having cleared the adhesions, performed cholecystectomy segmentectomy and the anterior portion of segments IV and V after confirmation of malignancy freezing. The histopathological (HE and immunohistochemistry) of the surgical specimen pointed to ulcerated carcinoma moderately differentiated squamous cells.

Discussion: squamous cell carcinomas are rare, thus creating sparse and sometimes diversive literature. Usually diagnosed in advanced stages as in the early stages it is considered to be a silent disease. The patient had typical clinical cholecystitis without evidence of weight loss or palpable bladder, in agreement with the literature, in which case most diagnoses are intraoperative, because of the similarity of the clinical picture. The biological behavior of squamous cell cancer is characterized by rapid growth, early metastatic spread and features local and regional infiltration, which also happened to the patient, described being found intraoperatively covered by omentum gallbladder, blocked by the transverse colon and duodenum, beyond the liver involvement, after confirmation by freezing. Although the patient in question had increased GGT present in their examinations, the involvement of the biliary tract was not evident.

Conclusion: The reported case and cited publications lead to the conclusion that its being a rare histological type, and thus without extensive literature, a lot of data such as the actual outcome of these patients and the survival time are underestimated and difficult to locate meaningful data.

Keywords: Gallbladder neoplasms; Gallbladder; Carcinoma; Squamous cell

Introduction

Gallbladder neoplasia is a relatively rare disease, despite being the most common tumor of the biliary tract and the fifth most frequent in the gastrointestinal tract. It features a high mortality rate because most of the time the patient present nonspecific symptoms and are already in advanced stages. Most diagnoses are made incidentally in patients who are undergoing exploration of bile ducts by cholecystitis/cholelithiasis – around 1 to 2% of these are diagnosed as having pathological galbladder neoplasia [1].

Gallbladder cancer is the fifth most common gastrointestinal malignancy, with about 5,000 new cases diagnosed each year in the United States. It is more common in women than in men at a ratio of 2/3:1 in part because a higher incidence of gallstones in women [2].

About ninety eight percent of the gallbladder tumors are of epithelial origin, more than ninety percent adenocarcinoma, squamous carcinoma types (adenosquamous carcinoma or squamous cell carcinoma) are rare, with a prevalence of about 1.4% to 10.6% in relation to all other types of gallbladder cancer. Because of its rarity, there are few literary descriptions of the clinical and biological behavior of this type of tumor [3].

Overall, there is a prominent geographical variability in the incidence of gallbladder carcinoma (GBC). High gallbladder carcinoma rates are seen in South American countries, especially Chile, Bolivia and Ecuador, as well as some areas of India, Pakistan, Japan and Korea. In Chile, GBC mortality rates are the highest in the world, where it is the most common type of cancer that affects women and is the leading cause of cancer death among women [4].

Gallbladder cancer manifests itself most often with abdominal pain in the right upper quadrant, generally mimicking cholecystitis and cholelithiasis. Weight loss, jaundice and a palpable abdominal mass are less common symptoms. About 40% of patients have the symptoms of chronic cholecystitis present. Another common manifestation is similar to acute cholecystitis, with sharp pain associated with vomiting, fever and localized discomfort [2].

Jaundice, ascites, and duodenal obstruction are associated with irresectability in 85% of the times [5].

Most carcinomas of the gallbladder have one of three types of macroscopic growth: infiltrative, papillary, or mucinous, with infiltrative being the most common. Tumor dissemination starts

***Corresponding author:** Fernando Leal Pereira, Associate Professor, UNESC University, Brazil, Tel. 48- 99-465-051; E-mail: antonini_fernando@hotmail.com

Received January 07, 2015; **Accepted** May 08, 2015; **Published** May 15, 2015

Citation: Sanches KP, Gil AKB, Costa VHD, Pereira FL (2015) Case Report: Moderately Differentiated Ulcerated Gallbladder Squamous Cell Carcinoma. Surgery Curr Res 5: 230. doi:10.4172/2161-1076.1000230

early to the lymph nodes, splanchnic nerves along the bile ducts for peritoneal implantation, to the liver and the lung [5].

Abdominal ultrasound is the preferred imaging examination for visualization of the biliary tree. Computed tomography (CT), ERCP, and angiography can be used to stage and plan treatment, however the laparotomy must be made so that the fabric can be analyzed for pathology, diagnosis confirmation, and definition of the extent of the disease [6].

The CA 19.9 antigen in gallbladder cancer diagnosed patients has a sensitivity of 55% and specificity of 99%. But CEA (carcinoembryonic antigen) has been used as diagnostic and prognostic marker in galbladder cancer (CA), however there is no relationship of this marker with survival time and no significant difference was observed between serum levels among patients who have bladder CA in patients with only cholelithiasis [5].

In the study by Kalayarasan, patients with the pathological squamous cell carcinoma (adenosquamous carcinoma and squamous carcinoma) always had levels of tumor markers such as CEA and CA 19.9 lower than compared to patients with adenocarcimona [3].

The treatment of this disease is closely related to the stage of the disease. If the disease is located, surgical resection offers results in a prolonged survival in some patients. However, if the disease is advanced or metastatic it is appropriate to use systemic treatment – with chemotherapy as a treatment [7].

Surgery is the only treatment with chance of cure. Only 1/3 of patients taken to surgery will have their tumor resected, and the overall 5-year survival with resected tumors is around 16.5%. Chemotherapy may be used in cases of advanced disease, and have varying degrees of response [5].

Tumors confined to the mucosa or submucosa or confined to gallbladder muscle are identified after cholecystectomy as calculus disease and has an overall survival rate of 100% and 85% respectively, in five years. So for T1 stage, cholecystectomy is the appropriate therapy. Gallbladder CA in stages II and III should be treated with "extended" cholecystectomy – lymphadenectomy of the cystic duct, hilar lymph nodes, right celiac and posterior pancreatoduodenal. If the stump margin of the cystic duct is compromised by the tumor, resection of the common bile duct and reconstruction with Roux-en-Y is mandatory. The staging laparoscopy should be performed in patients with gallbladder CA, since in a high percentage (50-55%) of patients have liver or extrahepatic disease that is not detected by noninvasive staging modalities. In most cases, the gallbladder AC therapy is palliative, being closely related to the stage of disease survival [2].

The direct invasion sites of squamous carcinoma are: liver, duodenum, transverse colon, pancreas and bile duct. Distant metastases are rare in this hystological type [8].

Even though gallbladder cancer is considered a very aggressive disease with a poor prognosis, recently several reports have suggested that a wide surgical resection improves the survival of patients [3].

Postoperative mortality depends on several factors including a worse prognosis when there are: bleeding, infection, bile fistulas and as cites [3].

Reasons

Because it is a rare theme, papers like this are indispensable for scientific, academic and the professional community by dealing with a uncommon theme with unique features, providing the basis for training since a percentage of bladder neoplasms are only diagnosed in cholecystectomy with a hypothesis preview of cholecystitis/cholelithiasis and being the rare histological type in our country.

Objective

With this case report, we aim to enrich the scarce existing scientific evidence on this rare entity and contribute to student learning and continued health professionals regarding the evolution and behavior by a patient who will present this histological type of gallbladder cancer.

Methods

As methodology, we reviewed the literature on the subject in the BIREME databases, we filtered the data to full texts, the descriptors gallbladder cancer, gallbladder adenocarcinoma, squamous cell carcinoma, later to complement our research we focused our search to the filter case report, and in the subject field; cancer of the gallbladder, where some relevant files when they were not found complete in the databases for free, researched the same title and authors in academic google, succeeding to find the article in PDF in some cases, where we could get them for free.

Case Description

MJ, 71, female, was referred to the clinic with a diagnosis of acute cholecystitis, of pain in her right hypochondrium for more than two weeks and had at hand a complete abdominal ultrasonography showing cholelithiasis with wall thickening suggestive of malignancy. Physical examination showed pain in the right upper quadrant, positive Murphy's sign, but without diffuse peritonitis.

She was recommended for urgent hospitalization, and a GGT was performed (alkaline phosphatase: 134 IU/l, gamma-glutamyl transferase: 286 U/l, direct bilirubin: 0.30 mg/dl, indirect bilirubin: 0.40 mg/dl, total bilirubin: 0.70 mg/dl), hepatic function (total protein was 6.2 g/dl, albumin 3.1 g/dl, globulin 3.1 g/dl, partial thromboplastin time: 36.2 sec, prothrombin time 13.7 seconds), CBC (hB: 12.5 g/dl, ht: 39.2%, MCV: 96.1 u^3, HCM: 30.6 pg, platelets: 300,000/mm^3, leukocytes: 15,700/mm^3, neutrophils: 75.1%, Rods 1.0% , targeted 2.0%, eosinophils 2.1%, lymphocytes 14.9%, monocytes: 7.9%) renal function (creatinine 1.0mg/dl, urea 21 mg/dl) and ionogram (sodium: 139mEq/L, 4,2mEq/L) potassium tumor marker (CA 19.9: 8.6U/ml and CEA: 16 ng/ml) as well as a computed tomography of the upper abdomen and evaluation by an infectologist and a cardiologist.

Following the suggestions of the cardiologist and the infectologist, she chose to await the clearing of the infection and schedule elective open cholecystectomy with intraoperative freezing.

In the intraoperative, the gallbladder was completely covered with omentum, blocked by transverse colon and duodenum. Having cleared the adhesions, a cholecystectomy and segmentectomy of the anterior portion of segments IV and V was performed after confirmation of pathological malignancy for the liver resection.

The patient remained in the intensive care unit during the first postoperative day, and was sent to her room stable and uneventfully. She was discharged on the sixth day after surgery.

The surgical resection specimen was sent to pathology and immunohistochemistry (Figures 1-4), with the conclusion ulcerated moderately differentiated squamous cell carcinoma.

Objective

With this case report, we aim to enrich the scarce existing scientific

evidence on this rare entity and contribute to student learning and continued health professionals regarding the evolution and behavior by a patient who will present this histological type of gallbladder cancer.

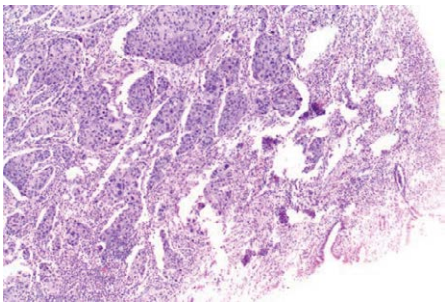

Figure 1: HE.

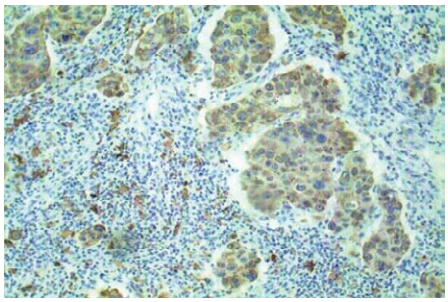

Figure 2: Cytokeratin 5/6.

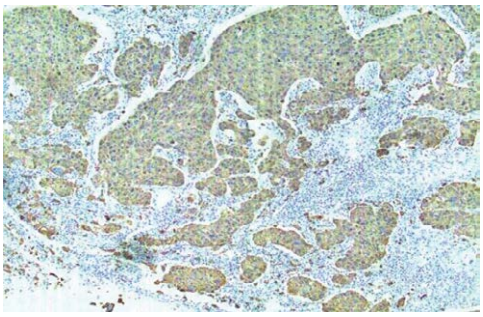

Figure 3: Cytokeratin CK7.

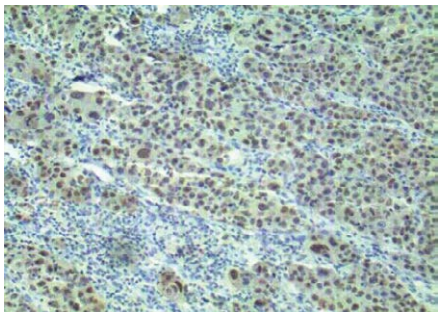

Figure 4: P63 Protein.

Methods

As methodology, we reviewed the literature on the subject in the BIREME databases, we filtered the data to full texts, the descriptors gallbladder cancer, gallbladder adenocarcinoma, squamous cell carcinoma, later to complement our research we focused our search to the filter case report, and in the subject field; cancer of the gallbladder, where some relevant files when they were not found complete in the databases for free, researched the same title and authors in academic google, succeeding to find the article in PDF in some cases, where we could get them for free.

Discussion

The most common histological type of gallbladder AC is well described in the medical literature - adenocarcinoma. However, squamous carcinomas are rare and thus litererature was scarce and sometimes diversive.

As mentioned in the introduction and observed in the clinical account, biliary neoplasia does not differ in any way from clinical cholecystitis. An often diagnosed by chance during cholecystectomony. But Saito reports that the clinical behavior of this type of cancer is different, because of rapid growth leading to a palpable mass in most cases [8].

Because the patient had only complained of abdominal pain, with no significant nausea, vomiting and weight loss, the picture was suggestive of cholecystitis. After investigation, gallbladder cancer was suspected. According to Mingoli, these types of tumors are usually diagnosed in advanced stages, mainly due to having little clinical importance and being silent in initial stages [9].

In the study by Kalayarasan, the age squamous cell carcinoma reaches is between the ages of 32 to 86 years. Tumor markers, as described in the introduction, do not have high serum levels. Abdominal pain is the most common complaint among patients, liver segments most affected by the disease - IV and V, 85.7% of patients with squamous cell carcinoma had extrahepatic disease at diagnosis and they all had keratinization in histopathology. Comparing this study with our case, there are several points of agreement, noting the age of our patient - 71 years, normal tumor markers, abdominal pain being the main complaint, liver disease affecting segments IV and V, and the presence of keratinization in the histopathology.

As well, the study by Roa reports that gallbladder carcinoma is a disease of older women, and strongly associated with billiary calculations [10].

Waisberg [11] reports that the biological behavior of squamous cell cancer is characterized by rapid growth, early metastatic spread and features local and regional infiltration. The tumor grows laterally along the gallbladder fossa, forming large infiltrative mass which usually invade, besides the liver, other directly adjacent organs. This fact, visualized during the intraoperative act, where the gallbladder was covered with omentum, blocked the transverse colon and duodenum, in addition to liver involvement, after confirmation by freezing.

Although this study's patient presented increased GGT in her exams, pathology of the common bile duct was not observed. Since one of the common bile duct cyst complications, although rare, is squamous cell carcinoma of the gallbladder [12,13].

The curative resection may lead to improved survival and extended life expectancy in patients with squamous cell carcinoma in the

gallbladder. Radical resection is the mainstay of treatment for these patients with locally invasive carcinoma and offers the only chance of cure. The extent of tumor invasion at diagnosis is the most important parameter in determining survival [14].

Conclusion

The reported case and cited publications lead to the conclusion that being a rare histological type, and consequently without extensive literature, a lot of data such as real prognosis or the survival time are underestimated and difficult to find a significant factor.

Limitations of this study are the small number of patients with squamous cell carcinoma of the gallbladder and the retrospective nature of the studies.

References

1. Yamaguchi K, Chijiiwa K, Ichimiya H, Sada M, Kawakami K, et al. (1996) Gallbladder carcinoma in the era of laparoscopic cholecystectomy. Arch Surg 131: 981-984.
2. Townsend CM, Beauchamp D, Evers M, Mattox K (2010) Sabiston: tratado de cirurgia. (18 edn.) Rio de Janeiro, Elsevier.
3. Kalayarasan R, Javed A, Sakhuja P, Agarwal AK (2013) Squamous variant of gallbladder cancer: is it different from adenocarcinoma?. Am J Surg 206: 380-385.
4. Chan KM, Yu MC, Lee WC, Jan YY, Chen MF (2007) Adenosquamous/squamous cell carcinoma of the gallbladder. J Surg Oncol 95:129-134.
5. Santos C, Mello E (2008) Manual de cirurgia oncológica. (2nd edn.) São Paulo: Tecmedd.
6. Fujii H, Aotake T, Horiuchi T, Chiba Y, Imamura Y, et al. (2013) Small cell carcinoma of the gallbladder: a case report and review of 53 cases in the literature. Hepatogastroenterology 48: 1588-1593.
7. Matsuo S, Shinozaki T, Yamaguchi S, Matsuzaki S, Takami Y, et al. (2000) Small-cell carcinoma of the gallbladder: report of a case. Surg Today 30: 89-93.
8. Saito A, Noguchi Y, Doi C, Mukai K, Fukuzawa K, et al. (1999) A case of primary adenosquamous/squamous cell carcinoma of gallbladder directly invaded duodenum. Hepatogastroenterology. 46: 204-207.
9. Mingoli A, Brachini G, Petroni R, Antoniozzi A, Cavaliere F, et al. (2005) Squamous and adenosquamous cell carcinomas of the gallbladder. J Exp Clin Cancer Res 24: 143-150.
10. Roa JC, Tapia O, Cakir A, Basturk O, Dursun N, et al. (2011) Squamous cell and adenosquamous carcinomas of the gallbladder: clinicopathological analysis of 34 cases identified in 606 carcinomas. Mod Pathol 24: 69-78.
11. Waisberg J, Bromberg SH, Franco MIH, Yamagushi N, Santos PA et al. (2001) Squamous cell carcinoma of the gallbladder. Sao Paulo Med J 119: 43.
12. Jordan PH, Goss JA, Rosenberg WR, Woods KL (2004) Some considerations for management of choledochal cysts. Am J Surg 187: 790-795.
13. Fujita T, Fukuda K, Ohmura Y, Nishi H, Mano M, et al. (2005) Long-term survival of a patient with advanced adenosquamous carcinoma of the gallbladder after radical resection. J Hepatobiliary Pancreat Surg 12: 147-150.
14. Oohashi Y, Shirai Y, Wakai T, Nagakura S, Watanabe H, et al. (2002) Adenosquamous carcinoma of the gallbladder warrants resection only if curative resection is feasible. Cancer 94: 3000-3005.