

Clear Cell Adenocarcinoma of the Colon in the Setting of Attenuated Familial Polyposis: A Rare Variant of Primary Colonic Adenocarcinoma

Nozha Mhamdi^{1,2}, Ahlem Bdioui^{1,2}, Nihed Abdessayed^{1,2*}, Sarra Mestiri¹, Marwa Guerfela^{1,2} and Moncef Mokni^{1,2}

¹Department of Pathology, Farhat Hached Hospital, Sousse, Tunisia

²Research Lab: Transfer in Technology in Anatomic Pathology, Tunisia

³Department of Surgery, Farhat Hached Hospital, Sousse, Tunisia

*Corresponding author: Nihed Abdessayed, Department of Pathology, Farhat Hached Hospital, Sousse, Street Farhat Hached, 4000 Sousse, Tunisia, Tel: +21652688551; E-mail: nihedabdessayed@gmail.com

Rec date: Feb 22, 2017; Acc date: Mar 29, 2017; Pub date: Mar 31, 2017

Copyright: © 2017 Mhamdi N, et al. This is an open-access article distributed under the terms of the creative commons attribution license, which permits unrestricted use, distribution, and reproduction in any medium, provided the original author and source are credited.

Abstract

Clear cell adenocarcinoma of the colon has been described rarely in the literature. It affects more commonly elderly men and usually appears in the left side of the colon. A 52-year-old male with a past medical history of attenuated FAP, who was diagnosed during a routine colonoscopy with bifocal tumor associated to 2 polyps of the transverse colon. Physical exam was normal. Laboratory data was unremarkable. A total colectomy with ileo-rectal anastomosis was performed. Gross examination of surgical specimen revealed 3 tumors and 6 pediculated polyps. Histopathology analysis of both coecal tumors conclude to an intestinal type adenocarcinoma.

However, for the third one located in the left colon was histologically different displaying clear cell features. The later showed at immunohistochemistry study a positive staining for CK20, CDX2, while it was negative for CK 7 and CD 10. These results confirmed the clear cell variant of the adenocarcinoma. Clear cell adenocarcinomas usually arises from kidneys and Müllerian organs. Colorectal occurrence is rare especially in the setting of attenuated adenomatous polyposis. More research and information about this malignancy is needed, especially in regard to prognosis and in order to provide the best treatment option.

Keywords: Clear cell; Adenocarcinoma; Colorectal; Attenuated familial polyposis

Introduction

Primary Clear cell adenocarcinoma (CCA) of the colon is a very rare variant of colonic adenocarcinoma [1]. Since first described by Hellstrom and Fisher in 1964, less than 20 cases have been described in the English literature [2,3]. We report a unique case of clear cells adenocarcinoma complicating attenuated familial adenomatous polyposis (FAP). To our knowledge no similar case has been published in Tunisian data.

Case Report

A 52-year-old man with a past medical a history of FAP, was operated in 2009 for a partial bowel obstruction. Per operative management revealed a tumor of the sigmoid colon. Final pathologic examination retained the diagnosis of a moderately differentiated adenocarcinoma of intestinal type, in addition to around twenty low grade adenomatous polyps mainly located in the sigmoid. The tumor was staged p T3 N1b M0. Although informed by the risk of degeneration in adenomatous polyps and carcinoma recurrence, patient refused a total colo-proctectomy. He had had a sigmoidectomy followed by 6 cures of Fol-fox with good evolution.

Seven years later, during follow-up, a systematic colonoscopy revealed a bifocal tumor associated to 2 polyps of the transverse colon. Abdominal CT showed a coecal nodule and circumferential thickening of the left colon wall. The patient had a total colectomy with ileo-rectal

anastomosis. The surgery and postoperative course were uneventful. Macroscopic examination revealed 3 tumors of which 2 were located in coecum, hemi-circumferential, measuring between 2.7 and 5 cm in greatest diameter. One of these tumors infiltrated the ileum. A third tumor was noted 18 cm far from rectal surgical limit (Figure 1). It was hemi-circumferential with glossy appearance, measuring 4 cm in greatest diameter. Moreover, we found 6 pediculated polyps, the largest one measures 1.5 cm. Microscopic examination of both coecal tumors revealed same histologic features. They correspond to a well differentiated intestinal type adenocarcinoma invading all colonic wall. The third tumor exhibits different histologic features. It was made entirely by invasive glandular structures lined by several layers of columnar cells.

Tumor cells had an abundant clear cytoplasm, well-defined borders giving a vegetal-like appearance. The nuclei were round, showing mild to marked atypia. Numerous mitotic figures were noted. Those glands were separated by a thin fibrous stroma containing chronic inflammatory cells (Figure 2). At Immunohistochemical study, cells stained positive for CK20, CDX2 and were negative for CK7 and CD10 (Figure 3). This clear cell adenocarcinoma invades all parietal tunics to the sub-serosa. For all examined tumors, there were no image of perineural and vascular invasion. The 12 lymph nodes had normal architecture with metastatic features. Surgical margins were tumor free. Accessory, the six polyps identified were low grade tubular adenomas without clarified features. The diagnosis was clear cell adenocarcinoma associated with bifocal synchronous colorectal intestinal type adenocarcinoma staged p T3^{multi} N0.

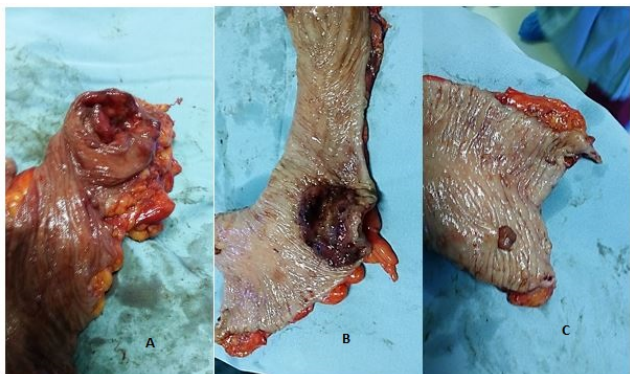


Figure 1: Macroscopic examination: (A) ulcerating polypoid coecal tumor, (B) hemi-circumferential tumor of the left colon showing a glossy appearance and (C) Gross features of the largest pediculated polyp.

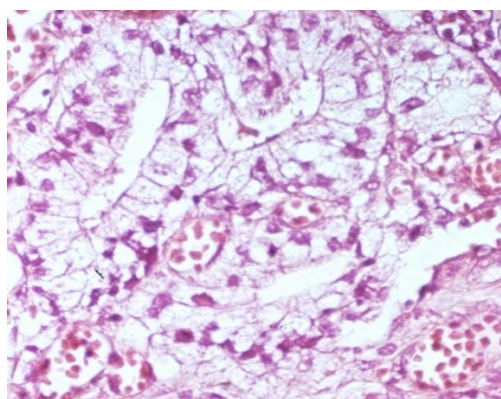


Figure 2: Cytoplasmic clarification of tumor cells in clear cell adenocarcinoma (HEX200).

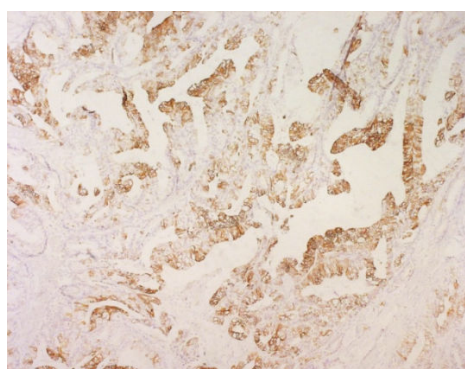


Figure 3: Immunohistochemistry showing positive staining for CK20(IHCx100).

Discussion

Primary CCA of the colon is an exceedingly rare malignant tumor. Thus far, only 15 such cases have been reported in the English literature [2]. According to published reports, male patients are more affected and tumor tends to be located on the left colon [1] which is consistent with the present case. CCA generally occurs in elderly males with an average age of 62 years [1,4,5]. Its pathogenesis still uncertain. Several studies have suggested a Müllerian origin that can be explained by colonic endometriosis. However, its occurrence in male patients declines this hypothesis. Other authors are proponents of a classic carcinogenesis pathway according to the linear sequence "adenoma-adenocarcinoma", and suggest that tumor-cells cytoplasmic clarification is due to glycogen accumulation [6,7]. In our observation, association of clear cell adenocarcinoma with attenuated AFP supports strongly this hypothesis, however clarified cytoplasmic features weren't observed in concomitant six adenomas. According to published cases there were nor predisposing factor neither association with AFP (even attenuated forms) reported. The lack of data and the absence reports about this association emphasizes the rarity of the tumor and its unclear pathogenesis.

The CCA affects mainly kidney and Mullerian organs [8], therefore it is necessary to distinguish primary CCA of the colon from colonic metastasis of CCA deriving from the ovary, kidney, and other organs. Clinical and histologic features are insufficient to make distinction between primary or secondary colorectal CCA and immunohistochemical study is essential. In fact, positive staining with CK20, CDX2 in contrast to negative staining with Vimentin, CK 7, RCC, CD31 and CD10 help to rule out secondary tumors and confirm its colonic nature [2,9].

Regarding prognosis, there is no study that evaluates the invasive characteristics or tendencies of this type of tumor. Previous studies have indicated that the behavior of this tumor is not different from that of conventional intestinal carcinomas; However, only a single case reported in the literature indicated the presence of vascular and perineural invasion [9]. Surgery has been the main treatment in all reported cases. There are some cases in which adjuvant chemotherapy has been used, but there are no reports or studies addressing the usefulness, superiority, or inferiority of chemo- or radiotherapy [10,11]. For CCA developed within attenuated AFP, with synchronous conventional intestinal type adenocarcinomas, prognosis corresponds to that of the conventional adenocarcinoma in the setting of attenuated AFP. Our patient had an excellent post-operative recovery and still have follow ups with an oncologist. Data about survival rate are insufficient explained by the scarcity of this variant of colorectal adenocarcinomas.

Conclusion

To conclude, in this report we present a rare case of CCA of the colon complicating a AFP and with bifocal synchronous intestinal type adenocarcinomas. This unique case of AFP and CCA association may be a key for further researches to investigate carcinogenesis pathway and clear cell origin.

References

1. Wang W, Li X, Qu G, Leng T, Geng J (2014) Primary clear cell adenocarcinoma of the colon presenting as a huge extracolonic mass: A case report. *Oncol Lett* 8: 1873-1875.

2. Barrera-Maldonado CD, Wiener I, Sim S (2014) Clear cell adenocarcinoma of the colon: A case report and review of the literature. *Case Rep Oncol Med* 905478.
3. Hellstrom HR, Fisher ER (1964) Physaliferous variant of carcinoma of colon. *Cancer* 17: 259-263.
4. Furuya Y, Wakahara T, Akimoto H, Kishimoto T, Hiroshima K, et al. (2011) Clear cell adenocarcinoma with enteroblastic differentiation of the ascending colon. *J Clin Oncol* 29: e647-649.
5. Ko YT, Baik SH, Kim SH, Min BS, Kim NK, et al. (2007) Clear cell adenocarcinoma of the sigmoid colon. *Int J Colorectal Dis* 22: 1543-1544.
6. Barisella M, Lampis A, Perrone F, Carbone A (2008) Clear cell adenocarcinoma of the colon is a unique morphological variant of intestinal carcinoma: Case report with molecular analysis. *World J Gastroenterol* 14: 6575-6577.
7. Suzuki H, Ohta S, Tokuchi S, Moriya J, Fujioka Y, et al. (1998) Adenoma with clear cell change of the large intestine. *J Surg Oncol* 67: 182-185.
8. Soga K, Konishi H, Tatsumi N, Konishi C, Nakano K, et al. (2008) Clear cell adenocarcinoma of the colon: A case report and review of literature. *World J Gastroenterol* 14: 1137-1140.
9. Sassi SH, Hamdane MM, Driss M, Mrad K, Abbas I, et al. (2011) Primary clear cell adenocarcinoma of the colon. *Tunis Med* 89: 803-804.
10. Braumann C, Schwabe M, Ordemann J, Jacobi CA (2004) The clear cell adenocarcinoma of the colon: Case report and review of the literature. *Int J Colorectal Dis* 19: 264-267.
11. Finkelstein A, Levy GH, Hui P (2010) Clear cell adenocarcinoma of the colon arising in the background of endometriosis: A case report and diagnostic approach. *Lab Med* 41: 111-114.