

Coexistence of Pemphigus Vulgaris and Pemphigus Foliaceus in the Same Patient at the Same Time

Koray Durmaz^{1*}, Recep Dursun¹, Arzu Ataseven¹, İlkey Özer¹, and Siddika Findik²

¹Department of Dermatology, Necmettin Erbakan University, Konya, Turkey

²Department of Pathology, Necmettin Erbakan University, Konya, Turkey

Abstract

Pemphigus is an autoimmune blistering disease and includes two classical forms. These forms are Pemphigus vulgaris (PV) and Pemphigus foliaceus (PF). These two subtypes of the disease are related with different auto-antibodies and show different clinical features. Rare cases of simultaneous presence of PV and PF have been presented in the literature. Here, we report the case of a 62-year-old woman who developed PV and PF lesions at the same time.

Keywords: Pemphigus disease; Simultaneous presence; Two subtypes

Introduction

Pemphigus is an autoimmune blistering skin disease resulting from a loss of keratinocyte cell adhesion mediated by autoantibodies against desmoglein 1 (Dsg1) and/or desmoglein 3 (Dsg3). Pemphigus disease that can be divided into two major subtypes by the result of these autoantibodies reactivity: Pemphigus vulgaris (PV) (target antigen is Dsg3) and pemphigus foliaceus (PF) (target antigen is Dsg1). The PV antigen, which is defined by autoantibodies from PV patients, has been characterized as a 130 kDa glycoprotein (desmoglein 3), whereas the PF antigen is a 160 kDa or 150 kDa desmosomal glycoprotein (desmoglein 1) [1-12]. These two types of the disease present some different clinical features. For instance, PV is characterized with oral and cutaneous erosions but oral mucosal lesions are only rarely seen in PF. We present a patient who has these two subtypes of the disease at the same time.

Case Report

A 62-year old woman who lives in Konya from Turkey was admitted to our dermatology clinic with 1-month history of oral mucosal erosions 4 years ago. Skin examination revealed multiple blisters on the bilateral buccal mucosae and the soft palate. A punch biopsy specimen from the oral mucosa revealed suprabasilar acantholysis in the epidermis. Direct immunofluorescence showed intercellular deposits of IgG in the lower epidermis confirming the clinical diagnosis of PV. Past medical history of the patient revealed that she was affected by hypertension, diabetes mellitus type-2, hyperlipidaemia and ischemic stroke. Methylprednisolone I.V. at the initial dose (80 mg per day) and Azathioprine P.O. (150 mg per day) was given to the patient. Cause of development steroid-induced myopathy and confusion, confabulation, amnesia like neurological symptoms (she has complained weakness mainly to the proximal muscles of the upper and lower limbs) then methylprednisolone dose was gradually reduced to 16 mg per day in 3 months. In a few months, patient's lesions were spread into the scalp and her chest. She was suffering from pruritus and crusts on healing lesions. Azathioprine was stopped and Cyclosporine P.O. 200 mg per day was given for the adjuvant therapy. Topical corticosteroids and emollients were also added. She was seemed in the visits periodically. Her BUN and creatinine levels were increased and blood pressure values were uncontrollable after cyclosporine therapy and unfortunately, the patient's dermatological symptoms did not respond to the therapy. Therefore, we decided to give IVIG therapy to the patient while she was taking oral methylprednisolone P.O. 4 mg per day. She received an intravenous drip infusion of human IgG at 400 mg/kg/day for 5 consecutive days in one month. This therapy was given to her five times. The lesions began to heal and no new lesions had appeared at that period. But she couldn't come to

control visits after 5 IVIG infusions because of some personal reasons. 8 months later, she came with activation of the disease. There were scattered erosions around submammary region and crusted scaly erythematous plaques with a few erosions on the scalp (Figure 1). In addition, she had erosions on the soft palate. She has been taking methylprednisolone P.O. 4 mg per day and applying topical corticosteroids on the scalp and submammary region two times a day. Pathohistological findings at the scalp lesion revealed suprabasilar acantholysis but there was subcorneal acantholysis at the submammary lesion specimen (Figure 2). Direct immunofluorescent technique demonstrated IgG in the epidermal layers. To characterize the autoantibodies in this case, we performed ELISA test for the detection of autoantibodies against Dsg3 and Dsg1. The values of both autoantibodies were positive. On the basis of these findings, PV and PF were diagnosed. So, we decided to increase methylprednisolone dose to 16 mg P.O. per day and give IVIG therapy to her again.

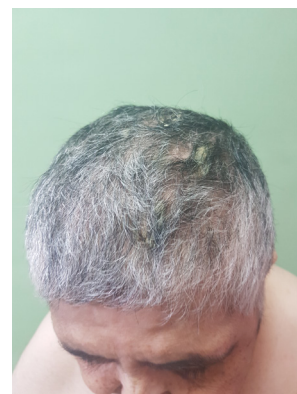

Figure 1A

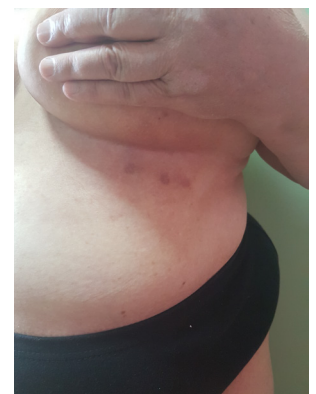

Figure 1B

Figure 1: (A) Crusted lesions on the scalp (B) Scattered erosions at the submammary area.

***Corresponding author:** Koray Durmaz, Department of Dermatology, Necmettin Erbakan University, Konya, Turkey; Tel: +90-332-223-6204, E-mail: koraydurmaz06@gmail.com

Received: June 14, 2017; **Accepted:** July 06, 2017; **Published:** July 17, 2017

Citation: Durmaz K, Dursun R, Ataseven A, Özer I, Findik S (2017) Coexistence of Pemphigus Vulgaris and Pemphigus Foliaceus in the Same Patient at the Same Time. Dermatol Case Rep 2: 124.

Copyright: © 2017 Durmaz K, et al. This is an open-access article distributed under the terms of the Creative Commons Attribution License, which permits unrestricted use, distribution, and reproduction in any medium, provided the original author and source are credited.

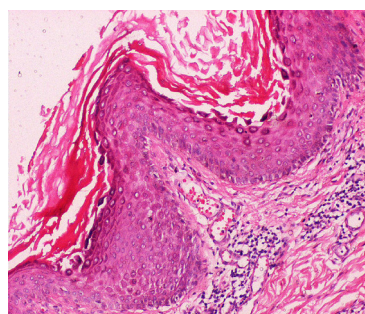


Figure 2A

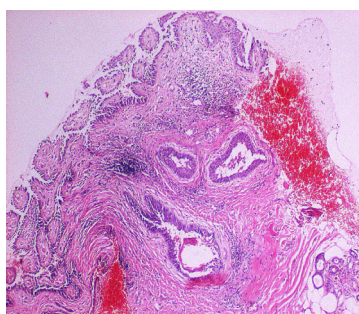


Figure 2B

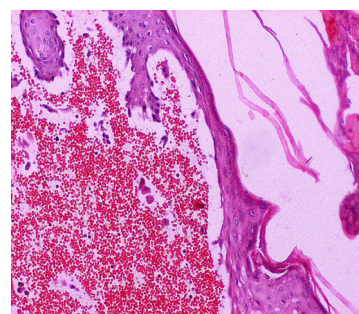


Figure 2C

Figure 2: (A): Subcornal blister with dyskeratotic acantholytic granular cells. Hematoxylin eosin (H&E) x100. (B): (x40) and (C): (x100) Intraepidermal acantholytic blister contains acantholytic cells. Dermal papillae lined by a single layer of basal keratinocytes. Hematoxylin eosin (H&E).

Discussion

The two types of pemphigus show some different features. PV is characterized by expanded cutaneous lesions with oral mucosal involvement. Blisters in PV are placed in the suprabasal layers of the epidermis. In PV, the target antigen is Dsg3 which located primarily on the oral mucosa and lower epidermis. In PF, the acantholysis exist within the upper layers of the epidermis, resulting in clinical crusts or superficial blisters without oral involvement, as the target antigen is Dsg1, which is located on the upper epidermis of the skin. Almost 60% of patients affected by PV also have circulating Dsg1 autoantibodies without any clinical symptoms of PF-like lesions [13]. The shifting between PV and PF is an uncommon situation [14]. Previous studies have suggested that qualitative changes in Dsg autoantibody profile might underlie this transition [15-17]. This transition is a reflection of qualitative and quantitative changes in the profile of developed autoantibodies against Dsg1 and Dsg3 antigens [18]. The pathogenic role of antidesmoglein in pemphigus is well known. Recent studies have demonstrated that the clinical phenotype of the disease is described by the antidesmoglein autoantibody profile and by the Dsg1 and Dsg3 tissue distribution [19].

Conclusion

In the reported cases of transformation between PV and PF, immunoblotting studies have suggested that the change in clinical features is related to a change in antibody profile [18]. Our patient displayed a mixed clinical and histopathological expression of features of both PV and PF related to co-expression of anti-Dsg3 and anti-Dsg1 antibodies. Rare cases of concurrent presence of PF and PV have been described in the literature [20,21]. So, our patient may have a rare case of pemphigus, diagnosed from clinical and histopathological findings, with detected two autoantibodies belong to PV and PF disease's pathogenesis.

References

- Harman KE, Gratian MJ, Shirlaw PJ, Bhogal BS, Challacombe SJ, et al. (2002) The transition of pemphigus vulgaris into pemphigus foliaceus: A reflection of changing desmoglein 1 and 3 autoantibody levels in pemphigus vulgaris. *Br J Dermatol* 146: 684-687.
- Stanley JR, Yaar M, Hawley-Nelson P, Katz SI (1982) Pemphigus antibodies identify a cell surface glycoprotein synthesized by human and mouse keratinocytes. *J Clin Invest* 70: 281-288.
- Stanley JR, Koulu L, Thivolet C (1984) Distinction between epidermal antigens binding pemphigus vulgaris and pemphigus foliaceus autoantibodies. *J Clin Invest* 74: 313-320.
- Buxton RS, Cowin P, Franke WW, Garrod DR, Green KJ, et al. (1993) Nomenclature of the desmosomal cadherines. *J Cell Biol* 121: 481-483.
- Kirtsching G, Wojnarowska F (1994) Autoimmune blistering disease: an up-date of diagnostic methods and investigations. *Clin Exp Dermatol* 19: 97-112.
- Eyre RW, Stanley JR (1988) Identification of pemphigus vulgaris antigen extracted from normal human epidermis and comparison with pemphigus foliaceus antigen. *J Clin Invest* 81: 807-812.
- Jones JCR, Yokoo KM, Goldman RD (1986) Further analysis of pemphigus autoantibodies and their use in studies on the heterogeneity, structure, and function of desmosomes. *J Cell Biol* 102: 1109-1117.
- Amagai M, Klaus-Kovtun V, Stanley JR (1991) Autoantibodies against a novel epithelial cadherin in pemphigus vulgaris, a disease of cell adhesion. *Cell* 67: 869-877.
- Loomis CA, Korega J, Manabe M, Sun TT (1992) Characterization of a keratinocyte specific extracellular epitope of desmoglein. Implications for desmoglein heterogeneity and function. *J Biol Chem* 267: 16676-16684.
- Rappersberger K, Roos N, Stanley JR (1992) Immunomorphologic and biochemical identification of the pemphigus foliaceus autoantigen within desmosomes. *J Invest Dermatol* 99: 323-330.
- Allen EM, Giudice GJ, Diaz LA (1993) Subclass reactivity of pemphigus foliaceus autoantibodies with recombinant human desmoglein. *J Invest Dermatol* 100: 685-691.
- Hashimoto T, Ogawa MM, Konohana A, Nishikawa T (1990) Detection of pemphigus vulgaris and pemphigus foliaceus antigens by immunoblot analysis using different antigen sources. *J Invest Dermatol* 94: 327-331.
- Feliciani C, Motta A, Castellana M, Federica M, De Benedetto A, et al. (2005) Coexisting pemphigus vulgaris and pemphigus foliaceus in the same patient. *Int J Dermatol* 44: 139-141.
- Ishii K, Amagai M, Ohata Y, Shimizu H, Hashimoto T, et al. (2000) Development of pemphigus vulgaris in a patient with pemphigus foliaceus: Antidesmoglein antibody profile shift confirmed by enzyme-linked immunosorbent assay. *J Am Acad Dermatol* 42: 859-861.
- Kawana S, Hashimoto T, Nishikawa T, Nishiyama S (1994) Changes in clinical features, histologic findings, and antigen profiles with development of pemphigus foliaceus from pemphigus vulgaris. *Arch Dermatol* 130: 1534-1538.
- Chorzelski TP, Hashimoto T, Jablonska S, Nishikawa T, Kozłowska A, et al. (1995) Pemphigus vulgaris transforming into pemphigus foliaceus and their coexistence. *Eur J Dermatol* 5: 386-390.
- Chang SN, Kim SC, Lee IJ, Hong CK, Park WH (1997) Transition from pemphigus vulgaris to pemphigus foliaceus. *Br J Dermatol* 137: 303-305.
- Komai A, Amagai M, Ishii K, Nishikawa T, Chorzelski T, et al. (2001) The clinical transition between pemphigus foliaceus and pemphigus vulgaris correlates well with the changes in autoantibody profile assessed by an enzyme-linked immunosorbent assay. *Br J Dermatol* 144: 1177-1182.
- Amagai M, Tsunoda K, Zillikens D, Nagai T, Nishikawa T (1999) The clinical phenotype of pemphigus is defined by the anti-desmoglein autoantibody profile. *J Am Acad Dermatol* 40: 167-170.
- Izumi T, Seishima M, Satoh S, Ito A, Kamiya H, et al. (1998) Pemphigus with features of both vulgaris and foliaceus variants, associated with antibodies to 160 and 130 kDa antigens. *Br J Dermatol* 139: 688-692.
- Martel P, Cordel Neg Courville P, Gilbert D, Musette P, et al. (2002) Pemphigus with clinical, histological and immunological features of both vulgaris and foliaceus subtypes. *Br J Dermatol* 147: 1263.