

Case Report

Open Access

Focal Nodular Hyperplasia: A Rare Indication of Resection

Mélanie Mansvelt, Baudouin Mansvelt* and Alexandra Dili

Department of Surgery, Hôpital de Jolimont, Rue Ferrer, Belgium

Abstract

Surgical indications of Focal Nodular Hyperplasia (FNH) remain exceptional except in cases of diagnostic uncertainty, symptomatic lesion or increase of tumour volume. We describe the case of FNH compressing the Inferior Vena Cava (IVC).

Case Report

A 33 years old female patient was admitted on an emergency basis for severe abdominal pain, spontaneously resolving within a few hours. The physical examination confirmed abdominal sensibility without signs of peritoneal irritation. The abdominal CT-scan showed ovarian varix and squeal of torsion of the right annex which was spontaneously reduced.

Few days later, clinical examination objectivated lower limbs oedema. Laboratory tests were normal but an abdominal ultrasound demonstrated a liver tumour of 90 mm located in the 5th segment. CT and MRI assessment (Figures 1 and 2) described a central scar into the mass as well as an inferior vena cava compression (Figures 3 and 4). The diagnosis of symptomatic focal nodular hyperplasia (FNH) was, then, established.

Because of the importance of inferior vena cava compression

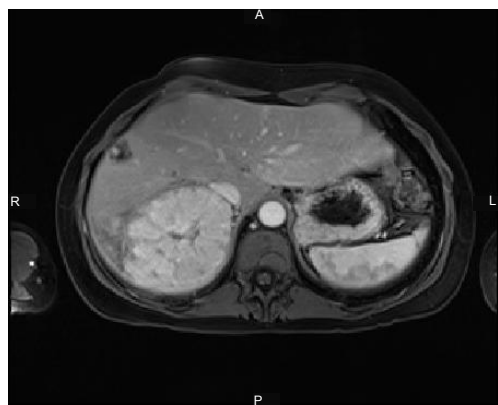


Figure 1: MRI. Injection of gadolinium, contrast uptake by the tumour.

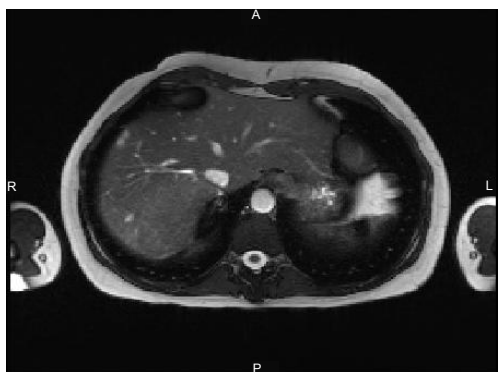

Figure 2: MRI T2, IVC of normal caliber above the level of the tumour.

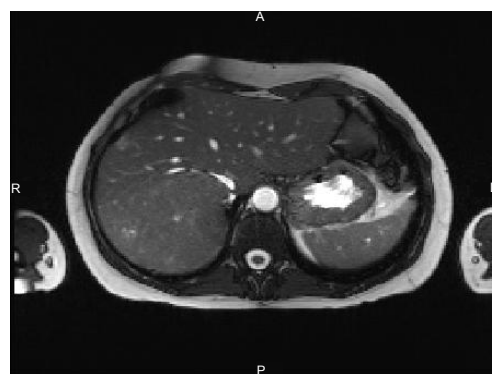

Figure 3: MRI T2, IVC compressive by the tumour.

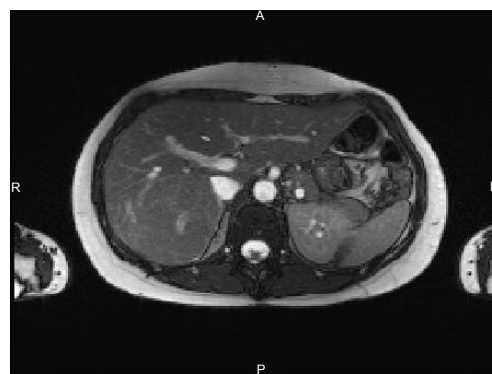

Figure 4: MRI T2, IVC below the level of the tumour.

causing lower limbs oedema and possibly explaining the ovarian varix, as well as real risk of IVC thrombosis, surgical resection was indicated. Intraoperative ultrasound evaluation confirmed a net compression of the IVC. Resection of segment V was performed. The histologic of the removed tumour is microscopic typical appearance of Focal Nodular

***Corresponding author:** Baudouin Mansvelt, Department of Surgery, Hôpital de Jolimont, Rue Ferrer, 159 7100 Haine Saint-Paul, Belgium, Tel: +3264225909 ; E-mail: baudouin.mansvelt@skynet.be

Received February 8, 2021; Accepted February 22, 2021; Published March 1, 2021.

Citation: Mansvelt M, Mansvelt B, Dili A (2014) Focal Nodular Hyperplasia: A Rare Indication of Resection. Gen Med (Los Angel) 9: 329. doi: 10.4172/2327-5146.1000329

Copyright: © 2021 Mansvelt M, et al. This is an open-access article distributed under the terms of the Creative Commons Attribution License, which permits unrestricted use, distribution, and reproduction in any medium, provided the original author and source are credited.

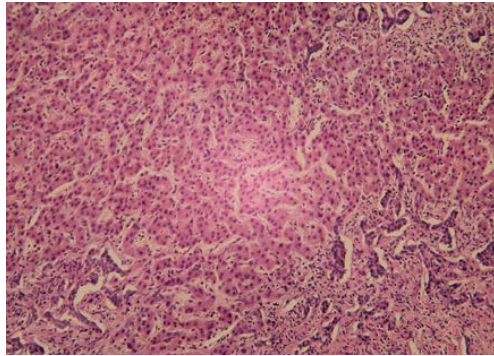


Figure 5: Histologic image of Microscopic FNH.

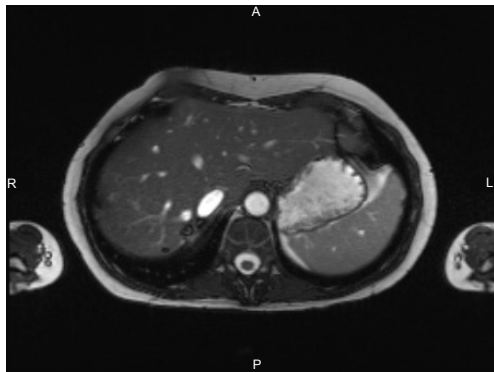


Figure 6: Postoperative MRI T2, IVC of normal caliber above the site of tumour resection.

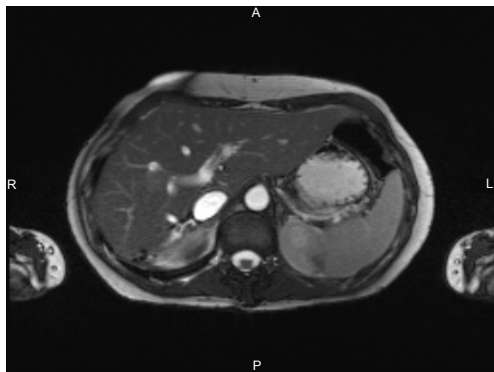


Figure 7: Postoperative MRI T2, IVC of normal caliber at the site of tumour resection.

Hyperplasia (Figure 5). The immediate postoperative course was uneventful. The MRI control (Figures 6 and 7) objectifies surgical site without anomaly and the diameter of the vena cava is back to normal. Clinically the lower limbs oedema disappeared.

Discussion

FNH is a benign idiopathic fleshy tumour of the liver, ten times more common than adenoma and is found at any age but mainly in adults. There is a female predominance (9:1). The lesion is usually single (80% of cases). Tumour is more or less rounded, lobulated and well demarcated but not encapsulated with a diameter ranging from one to

several centimetres. FNH is usually asymptomatic. When the tumour is large, it may be painful. Other symptoms described [1] are loss of appetite, nausea, vomiting and weight loss.

Some cases reported of FNH complications mention dilatation of intrahepatic bile duct [2], compression of portal vein [3], compression of stomach [4], compression of inferior vena cava [4], intra-tumour bleeding [5] and intra-peritoneal rupture [6].

Because of this benign evolution, therapeutic abstention is currently recommended if the diagnosis of FNH is established with certainty, including MRI assisted by echo-Doppler, and in the absence of symptoms. This attitude is justified by exceptional complications and no risk of cancer. The arguments for the intervention were significant compression of vena cava with dilatation of vena cava upstream, lower limbs oedema and the possibility that the ovarian varix are responsible for the torsion of the ovary. The risk of IVC thrombosis was the major argument for the surgical decision. In literature, some cases of FNH with vascular complications requiring surgical management are described. The first case [3] is a child of 7 months with a wide FNH invading all left hepatic lobe and compressing portal vein. Another case [4] reports compression of inferior vena cava. Tumour size is a decision factor for symptomatic patients [7].

It seems, for indications remain the exception, that surgical management of these lesions is justified and this attitude is reinforced by the low rate of morbidity and mortality of the surgical procedure [8,9].

References

1. Sörensen TI, Almersjö O (1976) Focal nodular hyperplasia of the liver. Five cases. *Scand J Gastroenterol* 11: 97-101.
2. Lapeyre M, Mathieu D, Tailboux L, Rahmouni A, Kobeiter H (2002) Dilatation of the intrahepatic bile ducts associated with benign liver lesions: an unusual finding. *Eur Radiol* 12: 71-73.
3. De Luca G, Zamparelli M, Fadda C, Martone A (2006) Focal nodular hyperplasia of the liver in infancy: a case report. *J Pediatr Surg* 41: 456-457.
4. Hung PL, Huang SC, Kuo HW, Shieh CS, Tiao MM (2001) Hepatic focal nodular hyperplasia in children: report of three cases. *Chang Gung Med J* 24: 657-662.
5. Akovbiantz A, Ackermann D, Bühler H, Schmid M (1980) [Management of liver cell adenoma and focal nodular hyperplasia]. *Helv Chir Acta* 47: 607-609.
6. Koch N, Gintzburger D, Seelentag W, Denys A, Gillet M, et al. (2006) [Rupture of hepatic focal nodular hyperplasia. About two cases]. *Ann Chir* 131: 279-282.
7. Charny CK, Jarnagin WR, Schwartz LH, Frommeyer HS, DeMatteo RP, et al. (2001) Management of 155 patients with benign liver tumours. *Br J Surg* 88: 808-813.
8. Mentha G, Rubbia-Brandt L, Howarth N, Majno P, Morel P, et al. (1999) Management of focal nodular hyperplasia and hepatocellular adenoma. *Swiss Surg* 5: 122-125.
9. Bonney GK, Gomez D, Al-Mukhtar A, Toogood GJ, Lodge JP, et al. (2007) Indication for treatment and long-term outcome of focal nodular hyperplasia. *HPB (Oxford)* 9: 368-372.