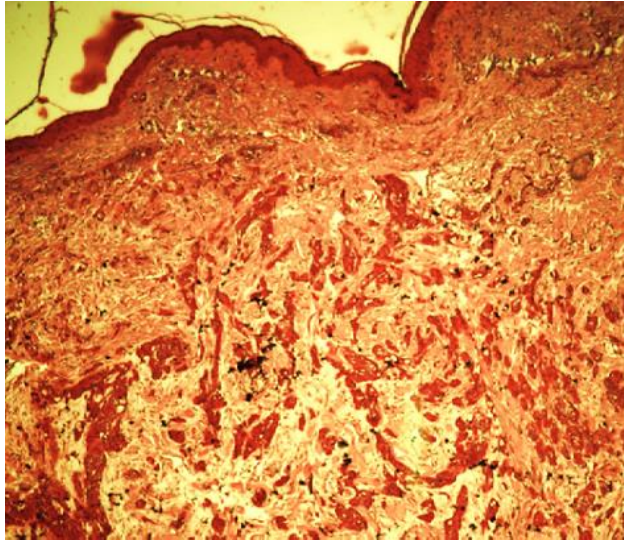


# Generalized Adenoid Cystic Carcinoma of the Skin

Christiana Williams\*

Longdom Publishing, Avenue Roger Vandendriessche, 18, 1150 Brussels, Belgium



**Figure 1:** Adenoid cystic carcinoma (ACC) is a comparatively rare type of cancer that most usually occurs in the salivary glands or other areas of the head and neck, characterized by a distinctive histological pattern of irregular 'nests' or cords of certain cells (epithelial cells) surrounding and/or infiltrating ducts or glandular structures inside the affected organ. These structures are usually packed with or contain irregular fibrous membranes with a mucous-like content. During microscopic examination of tumor cells from a biopsy sample, certain characteristics are evident.

**Correspondence to:** Christiana Williams, Longdom Publishing, Avenue Roger Vandendriessche, 18, 1150 Brussels, Belgium, E-mail: [info@longdom.com](mailto:info@longdom.com)

**Received:** February 23, 2021; **Accepted:** February 24, 2021; **Published:** February 26, 2021

**Citation:** Williams C (2021) Dermatomyositis: An Image Article. *Dermatol Case Rep* 6:176. doi: 10.35248/2684-124X.21.6.176

**Copyright:** © 2021 Williams C. This is an open-access article distributed under the terms of the Creative Commons Attribution License, which permits unrestricted use, distribution, and reproduction in any medium, provided the original author and source are credited.