

# Infection by *Hymenolepis diminuta* in Pediatric Patients from Gran Buenos Aires, Argentina

S. Ferioli\*, J. M. Perazzo, E. A. Correa Louzao, P. Paulin

Department of Parasitology and Gastroenterology Area, Prof Dr. J. P. Garrahan Hospital, Buenos Aires, Argentina

## ABSTRACT

*Hymenolepis diminuta* is a zoonotic cestode infrequently found in humans, with less than 1600 cases reported worldwide. Infection is acquired by accidental ingestion of arthropods containing the larval stage of the parasite in their body cavity. We present two clinical cases of pediatric patients attending the “Prof. Dr. Juan P. Garrahan” Pediatric Hospital, in whose coproparasitological examinations were found *Hymenolepis diminuta* eggs. Due to the rare finding and little knowledge of its epidemiology, the report of this infection becomes of great interest.

**Keywords:** Enteroparasite; *Hymenolepis diminuta*; Pediatric patients

## INTRODUCTION

*Hymenolepis diminuta* is an unusual enteroparasite, with less than 1600 cases reported worldwide [1]. The infection is diagnosed more frequently in the pediatric population [2]. Rodents are the main definitive hosts and natural reservoir for the parasite and in rare instances it can infect humans by accidental ingestion of infected insects. Coprophilic arthropods act as intermediate hosts, acquiring the infection by ingesting infective eggs. The larval stage of the parasite (cysticercoid) develops inside the body cavity of the intermediate host within 15 to 20 days. The cycle fulfills when the definitive host eats infected arthropods. Cysticercoids are released in the small intestine, where they attach into the intestinal mucosa and mature into the adult worm. Finally, embrionated eggs are eliminated in feces. Grains and cereals contaminated with infected insects represent the main source of infection for humans. The worm burden is generally low, and the infection is often asymptomatic or oligosymptomatic, with non-specific abdominal symptoms. Eosinophilia and anemia have also been registered. The diagnosis is based on the recovery and identification of the characteristic eggs in stool examination [3].

We report two cases of *Hymenolepis diminuta* infection in pediatric patients from Buenos Aires, Argentina, who attended to the Epidemiology and Infectology Service of the “Prof. Dr. Juan P. Garrahan” Pediatric Hospital.

## CASE PRESENTATION

**Patient 1.** An 8-year-girl, consulted for presenting abdominal pain that worsened after ingestion, weight loss and nausea during the last three months. The patient was always afebrile, with preserved catharsis and normal diuresis. An abdominal ultrasound was performed, which showed no abnormalities. The only finding within the routine analysis was in the stool samples from the parasitological examination that revealed few *H. diminuta* eggs. Monodose of praziquantel was prescribed. A second coproparasitologic examination carried out 20 days after, demonstrated the absence of parasitic structures. The patient reported improvement in symptoms, without vomiting, presenting occasional epigastric pain and weight gained.

**Patient 2.** A 2 year and 4 months old boy, came for follow-up due to low weight for over a year. He had a history of peripheral eosinophilia and infection with intestinal parasites (*Taenia* spp and *Enterobius vermicularis*) and *Toxocara* spp. Among the studies requested at this center, an abdominal ultrasound without abnormalities was reported; positive serological results for *Toxocara* sp. and peripheral eosinophilia were confirmed with an eosinophil count of  $6.09 \times 10^3/\text{mm}^3$ . In single and serial fecal samples, a regular amount of *Hymenolepis diminuta* eggs, *Giardia duodenalis* cysts, *Dientamoeba fragilis* trophozoites and *Blastocystis* spp were observed. Two cycles of mebendazol and one cycle of metronidazol were prescribed as antiparasitic treatment for the patient and his family. Patient follow-up was discontinued in this instance.

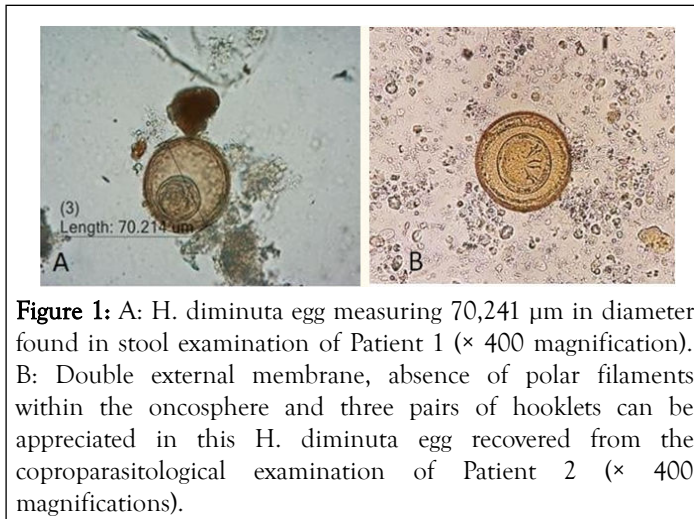
**Correspondence to:** S. Ferioli, Department of Parasitology and Gastroenterology Area, Prof Dr. J. P. Garrahan Hospital, Buenos Aires, Argentina, E-mail: silvanaferioli07@gmail.com

**Received:** July 07, 2021; **Accepted:** July 21, 2021; **Published:** July 29, 2021

**Citation:** Ferioli S, Perazzo JM, Louzao EAC, Paulin P (2021) Infection by *Hymenolepis diminuta* in Pediatric Patients from Gran Buenos Aires, Argentina. Gen Med (Los Angeles). 9:349.

**Copyright:** © 2021 Ferioli S, et al. This is an open-access article distributed under the terms of the Creative Commons Attribution License, which permits unrestricted use, distribution, and reproduction in any medium, provided the original author and source are credited.

The fecal samples for the parasitological examinations were collected in buffered formalin (SAF) and concentrated with the Ritchie method. The eggs of *H. diminuta* were brownish and spherical with an approximate measure of 70 µm in diameter. They presented a thick outer membrane, a thin inner membrane, and three pairs of hooklets but no polar filaments within the oncosphere (Figure 1). The described morphology allowed the identification of *H. diminuta* eggs and the parasitological diagnosis.



**Figure 1:** A: *H. diminuta* egg measuring 70,241 µm in diameter, found in stool examination of Patient 1 (× 400 magnification). B: Double external membrane, absence of polar filaments within the oncosphere and three pairs of hooklets can be appreciated in this *H. diminuta* egg recovered from the coproparasitological examination of Patient 2 (× 400 magnifications).

## DISCUSSION

We described two cases of *H. diminuta* parasitosis, a rare human infection. Prevalence in countries that reported human infection around the world varies from 0,002 to 8,222% [4-6]. In Latin America, epidemiological studies refer prevalence data ranging from 0.5% to 4% [7,8]. In the “Prof. Dr. Juan P. Garrahan” Pediatric Hospital we have reported the prevalence of intestinal parasites in fecal samples from patients attended during the year 2019, with a 0.05% result for *Hymenolepis diminuta* [9].

The intensity level of the infection is related to the number of adult worms in the intestines. In humans, the worm burden is frequently low, and the infection is usually asymptomatic, although it may present mild symptoms, such as the case of patient number 1. It may cause moderate peripheral eosinophilia in 6 to 20% of cases. A causal relationship between clinical aspects of patient number 2 and *Hymenolepis diminuta* infection cannot be established, due to coinfection with other parasites in this patient.

The diagnosis of *H. diminuta* infections in humans most often is performed by finding eggs in fecal samples, and rarely by the presence of the adult worm or its proglottids in fecal specimens, which require an experienced and trained observer to identify these parasite structures. The absence of polar filaments, the bigger size and the brownish color are specific features of *Hymenolepis diminuta* eggs that allow their recognition and differentiate them from *Hymenolepis nana* eggs that appear more frequently in parasitological examinations.

The drug of choice for the treatment of *Hymenolepis diminuta* infection is praziquantel in single dose. In patient number 1

clinical improvement was achieved with coproparasitological examination with no detected *H. diminuta* eggs after the completion of the treatment [10-12].

## CONCLUSION

*H. diminuta* infection has been related with basic services deficiencies and close contact with rodents. Individuals who are particularly vulnerable to this infection include children, rural areas inhabitants, and people living under overcrowding conditions and with poor sanitary facilities. It would be of great importance, in terms of prevention measures, to eradicate rodents and arthropods from housing and shops, where they can become in contact with food. There are over 20 species of insects susceptible to infection, such as rodent's fleas, moths, flour weevils, cockroaches and various beetles. The accidental ingestion of cereals or grains contaminated with infected insects is usually the source of human infection.

Due to the low worldwide incidence of *H. diminuta* infection, and the unawareness of its epidemiology, it has become of great interest to report this parasitosis.

## REFERENCES

1. Panti-May JA, Rodríguez-Vivas RI, García-Prieto L, Servián A, Costa F. Worldwide overview of human infections with *Hymenolepis diminuta*. Parasitol Res.2020;119(7).
2. Parija SC. Textbook of Medical parasitology, protozoology & Helminthology (2nd edn) New Delhi:All India Publishers & Distributors. 2010; pp:233.
3. Garcia LS. Diagnostic medical parasitology, intestinal cestodes. Washington DC (6th edn) Chapter 16. ASM Press. 2016; pp: 442.
4. Kalaivani R, Nandhini L, Seetha KS. *Hymenolepis diminuta* infection in a school-going child: A rare case report. Australas Med J. 2014;7:379-381.
5. Lo CT, Ayele Y, Birrie H. Helminth and snail survey in Harerge region of Ethiopia with special reference to Schistosomiasis. Ethiop Med J. 1989; 27(2):73-83.
6. MCMillan B, Kelly A, Walkar JC. Prevalence of *Hymenolepis diminuta* infection in man in the New Guinea highlands. Trop Geogr Med. 1971;23(4): 390-392.
7. Iannacone J, Benites M, Chirinos L. Prevalencia de infección por parasitos intestinales en escolares de primaria de Santiago de Surco, Lima, Perú. Parasitol Latinoam. 2006;61:54-62.
8. Rodriguez E, Costa-Cruz J. Strongyloidesstercoralis and other enteroparasites in children at Uberlandia city, state of Minas Gerais, Brazil. MemInst Oswaldo Cruz. 1998; 93(2):161-164.
9. Ferioli S, Perazzo JM, Paulin P. Prevalence of intestinal parasites in samples of patients attending the Hospital de Pediatría “Prof. Dr. Juan P. Garrahan”, Argentina, 2018-2019. Acta Bioquim Clin Latinoam. 2020; 54(4):455-460.
10. Tena D, Simón PM, Gimeno M, Pomata MTP, Illescas S, Amondarain I, et al. Human infection with *Hymenolepis diminuta*: Case report from Spain. J Clin Microbiol. 1998; 36(8):2375-2376.
11. Martínez-Barbabosa I, Gutiérrez-Cárdenas ME, Aguilar-Venegas JM, Shea M, Gutiérrez-Quiroz M, Ruiz-González LA. *Hymenolepis diminuta* infection in a college student. Rev Biomed. 2012;23(2): 61-64.
12. Kolodziej P, Rzymowska J, Stępien-Rukasz H, Lorencowicz R, Lucinska M, Dziobek M. Analysis of a child infected with *Hymenolepis diminuta* in Poland. Ann Agric Environ Med. 2014; 21(3):510-511.