

## Inguinoscrotal Bladder Hernia

Sebastian Barber-Millet MD\* and Manuel Vicente Planells

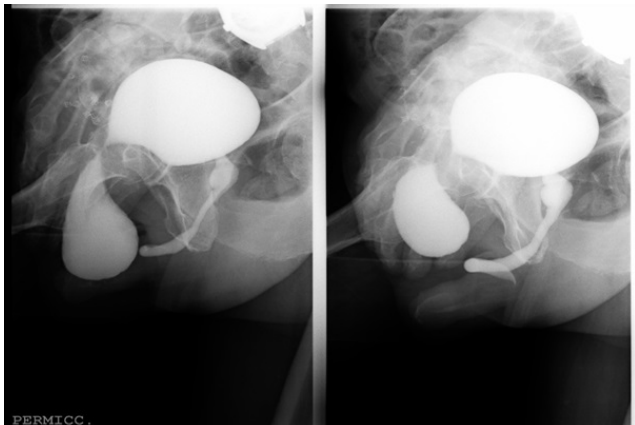
Department of Digestive Surgery, Hospital Francesc de Borja, Avenue Medical Gandia, Spain

\*Corresponding author: Sebastian Barber-Millet MD, Department of Digestive Surgery, Hospital Francesc de Borja, Avenue Medical Gandia, Spain, Tel: 962849690; E-mail: [sebarmi@hotmail.com](mailto:sebarmi@hotmail.com)

Rec date: April 25, 2016; Acc date: April 26, 2016; Pub date: April 28, 2016

Copyright: © 2016 Barber Millet S, et al. This is an open-access article distributed under the terms of the Creative Commons Attribution License, which permits unrestricted use, distribution, and reproduction in any medium, provided the original author and source are credited.

### Image Article



**Figure 1:** Diagnosis of right inguinoscrotal bladder hernia.

We present a 67-years-old male patient, operated 3 times of groin hernia. He consulted again due to inguinal mass, reducible with taxis maneuver and bulging with Valsalva, compatible with hernia recurrence.

He also mentioned mictional urgency during explorations and manipulations.

Abdominopelvic computed tomography showed inguinoscrotal bladder hernia, because of this finding, a mictional cystography was realized. The image showed the bladder full of contrast, with an hourglass disposition, where the caudal portion of the bladder occupied the inguinal channel (Figure 1).