

Research Article

Open Access

# Jarcho Levin Syndrome Associated With Aortic Coarctation

AEs Seddiki\*, A Babakhouya, S Messaoudi, M Rkain, R Amrani and N Benajiba

Department of Pediatrics, CHU Mohamed VI, Oujda School of Medicine and Pharmacy, Mohammed 1st University, Oujda, Morocco

## Abstract

Jarcho-Levin syndrome is a rare congenital disorder, characterized by a short trunk and vertebral and rib malformations. At birth, the diagnosis is suspected in a neck and a short trunk and thorax, a protruding abdomen, rib anomalies and vertebral defects as hemivertebrae, often associated with scoliosis. There are two different phenotypes: spondylocostal dysplasia and spondylothoracic dysplasia. Several defects are associated with bone malformations in this syndrome including neural tube defects (Spina Bifida found in 25% of patients), heart defects are rarely reported in the literature. We report a case of Jarcho-Levin syndrome in 40 days old infant associated with a heart disease.

**Keywords:** Short-trunk; Vertebral anomalies; Rib anomalies; Heart disease; Jarcho-Levin syndrome

## Introduction

Jarcho-Levin syndrome (JLS) is a rare congenital disorder characterized by the presence of vertebral and rib malformations at birth, first described in 1938 by Jarcho and Levin [1,2]. The majority of reported cases have originated in Puerto Rico, it seems that this syndrome is more common in patients with Spanish ancestors. Its frequency in Spain is 0.2 per 100000 newborns with a female predominance [3].

We report a case of Jarcho-Levin syndrome in infants forty days associated with heart disease (aortic coarctation).

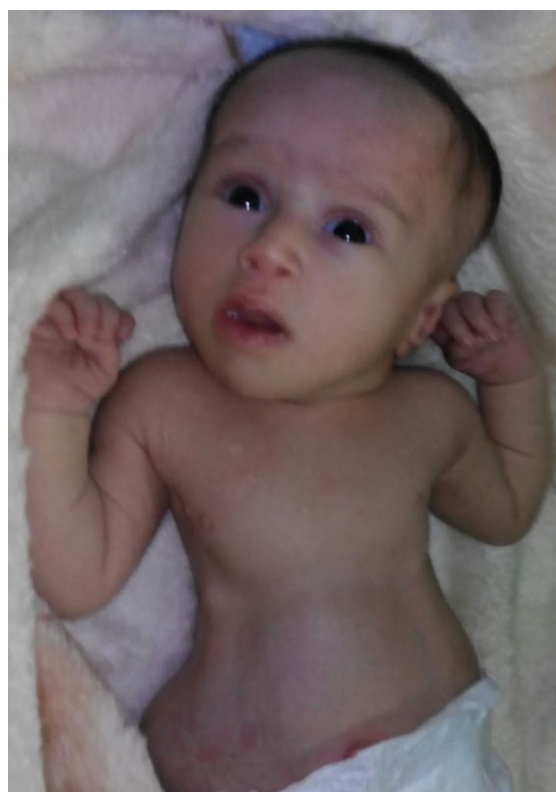
## Case Presentation

A forty days female infant, 3rd in a family of three, unrelated parents (the father's age was 50 years and that of the mother was 36 years). In the background we find an unfollowed and non full term pregnancy, the infectious anamnesis was negative with no medication or toxic intake during pregnancy and no similar cases in the family, a cesarean delivery (for face presentation) and stayed for 10 days in neonatal care unit for her respiratory distress which was associated to a 36 weeks prematurity. The infant was admitted for respiratory difficulties, with retraction signs and cyanosis. Somatic examination showed a weight of 3.5 kg, a size of 48 cm, head circumference was 38 cm, a heart rate of 124 beats / minute, respiratory rate 43 breaths / min and a pulsed oxygen saturation at 79 %. At the same time, we observe a malformation syndrome combining: a bulging forehead, a triangular face, large anterior fontanel, small ears, low-set and malformed short neck, short trunk, thoracolumbar scoliosis and a right parietal hernia (Spiegel hernia) (Figure 1).

The performed laboratory tests showed a correct blood count and electrolytes, a C-reactive protein at 28 mg/ml. The thoraco-abdominal radiography revealed nine straight ribs, a bifidity of the 8th right rib, an expansion of inter costal areas, thoracolumbar scoliosis right combined to hemivertebrae (Figure 2). The transfontanellar ultrasound was normal. The abdominal ultrasound showed a right Spiegel hernia without renal malformations and echocardiogram showed severe pulmonary Hypertension, aortic coarctation. The infant was put under oxygen therapy; a bi-antibiotic therapy and diuretic, the evolution was marked by death at J6 of hospitalization due to a severe respiratory distress.

## Discussion

Jarcho-Levin syndrome is a congenital disorder characterized by



**Figure 1:** Image showing our infant shortneck, low implanted ears and a narrow thorax.

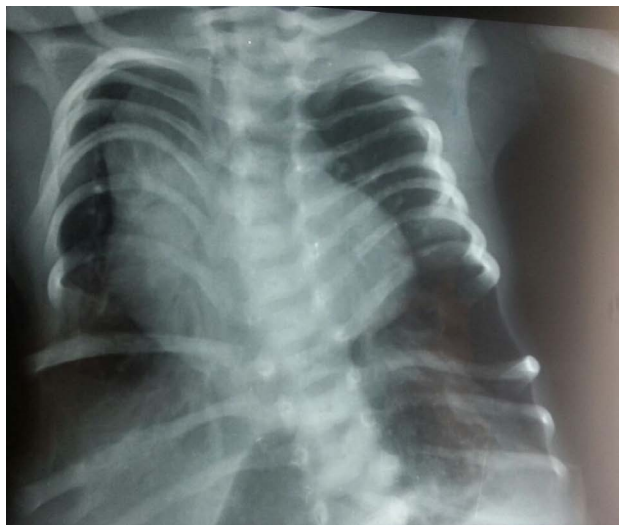a short trunk and vertebral and rib malformations [1,2]. At birth, the diagnosis is suspected in front of a neck and trunk shortness, low-set

**\*Corresponding author:** Anass Es seddiki, Department of Pediatrics, CHU Mohamed VI, Oujda School of Medicine and Pharmacy, Mohammed 1st University, Oujda, Morocco, Tel: 00212661411410; E-mail: [anass4444@gmail.com](mailto:anass4444@gmail.com)

**Received** February 15, 2016; **Accepted** March 28, 2016; **Published** March 30, 2016

**Citation:** Seddiki AEs, Babakhouya A, Messaoudi S, Rkain M, Amrani R, et al. (2016) Jarcho Levin Syndrome Associated With Aortic Coarctation. Gen Med (Los Angel) 4: 226. doi:10.4172/2327-5146.1000226

**Copyright:** © 2016 Seddiki AEs, et al. This is an open-access article distributed under the terms of the Creative Commons Attribution License, which permits unrestricted use, distribution, and reproduction in any medium, provided the original author and source are credited.



**Figure 2:** Chest radiograph showing only nine ribs, widening of inter costal spaces, vertebral malformations type of hemivertebrae floor of the dorsal scoliosis.

scalp, a protruding abdomen, rib anomalies (irregular size and shape) and vertebral malformations especially hemivertebrae, realizing a puzzle form sit above the thoracolumbar floor and often associated with scoliosis [1,4,5]. Other skeletal anomalies may be observed: winged scapula, malformation of the odontoid process, lack of atlas, irregular clavicle, hypoplasia of the humerus, extended iliac wings [2-5].

For our infant, the diagnosis of a JLS was laid since we observed a triangular face, wide anterior fontanel, small low-set and malformed ears, short neck and trunk, thoracolumbar scoliosis, the presence of a hernia (hernia spiegelien) and malformations detected in the chest radiography.

Several defects are associated with bone deformities in the JLS: Spina bifida (found in 25% of patients according to Chen CP) [6,7], the anal canal atresia, anal atresia, cryptorchidism, hernias a horseshoe kidney, renal agenesis, renal hypoplasia, bladder duplication, a single umbilical artery, Meckel's diverticulum and polydactyly [4,5]. In North Africa only two cases have been reported in the literature; Bouskraoui M et al., reported a case of a 6 months old male Moroccan infants in 1998 and Chabchoub I et al., reported a case in a newborn male Tunisian born in 2010 [8,9]. Heart defects are rarely described in the SJL; Pérez-Comas.A et al., reported a single case of heart disease (not detailed) associated with the SJL in a series of 6 patients in 1974 and Mortier GR et al., reported two cases in a series of 26 patients with this syndrome in 1996; transposition of the great arteries with hypoplastic left ventricle and situsinvertus [2,4]. The coarctation of the aorta in the JLS, as in our case, has not been described previously in world literature [2,4].

The JLS is divided into two different phenotypes: spondylocostal dysplasia (SCD), which is a congenital disorder with multiple vertebral and rib anomalies (numerical or structural) causing chest asymmetry, small size and short neck (as for our infant); and spondylothoracic dysplasia (STD), characterized by the presence of deformations of the rib cage crab-shaped rib without intrinsic abnormality [10].

Genetically, the SCD form is transmitted both as a severe recessive and dominant form of mutations in the delta-like 3 gene (DLL3) on the chromosome 19q13 with 17 described mutations affecting 1 in 40,000 newborns, while the STD form is transmitted in a recessive path and it

is due to a mutation of the gene on 15q26.1 MESP2 chromosome with an unknown impact [5,10].

## Analysis

Immunochemical studies have showed a significant reduction in Pax1 and Pax9 proteins expression rates in chondrocytes of the spine in this syndrome [5,10]. In our case the genetic study was not conducted due to lack of means.

Antenatal diagnosis is currently possible since the twelfth week of gestation through a standard (looking from hyper nuchal translucency) or three-dimensional ultrasound [11,12].

The majority of patients with this syndrome die early during the infancy period due to recurrent respiratory infections and respiratory failure secondary to thoracic small volume. Some cases described in the literature have survived beyond 12 months [5,10,12].

## Conclusion

Syndrome Jarcho-Levin is a rare malformation with a low incidence. It is important to detect pregnancy by ultrasound and any morphological anomaly in the delivery room to better organize the subsequent management. In the malformation disorder, we must search all associated anomalies especially cardiac ones.

## References

1. Jarcho S, Levin PM (1938) Hereditary malformation of the vertebral bodies, Bull Johns Hopkins Hosp 62: 216-226.
2. Pérez-Comas A, García-Castro JM (1974) Occipito-facial-cervico-thoracic-abdomino-digital dysplasia; Jarcho-Levin syndrome of vertebral anomalies: Report of six cases and review of the literature. J Pediatr 85: 388-391.
3. Martínez-Frías ML, Bermejo Sanchez E, Martínez Santana S, Nieto Conde C, Egues Jimeno J, et al. (1998) Syndromes Jarcho-Levin and Casamassima: differential diagnosis and often in Spain. An Esp Pediatr 48: 510-514.
4. Mortier GR, Lachman RS, Bocian M (1996) Multiple vertebral segmentation defects: analysis of 26 new patients and review of the literature. Am J Med Genet 61: 310-319.
5. Vázquez-López ME, López-Conde MI, Somoza-Rubio C (2007) Anomalies of vertebrae and ribs: Jarcho Levin syndrome- Description of a case and literature review. Joint Bone Spine 72: 275-277.
6. Chen CP (2008) Syndromes, Disorders and Maternal Risk Factors Associated with Neural Tube Defects (II). Taiwanese Journal of Obstetrics and Gynecology 47: 10-17.
7. Campbell RM (2009) Spine deformities in rare congenital syndromes: clinical issues. Spine 34: 1815-1827.
8. Bouskraoui M, Mouhaoui M, Ksyer M, Fehri M, Abid A (1998) Spondylocostal dysplasia or Jarcho -Levin syndrome. Pediatric Archives 5: 929-930.
9. Chabchoub I, Boukédi A, Turki H, Aloulou H, Kamoun T et al. (2010) Jarcho-Levin Syndrome: report of a case. Pediatric Archives 17: 426-428.
10. Mayer OM (2015) Chest Wall Hypoplasia: Principles and Treatment. Paediatric Respiratory Reviews 16: 30-34.
11. Kizer A, Muñoz A, Bennisar M, Martinez JM (2011) Iconographic case number 10 : Jarcho-Levin syndrome Prenatal diagnosis 22: 142-143.
12. Pardeshi KP (2012) Early sonographic diagnosis of jarcho-levin syndrome, will impact on further management. Int J Gynaecol Obstet 119: 738.