

Kidney Auto Transplantation: A Long Forgotten Technique?

Weigand K*, Schaarschmidt T, Fornara P and Kawan F

Department of Urology, Martin-Luther-University Halle-Wittenberg, Halle/S, Germany

*Corresponding author: Karl Weigand, Department of Urology, Martin-Luther-University, Halle-Wittenberg, Halle/S, Germany, Tel: +00493455574246; E-mail: karl.weigand@uk-halle.de

Received date: November 30, 2016; Accepted date: February 23, 2017; Published date: February 24, 2017

Copyright: © 2017 Weigand K, et al. This is an open-access article distributed under the terms of the Creative Commons Attribution License, which permits unrestricted use, distribution, and reproduction in any medium, provided the original author and source are credited.

Abstract

Introduction: A surgeon is constantly faced with the question to preserve the kidneys and their function for diverse lesions of the ureter. Often these lesions limit the kidneys in their performance.

Material and methods: Between 2001 and 2015, five renal auto transplantations were performed at our center. The patients' demographic, clinical and lab data was collected and analysed in the pre, intra, and postoperative phases.

Results: All five patients in our center undergoing surgery because of ureteral lesions. The retention results were when compared preoperatively to the date of discharge stable.

Conclusion: With the data we collected in this study we can only confirm the good long-term results after kidney auto transplantation with stable kidney function. Following the corresponding indication, kidney auto transplantation is a safe and effective procedure to retain the kidney's function.

Keywords: Kidney; Ureter lesions; Auto transplantation; Renal; Loin-Pain-Hematuria Syndrome; Reno vascular disorders

Background

A urologist is constantly faced with the question which options are available for the most diverse lesions of the ureter to preserve the kidneys and their function. Often these lesions are iatrogenic, or mutations due to tumors which limit the kidneys in their performance. Besides these disorders there are many others, for example vascular mutations, or pain syndromes, that require a therapy salvaging the kidney.

But which methods are available to reach a long-term solution? Sometimes it is necessary to return to methods long forgotten in our daily routine, such as kidney auto transplantation.

The first kidney auto transplantation was performed in 1963 by J.D. Hardy [1] in Minnesota. In this procedure, a ureteral lesion in the upper third of the ureter was transplanted into the ipsilateral Fossa ileac. As time went by, it became obvious that kidney auto transplantation is a safe and effective method to treat the most diverse disorders that would otherwise lead to a loss of the kidney's function. Among these are a multitude of complex disorders, such as iatrogenic injuries of the ureter, lithiasis, kidney pain syndrome, autoimmune deficiencies, such as retroperitoneal fibrosis, or renovascular disorders, such as stenosis of the distal kidney arteries, intrarenal aneurysms, arteriovenous deformities, and significant multivascular disorders [2-4].

Today, the largest indication for kidney auto transplantation is for vascular disorders. Especially with abdominal aneurysms of the aorta, stenosis of the aorta, such as the 'Mid Aortic Syndrom', renovascular aneurysms, or other vascular changes, it is an effective method to

retain the kidney's function. In most cases, a percutane transluminal angioplasty is the preferred and implemented method. Exspecially for abdominal aortic aneurysms the PTA is the method of choice which reduced the risk to lose the patient's life, whenever the danger of the loss of kidney function had increased. Because of this fact it is useful to inform the transplant unit about the intervention so a auto transplantation can be planed as the rescue therapy for the kidney function, even in single complicated renovascular disorders (isolated occlusive fibrodysplasia, arteriosclerotic lesions of the kidney artery, or inflammatory lesions) with which PTA does not promise success, or could even be dangerous, auto transplantation is a safe alternative [5-10].

Besides vascular reasons, there is by all means also an indication for a kidney auto transplantation for the, 'Loin-Pain-Hematuria Syndrome' [11], but this is being driven back by radiofrequency ablative denervation methods.

This method is also used to treat solid kidney tumors, especially when they occur bilaterally, and for urothelcarcinoma of the upper and middle thirds of the ureter. But these indications are also seen controversially from an oncological point of view and the indication should be rigorously evaluated [3,12].

Kidney auto transplantation can be seen as an option to retain the kidney's function with extensive tumor resections and extracorporeal, back table surgery'. In publications, there are repeated reports of good long-term results after auto transplantation regarding the kidney's function and the interval without tumors with patients with bilateral kidney carcinoma or a kidney cell carcinoma in individual kidneys [3,12-14]. The largest publication in this scope is by Mickisch [14]. Here he describes his experiences of 'back table surgery' and subsequent kidney auto transplantation with 36 patients with complex kidney tumors in single kidneys. In his collective group, 33

patients were without need for dialysis postinterventionally, and had an average tumor free interval of 2.8 years. But also other malignant tumors, such as the Wilms-Tumor, show good long-term results after kidney auto transplantation [15,16], but only in a small number of cases.

There are also individual case reports of benign tumor therapy that were successful using back table preparation and subsequent auto transplantation [17].

Over the years, experience and operation techniques have been so improved, especially in regards to nephron-saving tumor surgery under warm ischemia, that ischemic periods of up to 30 minutes can be tolerated. If, due to the size, location and technical situation (e.g. rapid cut examinations), longer ischemic periods are to be expected, cold ischemia must be used. This is both possible in situ, as well as ex situ, with subsequent auto transplantation [18-21]. In our opinion, ex situ intracranial tumor surgery in cold ischemia with subsequent auto transplantation should remain reserved for suitable individual cases.

When there are lesions in the ureter, though, the advantages of kidney auto transplantation become obvious. This counts both for extrinsic lesions, such as with Mb. Ormond, or retroperitoneal tumors [22-24], as well as for intrinsic lesions, such as with urothel carcinoma, or long ureteral stenosis [1,12,25-29]. This means that kidney auto transplantation is, besides the Ileuminterponate, a potent solution for restructuring after complex ureteral injuries with individual kidneys, or limited kidney function combined with a significant loss of the upper and middle third of the ureter [26,30,31].

Even though kidney auto transplantation is a less common therapy form in urology, it has not lost its justification and has found its place despite the arrival of new surgical methods, such as laparoscopy and robot-assisted laparoscopy [32-35].

In this study we will report our experience and results from five patients with long ureteral lesions and the therapy using kidney auto transplantation. Furthermore, we researched clinical and functional results in the pre- and postoperative phases.

Material and Methods

Between 2001 and 2015, five auto transplantations were performed on five patients at the clinic and polyclinic for Urology with a kidney transplant center at the Martin-Luther-University Halle-Wittenberg in Germany. The patients' demographic, clinical and lab data was collected and analyzed in the pre-, intra-, and postoperative phases.

The preoperative parameters used in this study were: age, body-mass-index (BMI), gender, etiology of the disease, kidney function (creatinine, urea and urine), blood pressure and antihypertensive medication.

In the direct operative and postoperative phases, the following parameter were gathered: surgery duration, warm and cold ischemia, handling time, blood loss, time spent at the hospital, peri- and post-surgery complications, kidney function (creatinine, urea and urine), blood pressure and antihypertensive medication.

The postoperative data was collected on site, as far as the patients were still in our care, or correspondingly by the doctor responsible for care after surgery. Aftercare took place in our regular kidney transplant ambulance so these patients undergoing sonographic and dopplerscan regularly to exclude urine stasis or stenosis of the arterial anastomosis (follow up for kidney transplants according to KDIGO guidelines

[36]). The kidney's long-term function and possible later complications were recorded.

With the patients included here, with one exception, based on the kind and gravity of the ureteral lesions, other rehabilitating measures retaining the kidney's function, such as Ileuminterponates, Psoas-Bladder-Hitch-Plastic or Boar plastic surgery were not indicated in our opinion. Also, in regards to co-morbidity, former surgery, and the general state of the patients, the method with the least risk of complications was chosen.

As the kidney transplantation center Sachsen-Anhalt, Germany has been integrated in our urological clinic since 1966, excellent expertise is available for the necessary handling of organ harvesting, perfusion, transplantation, vascular surgical knowledge, and experience with possible complications, so that kidney auto transplantation surgery can be carried out as a routine procedure.

For the operative planning of mending ureteral lesions, a uroradiological diagnosis was performed beforehand to verify the localization and length of the ureteral deficiency. For this, excretory urograms, ante or retrograde ureteropyelograms and cystograms were performed. The kidney's function was examined using kidney sequence scintigraphy on each side individually, to make a preoperative statement on the function of the individual kidneys. Where there were tumors, a Computed Tomography (CT) scan was also performed. Additionally, the patients received a Doppler scan of the pelvis axis to detect possible arteriosclerotic changes and to have optimum preconditions for the arterial anastomosis (Figure 1).

The kidney was harvested using a paracostal incision. In this procedure, the kidney was completely prepared in situ. The ureter is represented until below the constriction site, placed there, and initially remains on the kidney. After the vessels are prepared, the outlet of the artery renalis is clamped using the Satinsky-clamp and the artery is removed. The vein renalis is clamped using a vascular clamp and removed. Immediately after that, a tube is inserted into the artery renalis and the artery is perfused with 1000 ml Custodiol® 4°C. This leads to a conservation of the kidney with a reduction of metabolic processes, as with post mortal or live kidney donations. The stumps of the vessels are treated with Prolene 4 × 0. After obturating the harvested site, the patients were repositioned onto their backs and the auto transplantation was performed using ipsilateral hockey stick incisions to access the area. The vascular anastomoses were routinely performed using the end-to-side technique on the external iliac vessels. Should the anatomic disposition not allow this, it is also possible to perform an arterial anastomosis using end-to-end technique on the artery iliaca interna. The ureter was then removed proximally to the constriction and it was generally possible to implant, modified according to Lich-Gregoir. To protect the anastomoses, a DJ-stent was inserted intraoperative, which was generally removed after four weeks endoscopically. On the 7th postoperative day, a cystogram was performed, removing the urinary catheter. Only with patients with complete ureteral loss with an externally performed URS was it necessary to perform Boar plastic surgery, which was anastomosed to the renal pelvis, as there was no ureter. With these patients, the protection of the kidney's drain was not secured via DJ-stent, but by a cutaneous channeled MJ-catheter (Figure 2).

Result

The average patient age was 45.8 years (26-60 years of age); all were male and had an average BMI of 27.9 kg/m² Body Surface Area (BSA) (20.8-37.5 kg/m² BSA).

The reasons for the ureteral lesions were in two cases iatrogenic injuries to the ureter during ureterorenoscopies to remove kidney

stones. In one of these cases it led to complete ureter removal. One patient developed a retroperitoneal abscess after ventral lumbar spine stabilization due to Ewing's Sarcoma, with secondary long ureteral stenosis. Patient 4 suffered an iatrogenic long ureteral lesion during a hemi colectomy. Another patient suffered from long ureteral stenosis with Mb. Ormond.

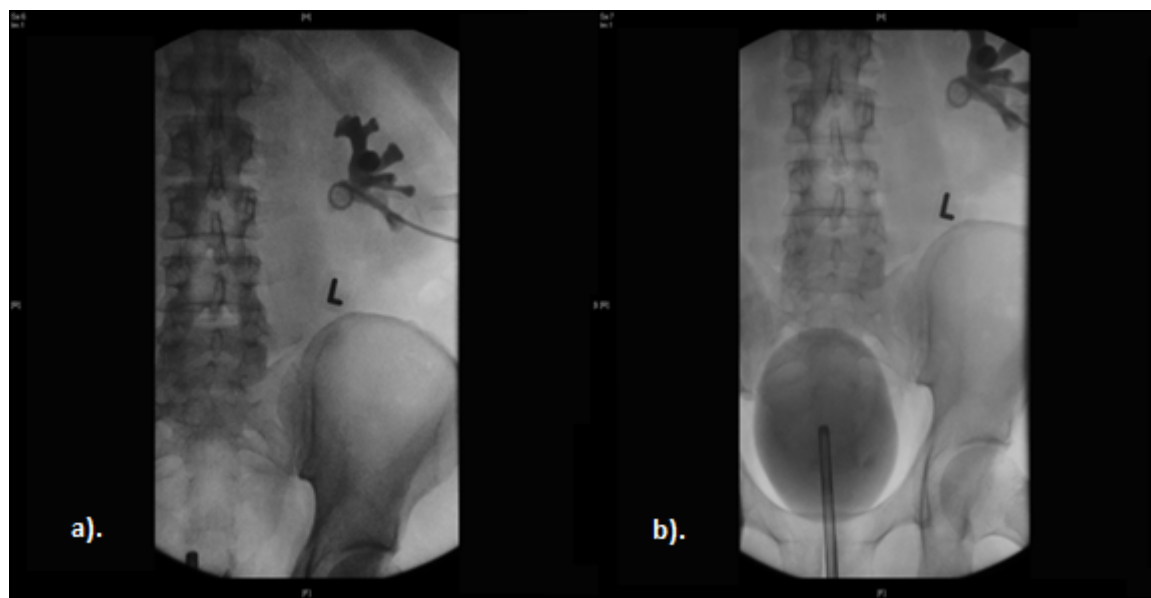


Figure 1: a) Pyelography b) Pyelography with cystogram after external iatrogenic total ureter avulsion during an ureterorenoscopy because of an upper ureteral stone, the ureter had torn intramurally at the ureteropelvic junction.

The kidney sequence scintigraphy on both sides individually was on average 51.4% (39%-87%) for the affected side. This average value stems from the fact that with one patient the affected side, the supposedly functional kidney and the other side, were practically without a function, this is not taken into consideration, so the corrected average value lies at 42.5% kidney function of the affected side.

Due to the complex ureteral injuries, intraabdominal inflammatory processes and extensive intraabdominal former operations performed beforehand, traditional ureteral reconstruction, such as ureteroureterostomies, Psoas-Bladder-Hitch or Boari plastic surgery or ileuminterponates were not possible with these patients, so that with these candidates kidney auto transplantation was performed.

Vascular nourishment with four patients was single-stem, only patient 5 presented a variation with four arteries and two veins.

The average operation time was 246 min (174-335 min). The average warm ischemic period was 107.5 sec (45-175 sec), the average cold ischemic period was 41.7 min (38-45 min) and the average handling time (anastomoses period until perfusion was cleared) 52.7 minutes (32-90 min).

Intraoperative blood loss was not evaluated, as the information provided was too imprecise, but patient 2 and patient 3 were transfused two erythrocyte concentrates during the surgery.

The average total duration of stay, partially with preoperative diagnosis, lasted 24.2 days (12-41 days), the average postoperative duration of stay was 17.6 days (10-34 days).

As can be seen in table 2, two patients suffered no complications, one patient had a drop in Hb postoperatively, but a revision was not necessary, bleeding could be restrained conservatively, and one patient suffered a urinary tract infection without any further importance postoperatively. Only with patient 2 was there massive postoperative hemorrhage which led to hemorrhagic shock, a urinary tract infection, and wound healing disorder which required revision. Urinomes, abscesses or constriction relapses did not occur in this group.

The complications according to the Clavien-Dindo classification were in 4 cases grade 2, only in one case with adiposities grade 3b because of wound healing disorder. So the auto transplantation is associated with low rate of CD grade 3 or higher complications.

The retention results were, when compared preoperatively to the date of discharge, stable, there was no significant deterioration of the kidney's functions. Also, after 6 and 12 months the results were still stable. As the patients were no longer in our care after twelve months, it was not possible to perform a standardized long term analysis for a further time period. But as the patients were repeatedly hospitalized due to other disorders, it was possible to gather further information on their kidneys' functions, which resulted in a stable function for up to six years after the auto transplantation at the most diverse of times for patients 2-5.

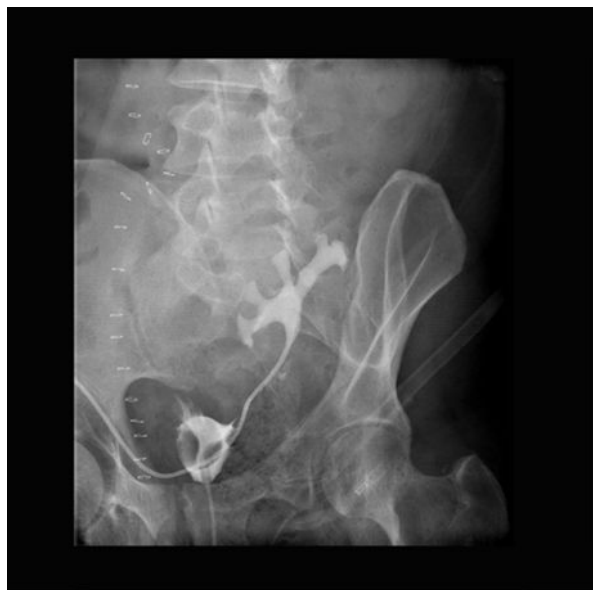

Figure 2: Antegrade depiction over MJ-stent 7th postoperative day after autotransplantation with Boari plastic surgery.

The characteristics of the patient group are shown in (Table 1).

In this group, kidney auto transplantation also showed no impact on blood pressure or antihypertensive medication between the preoperative situation and the time of discharge from the hospital.

Sonographic and Doppler sonographic exams during the postoperative phase, as well as the follow up for 12 months, showed a homogenic perfusion with normal spectra's of the auto transplanted kidneys. Only with patient 5, one of the pole vessels was no longer tracable from the 6th month without being able to detect a definite perfusion loss in the kidney.

Besides the five patients recorded here we found a patient during our research who received auto transplantation on his right side in our clinic in 1968 when he was aged 48. Due to missing documents on the

reasons for the auto transplantation, this patient was not included in our group. But it is remarkable with this patient, that in the hospital's files from 1999, 31 years after the kidney auto transplantation, the patient still showed a stable kidney function with a creatinine count of 99 μ mol/l with a homogenous perfusion and normal spectra without indication of a urinary transport disorder.

Discussion

Since the first kidney auto transplantation 1963 by J. D. Hardy [1] this method has established itself as a tested alternative procedure for patients with complex ureteral lesions or vascular and Reno vascular disorders [1-3,25]. Since this time, cases and studies which report good long term results with a selected group of patients have been published regularly. These patients usually suffer from long ureteral lesions, metabolic stone disorders, complex vascular and Reno vascular disorders and diverse malignoma [2-6,12,14,26,27]. In the care of experienced transplantation surgeons, kidney auto transplantation is a safe and efficient procedure to treat the above mentioned disorders. For these often very complex disorder patterns, the decision in which way they should be treated depends on many factors. Among these are e.g. patient age, anatomy and kidney function, etiology of the disorder, surgical and transplantation-surgical experience and former surgery [25].

With the data we collected in this study we can only confirm the good long term results after kidney auto transplantation stated in other publications. This counts both for the absence of recurrence with the patients in our group, as well as the stable kidney function after auto transplantation. But we were unable to determine an improvement of the kidney's function, as it has been described in other studies [25]. Postoperative complications in our patient group were fewer compared to other publications. According to the Clavien-Dindo classification it's a safe procedure with less complications grade 3 or higher. This could be connected to the kidney transplants performed since 1966 in Halle and the resulting experience with kidney harvesting, conservation, transplantation and patient management. At the same time our results emphasize the low risk with kidney auto transplantation. This means that auto transplantation for correspondingly long ureteral lesions, when other conventional reconstruction cannot guarantee success, are to be preferred.

	Patient 1	Patient 2	Patient 3	Patient 4	Patient 5
Age (in years)	49	60	26	37	57
Gender	male	male	male	male	male
BMI (kg/m² BSA)	31,4	37,5	24,6	20,8	25,6
Primary disease	iatrogenic ureteral avulsion	Ewing's sarcoma	iatrogenic ureteral lesion	iatrogenic ureteral lesion	Mb. Ormond
Side	left	left	left	right	right
Kidney sequence scintigraphy right/left in %	51/49	61/39	59/41	87/13	41/59
Surgery duration in minutes	243	253	218	174	335
Blood loss	not known	1800	not known	not known	not known
WIZ in sec	45	155	55	107	175

KIZ in min	38	45	40	42	44
Handling time in min	32	57	32	53	90
Total duration of stay in days	29	41	12	16	23
Postsurgery stay in days	22	34	10	11	11
Crea/eGFR in $\mu\text{mol/l/ml/min/1}$ presurgery	100/>60	113/>60	77/>60	163/44	89/>60
Crea/eGFR in $\mu\text{mol/l/ml/min/1}$ on discharge	100/>60	99/>60	98/>60	187/37	110/>60
Crea/eGFR in $\mu\text{mol/l/ml/min/1}$ after 6 months	98/>60	107/>60	98/>60	183/38	104/60
Crea/eGFR in $\mu\text{mol/l/ml/min/1}$ after one year	99/>60	101/>60	96/>60	189/37	98/>60

Table 1: Overview of the group of patients, characteristics and follow-up results.

	Patient 1		Patient 2		Patient 3		Patient 4		Patient 5	
	No.	C.D.C.	No.	C.D.C.	No.	C.D.C.	No.	C.D.C.	No.	C.D.C.
Bleeding	0	0	1	2	1	2	0	0	0	0
Infection	0	0	1	2	0	0	0	0	0	0
Wound healing disorder	0	0	1	3b	0	0	0	0	0	0
Urinoma/Abscess	0	0	0	0	0	0	0	0	0	0
Recurring stenosis	0	0	0	0	0	0	0	0	0	0
Urinary tract infection	0	0	1	2	0	0	1	2	0	0

Table 2: Intra- and postoperative complications No.: number of infection episodes without urinary tract infection C.D.C.: Complications according to the Clavien-Dindo classification.

Furthermore, kidney auto transplantation is an effective therapeutic remedy when a PTA or other endovascular interventional procedure is not applicable in complex Reno vascular medical conditions or disorders of the Aorta abdominalis.

The incidence of iatrogenic ureteral lesions is described in expert literature at 1-4% [27,37]. To treat long lesions of the upper and middle third of the ureter there are no binding recommendations or guidelines, these are rather often individual cases that demand extraordinary expertise from the operating surgeon [27,38].

With lesions of especially the lower third of the ureter there are a row of effective reconstructive surgical methods, such as uretero-ureterostomy, the Psoas-Bladder-Hitch plastic and Boar plastic surgery, transuretero-ureterostomy or transuretero-pyelostomy [26,28,39,40].

If there are long lesions or lesions of the upper third of the ureter, these methods often cannot be applied. The recommended treatment method in these cases is the use of Ileum- or appendixinterponates, as well as kidney auto transplantation. The decision, which therapy form is to be chosen must be made based on different factors. Among these are the surgeon's experience, the availability of interponates and the length and localisation of the ureteral lesion [29].

In contrast to kidney auto transplantation, an enterointerponate shows additional problems, besides possible postoperative

complications of the enterotomy. This method is frequently accompanied by electrolyte balance problems, reabsorption of metabolic products that are responsible for retention, and an excessive secretion of mucus [26,39]. Adding to that, an enterointerponate is accompanied by a chronic bacteriuria, which again in 25-34% of the cases leads to a deterioration of the kidney's function [29].

On the other hand, there are excellent long-term reports in publications on kidney auto transplantation [1,2,26,27,41]. In the largest of these studies with 27 patients, von Bodie et al were able to keep the kidney's function stable for 93% of the patients after kidney auto transplantation in a follow up time frame of 14 years [29].

Besides these urological indications for kidney auto transplantation there is a further row of indications with specific disorders of the abdominal aorta or with Reno vascular disorders. With these indications, kidney auto transplantation is always applicable when other surgical procedures or intravascular interventional procedures, such as the PTA, are not auspicious. From this point of view there are a row of publications that, such as the kidney auto transplantation under urological indication, are accompanied by excellent long-term results [5,6,42-44]. In this field, kidney auto transplantation has a fixed standing.

In regards to renal tumor surgery, or also tumor surgery of the renal pelvis and the upper and middle third of the ureter, there are good results [3,12-14], but the indication is to be carefully regarded with these indications and must be rated as the ultima ratio to retain the kidney's function.

Summary

Following the corresponding indication, kidney auto transplantation for long ureteral lesions of the upper or middle third of the ureter is a safe and effective procedure to retain the kidney's function. Especially with vascular disorders of the abdominal aorta or Reno vascular disorder, kidney auto transplantation has important significance. But kidney auto transplantation also demands extraordinary expertise from the surgeon in the fields of organ harvesting, organ conservation, transplantation and postoperative management. So its really necessary if an intervention is planned, which can lead to a loss of the kidney function, to inform the transplant unit about it. So the rescue therapie by a auto transplantation can be planed and proceded by experienced hands of a transplant surgeon.

References

1. Hardy JD (1963) High ureteral injuries. Management by autotransplantation of the kidney. *Jama* 184: 97-101.
2. Novick AC, Jackson CL, Straffon RA (1990) The role of renal autotransplantation in complex urological reconstruction. *J Urol* 143: 452-457.
3. Wotkowicz C, Libertino JA (2004) Renal autotransplantation. *BJU Int* 93: 253-257.
4. Flechner SM, Noble M, Tiong HY, Coffman KL, Wee A (2011) Renal autotransplantation and modified pyelovesicostomy for intractable metabolic stone disease. *J Urol* 186: 1910-1915.
5. Chiche L, Kieffer E, Sabatier J, Colau A, Koskas F, et al. (2003) Renal autotransplantation for vascular disease: late out-come according to etiology. *J Vasc Surg* 37: 353-361.
6. Sevmis S, Karakayali H, Boyvat F, Aytakin C, Haberal M (2006) Renal autotransplantation for the treatment of complex renovascular hypertension. *Transplant Proc* 38: 3412-3415.
7. Rooden VJ, Baalen VJM, van Bockel JH (2003) Spontaneous dissection of renal artery: long-term results of extracorporeal reconstruction and autotransplantation. *J Vasc Surg* 38: 116-122.
8. Zhang H, Li FD, Ren HL, Zheng YH (2014) Aortic bypass and orthotopic right renal autotransplantation for midaortic syndrome: a case report. *BMC Surg* 14: 86.
9. Kim HK, Lee JM, Cho MH, Huh S (2014) Aortic stent and renal autotransplantation for the management of renovascular hypertension with Takayasu's arteritis: report of a case. *Surg Today* 44: 944-947.
10. Berloco PB, Sandri LGB, Guglielmo N, Lai Q, Melandro F, et al. (2014) Bilateral ex vivo repair and kidney autotransplantation for complex renal artery aneurysms: A case report and literature review. *Int J Urol* 21: 219-221.
11. Thauat O, Kervella D, Matillon X, Rabeyrin M, Martin X, et al. (2013) Allotransplantation of kidney from unrelated living donor with loin pain haematuria syndrome. *2013 Steunstichting ESOT* 27: e24-e26.
12. Pettersson S, Brynger H, Henriksson C, Nilson AE, Ranch T (1984) Treatment of urothelial tumors of the upper urinary tract by nephroureterectomy, renal autotransplantation, and pyelocystostomy. *Cancer* 54: 379-386.
13. Holmäng S, Johansson SL (2005) Tumours of the ureter and renal pelvis treated with resection and renal autotransplantation: a study with up to 20 years of follow-up. *BJU Int* 95: 1201-1205.
14. Mickisch GHJ (2007) Renal cell cancer: bench surgery and autotransplantation for complex localised disease. *Eur Urol* 6: 544-548.
15. Novick AC, Jackson CL, Straffon RA (1990) The role of renal autotransplantation in complex urological reconstruction. *J Urol* 143: 452-457.
16. Desai D, Nicholls G, Duffy PG (1999) Bench surgery with autotransplantation for bilateral synchronous Wilms' tumor: a report of three cases. *J Pediatr Surg* 34: 632-634.
17. Zhenga J, Zhoua Z, Chena Z, Fanga Q, Liub H, et al. (2014) Bench surgery with renal autotransplantation for angiomylipoma of renal sinus. *Transplant Proc* 46: 1281-1285.
18. Becker F, Siemer S, Rotering J, Suttman H, Stöckle M (2008) Organ erhaltende Nierentumorchirurgie. *Der Uro* 47: 215-223.
19. Janetschek G, Abdelmaksoud A, Bagheri F, Zahrani AH, Leeb K, et al. (2004) Laparoscopic partial nephrectomy in cold ischemia: renal artery perfusion. *J Urol* 171: 68-71.
20. Steffens J, Humke U, Ziegler M, Siemer S (2005) Partial nephrectomy with perfusion cooling for imperative indications: a 24-year experience. *BJU Int* 96: 608-611.
21. Marberger M (1978) Ischämie und regionale Hypothermie bei Operationen am Nierenparenchym. *Fortschritte der Urologie und Nephrologie* 13:978-979.
22. Bansal VK, Misra MC, Sharma A, Chhabra A, Murmuals LR (2013) Giant retroperitoneal liposarcoma- renal salvage by autotransplantation. *Indian J Surg* 75: 159-161.
23. Basiri A, Shakhsealim N, Nasiri MR, Radfar MH (2014) Renal autotransplantation in postchemotherapy retroperitoneal lymph node dissection: a case report. *Uro J* 11: 1362-1365.
24. Woods T, Jennings NB, Fernandez HT, Onaca N, Carlile BK, et al. (2015) Renal autotransplantation in lynch syndrome: a viable option in a patient with contralateral metachronous ureteral cancer. *Am J of Transplant* 15: 2507-2510.
25. Hau HM, Bartels M, Tautenhahn HM, Morgul MH, Fellmer P, et al. (2012) Renal autotransplantation - a possibility in the treatment of complex renal vascular diseases and ureteric injuries. *Ann Transplant* 17: 21-27.
26. Shekarriz B, Lu H, Duh Q, Freise CE, Stoller ML (2001) Laparoscopic nephrectomy and autotransplantation for severe iatrogenic ureteral injuries. *Urology* 58: 540-43.
27. Milonas D, Stirbys S, Jievaltas M (2009) Successful treatment of upper ureteral injury using renal autotransplantation. *Medicina (Kaunas)* 45: 988-991.
28. Benson MC, Ring KS, Olsson CA (1990) Ureteral reconstruction and bypass: experience with ileal interposition, the boari flap-psoas hitch and renal autotransplantation. *J Urol* 143: 20-23.
29. Bodie B, Novick AC, Rose M, Straffon RA (1986) Long-term results with renal autotransplantation for ureteral replacement. *J Urol* 136: 1187-1189.
30. Armenakas NA (1999) Current methods of diagnosis and management of ureteral injuries. *World J Urol*, 17: 78-83.
31. Soto JS, Phillips M, Cernigliaro J, Haley W (2012) renal autotransplantation for iatrogenic high-grade ureteric stricture. *Case Rep Urology* pp: 1-3.
32. Cheng YT, Flechner SM, Chiang PH (2014) The Role of Laparoscopy-assisted Renal Autotransplantation in the Treatment of Primary Ureteral Tumor. *Ann Surg Oncol* 21: 3691-3697.
33. Gordon ZN, Angell J, Abaza R (2014) Completely intracorporeal robotic renal autotransplantation. *J Urol* 192:1516-1522.
34. Meng MV, Freise CE, Stoller ML (2004) Expanded experience with laparoscopic nephrectomy and autotransplantation for severe ureteral injury. *J Urol* 169:1363-1367.
35. Bluebond-Langner R, Rha KH, Pinto PA, Varkarakis J, Douyon E, et al. (2004) Laparoscopic-assisted renal autotransplantation. *Urology* 63:853-856.
36. American Journal of Transplantation (2009) KDIGO Clinical Practice Guideline for the Care of Kidney Transplant Recipients. 9: S131-S155.

-
37. Trottmann M, Tritschler S, Graser A, Strittmatter F, Becker A, et al. (2007) Injuries of the renal pelvis and ureter. diagnosis and management. *Urologe A* 46: 927–934.
 38. Wein AJ, Kavoussi LR, Novick AC et al: *Campbell-Walsh urology*. In: McAninch JW, Santucci RA, editors. Renal and ureteral trauma. 9th ed. Philadelphia, Saunders Elsevier, 2007; 1274–1293.
 39. Bretan PN, Malone MJ (1999) Complex renal reconstruction. *Urol Clin North Am* 26: 201–217.
 40. Png JC, Chapple CR (2000) Principles of ureteric reconstruction. *Curr Opin Urol* 10: 207-212.
 41. Webster JC, Lemoine J, Seigne J, Lockhart J, Bowers V (2005) Renal autotransplantation for managing a short upper ureter or after ex vivo complex renovascular reconstruction. *BJU Int* 96: 871–874.
 42. Sorcini A, Libertino JA (1999) Vascular reconstruction in urology. *Urol Clin North Am* 26: 219–34.
 43. Brekke IB, Sødal G, Jakobsen A, Bentsdal O, Pfeffer P, et al. (1992) Fibromuscular renal artery disease treated by extracorporeal vascular reconstruction and renal autotransplantation: short- and long-term results. *Eur J Vasc Surg* 6: 471–476.
 44. Gallagher KA, Phelan MW, Stern T, Bartlett ST (2008) Repair of complex renal artery aneurysms by laparoscopic nephrectomy with ex vivo repair and autotransplantation. *J Vasc Surg* 48: 1408–1413.