

Large Borderline Ovarian Tumor: A Case Report

Vlad Teodor Berbecar*, Cristina Elena Zeca, Sorin Aldoescu, Cornelia Ivancu, Alina Draghia and Florin Draghia
Department of Internal Medicine, Fundeni Clinical Institute, Romania

Abstract

Background

This article reports the case of a 59 year old woman who presented to the hospital with an enlarged abdomen and no other symptoms. The clinical and paraclinical investigations revealed a massive ovarian tumour which had occupied most of her abdomen. The patient underwent surgery and the histological examination revealed a mucinous cystadenoma. The purpose of this paper is to highlight the importance of thorough examination of women with vague symptoms and to emphasize the necessity of a good collaboration between medical specialties (primary physician, clinician, radiologist, pathologist, surgeon).

Keywords: Large ovarian tumour; Mucinous cystadenoma; Borderline mucinous tumour

Introduction

Most tumors of the ovary can be placed into one of three major categories; surface epithelial-stromal tumors, sex cord-stromal tumors, and germ cell tumors according to the anatomic structures from which the tumors presumably originate.

Surface epithelial-stromal tumors are believed to originate from the surface epithelium of the ovary. They are classified as benign if they lack exuberant cellular proliferation and invasive behavior; as borderline (also known as atypically proliferating or of low malignant potential) if there is exuberant cellular proliferation but no invasive behavior; and as malignant if there is invasive behavior. Surface epithelial-stromal tumors account for approximately 60% of all ovarian tumors and approximately 90% of malignant ovarian tumors.

Mucinous tumors are epithelial ovarian tumors formed by cells that resemble either those of the endocervical epithelium (endocervical or mullerian type) or, more frequently, those of the intestinal epithelium (intestinal type). Benign mucinous tumors are multiloculated cysts that are filled with opaque, thick, mucoid material. They account for up to one-fourth of all benign ovarian neoplasms and 75-85% of all mucinous ovarian tumors. Benign mucinous tumors most frequently occur between the third and fifth decades of life and are rarely bilateral [1]. Surgical removal is curative. The differential diagnosis is broad, including pancreatic cystic lesions, mesenteric cyst, lymphocele, cystic lymphangioma, cystic mesothelioma, teratoma, cystic hydatidosis, intraperitoneal pseudomyxoma peritonei and peritoneal carcinomatosis [2].

The concept of borderline epithelial tumors of the ovary has faced controversy since their discovery in 1898 by Hermann Johannes Pfannenstiel, who illustrated and described papillary ovarian cystadenomas with clinical features that stand on the border of malignancy [3]. Borderline tumors have been thought to possibly represent an intermediate stage in the stepwise progression to carcinoma. In the FIGO classification, the common primary epithelial tumors were subdivided into three groups: benign cystadenoma; cystadenoma with proliferating activity of the epithelial cells and nuclear abnormalities, but with no infiltrative destructive growth (low potential malignancy); and, cystadenocarcinoma [4]. According to the WHO definition, a borderline epithelial tumor lacks obvious invasion of the stroma and has mitotic activity and nuclear abnormalities intermediate between clearly benign and unquestionably malignant tumors of a similar cell [5].

In 1988, two basic types of borderline mucinous tumors were delineated: the intestinal type and the endocervical-like (Mullerian) type. The endocervical-like type is clinically and pathologically closely related to serous borderline tumors with which it is often mixed (also known as seromucinous borderline tumor and Mullerian borderline mucinous tumor). It accounts for only 5-14% of borderline mucinous tumors [6] and has little in common with intestinal-type mucinous tumors. The pure and mixed endocervical-like borderline mucinous tumors have a high association with endometriosis which is the site of origin of the tumors in some instances [7].

This report presents the short evolution (3-4 months) of a large mucinous cystadenoma in a 59 year old Caucasian woman.

Materials and Methods

A 59 year old Caucasian woman presented to the Clinical Hospital "Dr. Ioan Cantacuzino" in Bucharest with a progressively enlarged abdomen without manifesting any other clinical signs. The patient stated that she had first noticed her abdomen increasing in size over 3 months ago but she chose to ignore it as she did not feel any pain or discomfort. The physician's first presumable diagnosis was that the woman could be pregnant.

The patient's history revealed that she had hydrocephalus in 1998 and had had a ventriculoperitoneal shunt inserted. During her lifetime she has given birth to 5 babies and has had 3 abortions. She entered menopause when she was 48 years old. She is a moderate smoker and occasionally drinks alcohol.

Results

Physical examination revealed an enlarged abdomen with a palpable fixed formation along the xifo-pubian line. The formation did not provoke any pain when palpated and the percussion revealed dull sounds. The blood work of the patient came back normal having only a

*Corresponding author: Vlad Teodor Berbecar, Department of Internal Medicine, Fundeni Clinical Institute, Bucharest, Romania, Tel: +0723559798; E-mail: vberbecar@gmail.com

Received December 07, 2015; Accepted January 17, 2016; Published January 27, 2016

Citation: Berbecar VT, Zeca CE, Aldoescu S, Ivancu C, Draghia A, et al. (2016) Large Borderline Ovarian Tumor: A Case Reports. Surgery Curr Res 6: 258. doi:10.4172/2161-1076.1000258

Copyright: © 2016 Berbecar VT, et al. This is an open-access article distributed under the terms of the Creative Commons Attribution License, which permits unrestricted use, distribution, and reproduction in any medium, provided the original author and source are credited.

slightly elevated hemoglobin - 15.5 mg/dl (N=11.7-15) and hematocrit - 48.6% (N=36-48) (Figure 1).

The ultrasonography showed a large cystic formation (19/19/31 cm) with a well-defined wall and a hypoechoic image inside of approximately 12.6 cm in diameter which contained multiple cysts. The formation was a space occupying process which had pushed the entire colon and the intestinal loops; it had moderate vascular drawings and was adherent to the abdominal aorta and the inferior vena cava. The image was suggestive for a lymphangioma.

The CT revealed a large cystic formation occupying most of the abdomen (Figure 2). It had a good vascular supply which seemed to originate from the vascular pedicle of the left ovary. The tumor was pushing on the urinary bladder and the uterus; the kidneys had a grade 1 hydronephrosis. All the intestinal loops and the supramezocolic organs were pushed against the diaphragm.

Surgical intervention followed. A large xifo-pubic incision was made to allow access to the entire tumor. Left salpingo-oophorectomy was performed. The uterus and right adnexa looked healthy and there was no apparent lymph node infiltration. The cyst, which was adherent to the left ovary was removed (it measured in diameter 28/22 centimeters) and 4L of liquid were drained from it. Intraoperative histology using frozen section is useful; however the technique was unavailable at the time [8].

Post-operative recovery was uneventful. The patient was discharged after 5 days of close observation and told to come back every 6 months during a period of 2 years for follow-up [9,10] (Figures 3 and 4).

The histological examination revealed a multilocular mucinous cystadenoma with borderline areas and necrosis. The left salpinx had thickened mucus creases. Towards the internal layer of the cyst there are papillary proliferations and ramifications. You can also observe unistratified and pluristratified layers of cylindrical and cubic cells of different sizes along with areas that appear to be squamous metaplasia. In our samples we can see intensely basophilic nuclei and cytoplasm with

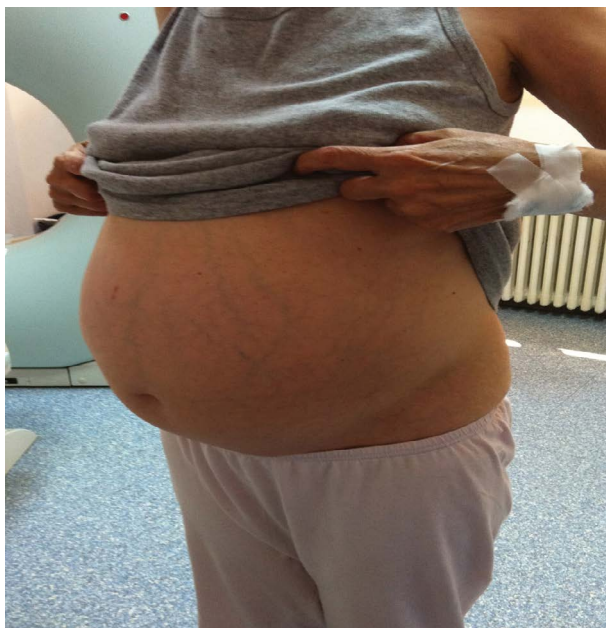

Figure 1: The patient first presented to the hospital with an enlarged abdomen and visible collateral venous circulation.

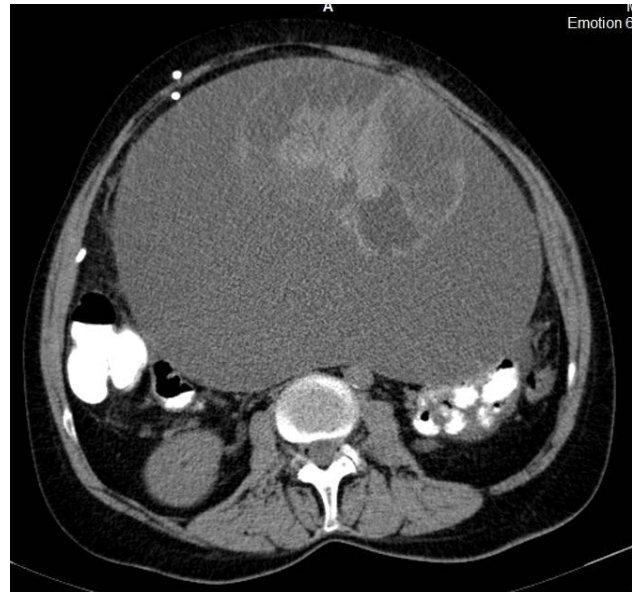


Figure 2: CT scan transverse section of the abdomen. Massive tumor occupying most of the abdomen. Multiple cysts can be observed inside.

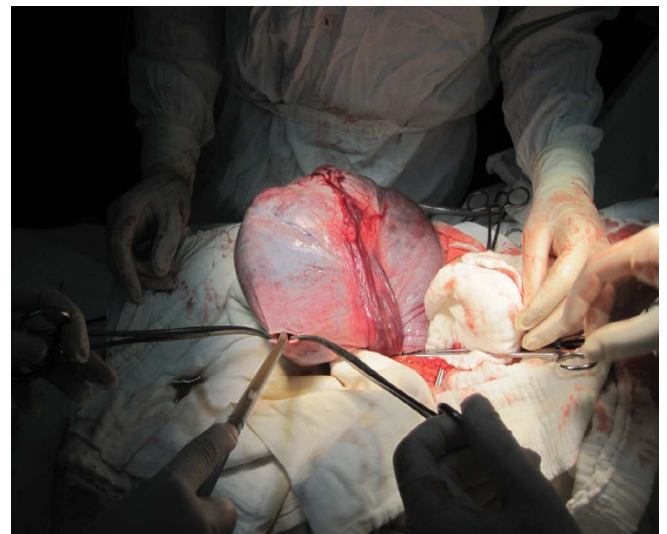

Figure 3: Intraoperative image. The tumor was isolated and had to be drained (4L of liquid were extracted) before it could be removed.

various degrees of acidophilia. This suggests a highly increased rate of division which is specific for borderline tumors (Figure 5).

The epithelium of the cyst is made out of one layer of cubic cells mixed with cylindrical cells. The cells have a basal nucleus. The stroma is rich in fibroblasts with frequent capillaries. Col H.E. x 10.

Discussion

Mucinous tumors of the ovary demonstrate marked morphological diversity, both within the group as a whole and in individual tumors. A major change that has occurred relatively recently is the subdivision of mucinous tumors into those of intestinal and Müllerian types. In contrast to intestinal-type tumors, Müllerian borderline tumors are typically lined by endocervical-like mucinous cells and often

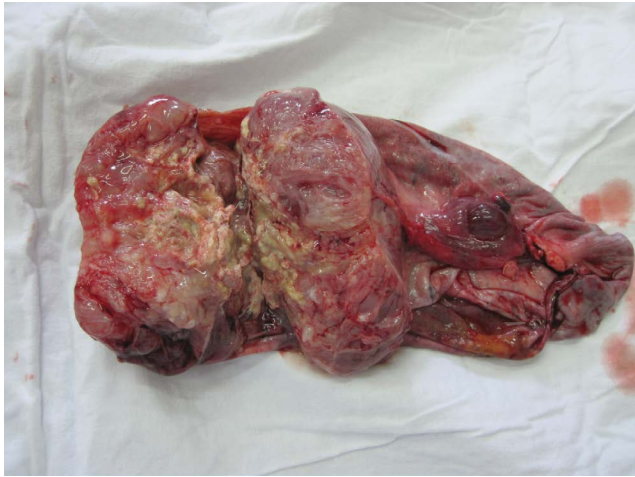

Figure 4: Tumoral formation originating from the left ovary.

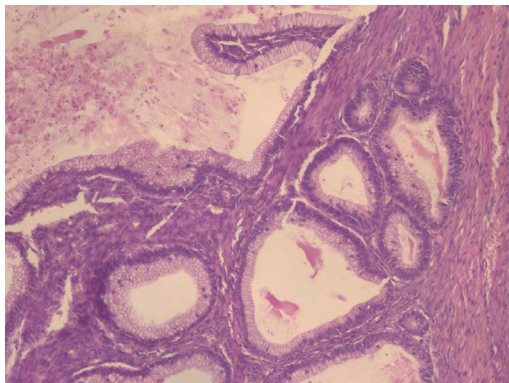


Figure 5: Simple multilocular ovarian cystadenoma.

have distinctive polygonal cells with eosinophilic cytoplasm. They are characterized by large papillae similar to those seen in serous borderline tumors and occasionally in endometrioid borderline tumors. Mullerian-type tumors are also frequently associated with pelvic endometriosis, unlike intestinal-type tumors. A morphological continuum exists from mucinous cystadenoma to mucinous carcinoma, and epithelium that varies from benign to borderline to frankly malignant is frequently found within a single tumor. Because of this continuum, drawing the line between these three major categories of neoplasia can be problematic [11]. A tumor composed predominantly of cystadenoma with a minor component of borderline tumor (<10%) should be primarily diagnosed as a mucinous cystadenoma. Upon gross pathologic examination, borderline mucinous tumors are similar to benign mucinous tumors but may have solid regions and exhibit papillae projecting into the cyst chambers [12].

Ovarian tumors are seen frequently in medical practice but giant tumors that have a rapid growth and present with no symptoms are rare. Early detection is the key to improving the outcome of the patient but it is difficult to discover something that the patient does not complain about. Usual symptoms that can be seen in such patients include: pressure or pain in the abdomen or legs, indigestion, diarrhea, constipation, gas, polyuria, shortness of breath, vaginal bleeding. Screening is very important and should be done regularly; however, in this case it was unhelpful because of the rapid onset and development of the tumor. Surgery with the intent of excising the lesion is the elected method of treatment and it can be

performed either radical or conservative depending on the histological type of the tumor [13,14].

Conclusion

This patient is presented as a special case because of the rapid onset and evolution of the tumor as well as its impressive size and evolution which are characteristic for borderline tumors of the ovary.

In our patient, conservative surgery was chosen because of the macroscopic and microscopic (extemporaneous histopathology) aspect of the tumor. Left salpingo-oophorectomy was performed because the mass was adherent to the left ovary and the left fallopian tube was unhealthy. The uterus and right adnexa were left intact as there was no apparent infiltration or any other signs of metastasis. Conservative surgery as ovarian cystectomy and salpingo-oophorectomy is adequate for benign lesions. Postoperative monitoring of patients plays a critical role in case of any possible relapses, especially consequent malignant evolutions. The follow-up is done by performing ultrasound and contrast CT every 6 months for a minimum of two years post operatory.

Acknowledgement

This paper was cofinanced from the European Social Fund through Sectoral Operational Programme - Human Resources Development 2007-2013, project number POSDRU/1871.5/S/155605, entitled "Scientific excellence, knowledge and innovation through doctoral programs in priority areas", Beneficiary - University of Petrosani.

References

1. Vivien WC, Bernardo R, Jeffrey LK, Timothy RC, Xiao CW, et al. (2003) Pathology and Classification of Ovarian Tumors. American Cancer Society 97: 2631-2642.
2. Seung EJ, Jae ML, Sung ER, Jae YB, Jung IJ, et al. (2002) CT and MR Imaging of Ovarian Tumors with Emphasis on Differential Diagnosis. RadioGraphics 22: 1305-1325.
3. Pickel H, Tamussino K (2003) History of gynecological pathology. XIV. Hermann Joannes Pfannenstiel. Int J Gynecol Pathol 22: 310-314.
4. FIGO (1971) International Federation of Gynecology and Obstetrics. Classification and staging of malignant tumors in the female pelvis. Acta Obstet Gynecol Scand 50: 1-7.
5. William RH (2005) Borderline epithelial tumors of the ovary. Mod Pathol 18: S33-S50.
6. Serov SF, Scully RE, Sobin LH (1973) Histological Typing of Ovarian Tumors. World Health Organization: Geneva.
7. Lee KR, Scully RE (2000) Mucinous tumors of the ovary: a clinicopathologic study of 196 borderline tumors (of intestinal type) and carcinomas, including an evaluation of 11 cases with 'pseudomyxoma peritonei'. Am J Surg Pathol 24: 1447-1464.
8. Mohammed ABF, Vijay KA, Hanan F (2015) "Role of frozen section in the intraoperative management of ovarian masses." Middle East Fertility Society Journal 20: 97-101.
9. Mohammad KM, ZahraY (2010) A Huge Ovarian Cyst in a Middle-Aged Iranian Female. Case Rep Oncol 3: 165-170.
10. Ie MS, Robert JK (2005) Molecular Pathogenesis of Ovarian Borderline Tumors: New Insights and Old Challenges. Clin Cancer Res 11: 7273-7279.
11. Melinda FL, Robert HY (2008) Mucinous tumors of the ovary. Diagnostic Histopathology 14: 366-387.
12. Brigitte MR, Andre KB, Gilks CB, Maria JM, Elvio S, Bruce AW, et al. (2004) Young: Mucinous Borderline Ovarian Tumors: Points of General Agreement and Persistent Controversies Regarding Nomenclature, Diagnostic Criteria, and Behavior. Hum Pathol 35: 949-960.
13. Barbara AC, David MG, Harry LE (1985) Mucinous Tumors of the Ovary - A Clinicopathologic Study of 7 Cases. Cancer 55: 51958-1962.
14. Claes GT, Gunnar K, Amin M (2000) Surgery for Borderline Tumor of the Ovary. Semin Surg Oncol 19: 69-75.