

Preferences in the Aesthetic Appearance of the Female External Genitalia

Christopher J Salgado^{1*}, Lydia A Fein MD MPH², Renee Gasgarth¹, Priscila Sanchez³, Dalila Lo Bue¹, Brian A Crosland⁴, Ashley Taggart BS⁵, Madison Rumbaut¹ and Ajani Nugent¹

¹Division of Plastic, Aesthetic and Reconstructive Surgery, University of Miami Miller School of Medicine Miami, USA

²Department of Obstetrics and Gynecology, University of Miami Miller School of Medicine, USA

³Department of Surgery, University of Miami Miller School of Medicine, USA

⁴Department of Obstetrics and Gynecology, University of California, USA

⁵University of Miami Miller School of Medicine, USA

*Corresponding author: Christopher J. Salgado, MD, Division of Plastic, Aesthetic and Reconstructive Surgery, 1120 NW 14th St, Clinical Research Building 4th floor, Miami, Florida 33136, USA, Tel: 305-243-4500; Fax: 305-243-4535; E-mail: salgado_plastics@hotmail.com

Received date: January 08 2016, Accepted date: February 10, 2016, Published date: February 17, 2016

Copyright: © 2016 Christopher JS, et al. This is an open-access article distributed under the terms of the Creative Commons Attribution License, which permits unrestricted use, distribution, and reproduction in any medium, provided the original author and source are credited

Abstract

Objective: In recent years, women have become more dissatisfied with the appearance of their labia minora, in particular their width, shape, and symmetry, prompting increased requests for labiaplasty. This has been attributed to the popular depiction of female genitalia in media outlets as homogenously hairless, symmetrical, and without protruding labia minora. Over-reduction of labia minora, although requested by patients, should not be performed due to their physiologic importance.

Methods: We designed a survey to better understand preferences for the aesthetic appearance of female external genitalia. Survey Monkey was used to distribute an online questionnaire to a convenience sample of authors' contacts. Respondents were asked to refer to three images of female external genitalia-varying in labia minora width but all still physiologically normal-and select the image that they felt to be most normal and most attractive, respectively. Pearson's chi square test with significance level of 5% was used for statistical analysis.

Results: Overall 95.8% (767/800) selected non-visible or slightly visible labia as the most "normal" variants, and 96.6% (773/800) selected either A or B for the most "attractive" variants of labia minora. Respondents selected images most consistent with popular culture depictions of genitalia, which seem to be driving genital plastic surgery requests.

Conclusion: Given these findings, we recommend a discussion with patients about preferences and a belief regarding what is truly normal and encourages more widespread media visibility and education about normal physiologic variability in female external genitalia.

Keywords: Labia minora; Labiaplasty; Vulva; Female genital cosmetic surgery

Introduction

The vulva, a collective term for female external genitalia, is largely comprised of the labia major, labia minora, clitoral hood and clitoris. The labia major are cutaneous folds of adipose and fibrous tissue that extend from the mons pubis to the perineum. Under normal physiologic conditions, they converge along the midline to protect the other structures of the external genitalia [1]. The labia minora are smaller cutaneous folds that separate the labia major from the vaginal orifice. They guide the urinary stream during micturition and also play a role in sexual response due to their highly innervated edges and vasocongestive properties [2-5].

Size, shape, and color of labia major and minora are known to vary and can be influenced by age, parity, disease, or simple congenital formation [6-10]. Among a cohort of British women, Lloyd et al. demonstrated labia major and labia minora ranging from 7-12 cm and 2-10 cm in length, respectively, and labia minora ranging from 7-50 mm in width-the distance measured from the vaginal introitus to the most laterally projecting tip of the labia minora [7].

In recent years an increasing number of women have sought female genital cosmetic surgery (FGCS), most commonly labiaplasties [11-15]. In 2013, ASAPS reported that 5,070 labiaplasties were performed, a 44% increase from 2012 [14], and in the United Kingdom, the National Health Service reported a 200% increase in labiaplasties performed between 1998 and 2008 [15]. Though also performed for functionality, labiaplasty is most commonly requested for aesthetic reasons, in order to reduce the width of the labia minora and lessen their protrusion past the labia major [11,16-20].

In current literature, the rise in labiaplasty has been attributed to the popularization of images of female genitalia in media outlets, on the Internet, and in pornography that propagate a prepubescent representation of the vulva-hairless, symmetrical, and without protrusion of labia minora [21-24]. The portrayal of female genitalia in this manner has been shown to influence women's perceptions of normality and be a motivating force for the desire to alter one's genitalia [25-27]. Without a spectrum of female genitalia represented, it is possible that persons whose genitalia differ from the popular

media portrayal will question if their vulvae are attractive or normal. As the popularity of labiaplasty increases, it is important for providers to be aware of prevailing opinions of labia that may be driving their patients' motivations for seeking this procedure. Accordingly, the aim of this study is to assess preferences for the aesthetic appearance of female external genitalia across various demographic variables and to ascertain participants' reasons for their preferences.

Methods

Survey Monkey used to administer a six-question survey from July 2014 to September 2014. Though not a validated survey, we replicated our previously disseminated Internet-based survey regarding male genitalia. A brief description and survey website link were sent through e-mail, SMS messaging, and social media to a convenience sample of the study authors' personal and professional contacts within the United States and internationally. Because this study surveyed a convenience sample that did not include patients, it was exempt from institutional review. Participation was, optional, anonymous and limited to adults

(>/18 years old). We did not restrict our sample population based upon age, gender, or any other demographic criteria, because the purpose was to assess the preferences for female genitalia across all persons, not just those who might be seeking surgery.

The first four questions collected demographic data. In the interest of providing a clear understanding for participants, we opted to use common vernacular for terms relating to gender identity and sexual orientation. Therefore, with no intention of conflating gender and sex in our data analysis or discussion, we asked respondents to select their gender identity from the terms female, male, transgender female, and transgender male. These terms will thus be used when discussing our results. Similarly, sexual orientation options included heterosexual, homosexual, bisexual, and pansexual. For both categories, participants were given the "other" option with the opportunity to self-identify both in gender and sexual orientation.

The last two survey questions asked respondents to consider three graphically designed images of vulvae, which varied only in labia minora protrusion (Figure 1).

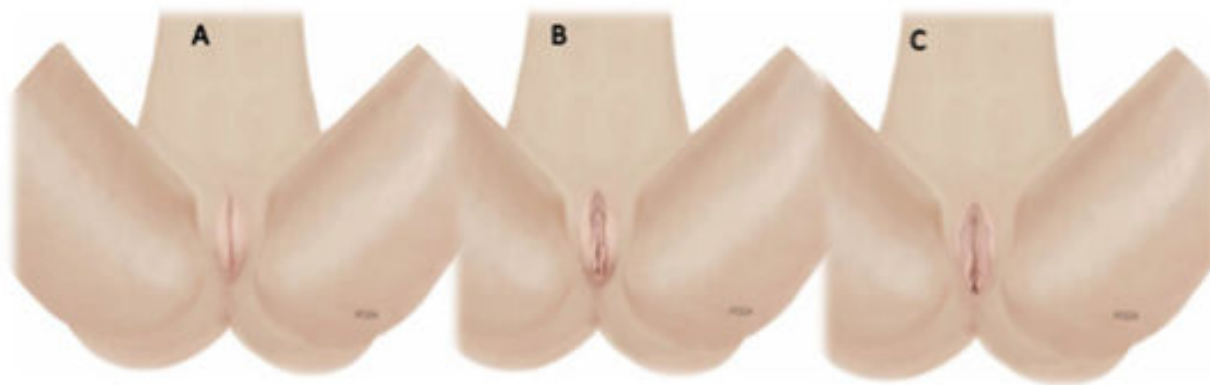

Figure 1: The options depicted the labia major with non-visible labia minora (A), with barely visible labia minora, protruding only to the distal edge of the labia major (B) and with protrusion of the labia minora beyond the labia major (C). All three depict normal variants of labia minora.

The questions prompted respondents to select the image that they felt was most "normal" and most "attractive", respectively. Specifically, "In your opinion, which genital region (labia) appears most normal?" and "In your opinion, which genital region (labia) appears most attractive?"

A fixed-response system was used for the final two opinion-based questions, but each question was associated with an open-ended response box for participants to explain their answer selection. Two authors reviewed the responses to the open-ended questions and categorized the responses into eight categories. They also excluded those responses that were not applicable to or did not address the posed questions.

We used graphically designed images rather than photographs in order to control for variables other than labia minora protrusion. Using clinical photographs would require that each photograph feature a different person's genitalia, undoubtedly introducing variables that might influence participants' choices. Given the popularity of depilated genitalia in society, we drew the images without pubic hair to eliminate another variable that may have influenced respondents' opinions.

IBM SPSS version 22.0.0.0 software was used for analysis. Associations between answer responses to the questions of female genital normality and attractiveness as well as distributions of answer responses to these questions across demographic variables were investigated by Pearson's chi square tests with significance level of 5%.

Results

The survey was completed by 800 persons in 26 countries, with the majority of respondents from the United States (87.6%, 701/800). Each survey question had a 100% completion rate, thus having no impact on statistical analysis. Respondents were asked to identify their age within certain ranges. Most respondents were between 25 and 34 years old (48.1%, 385/800) and predominantly cisgender, identifying as either female (42.6%, 341/800) or male (56.8%, 454/800). Four respondents identified as transgender (0.5%) and one person identified as "Other" (0.1%). Sexual orientation of respondents was mostly heterosexual (92.3%, 738/800). Complete demographic data are presented in (Table 1).

Variable	n (%)
18-24	194 (24.3)
25-34	25-34 385 (48.1)
35-44	35-44 145 (18.1)
45-54	45-54 51 (6.4)
55-64	55-64 19 (2.4)
65-74	65-74 4 (0.5)
75+	75+ 2 (0.3)
Country of origin	
USA	701 (87.6)
Other*	99 (12.4)
Gender	
Female	341 (42.6)
Male	2 (0.3)
Male-to-Female transgender	454 (56.7)
Other**	454 (56.7)
Female-to-Male transgender	2 (0.3)
Other**	1 (0.1)
Sexual Orientation	
Heterosexual	738 (92.3)
Homosexual	23 (2.9)
Bisexual	28 (3.5)
Pansexual	7 (0.8)
Other***	4 (0.5)
* Jamaica (5), Belize, Trinidad & Tobago (5), Poland, Turkey(2), Hungary (15), Germany (4), Vietnam, Italy (24), Canada(5), Brazil (5), Ecuador (14), Indonesia, Australia (2), United Kingdom (2), Barbados, France, Sweden, Armenia, Colombia, Spain, Singapore, Kuwait, China (3), Haiti **Trans (no interest in assignment) ***Straight, Normal, Queer, Hetero flexible	

Table 1: Demographic variables of survey respondents.

Overall, 81.5% (652/800) and 60.6% (485/800) of respondents selected Option B, barely visible labia minora protruding to the distal end of the labia major, as the most “normal” and most “attractive” female external genitalia, respectively. Moreover, 95.8% (767/800)

selected either A or B-non-visible or slightly visible labia-as the most “normal” variants, and 96.6% (773/800) selected either A or B for the most “attractive” variants of labia minora (Figure 2).

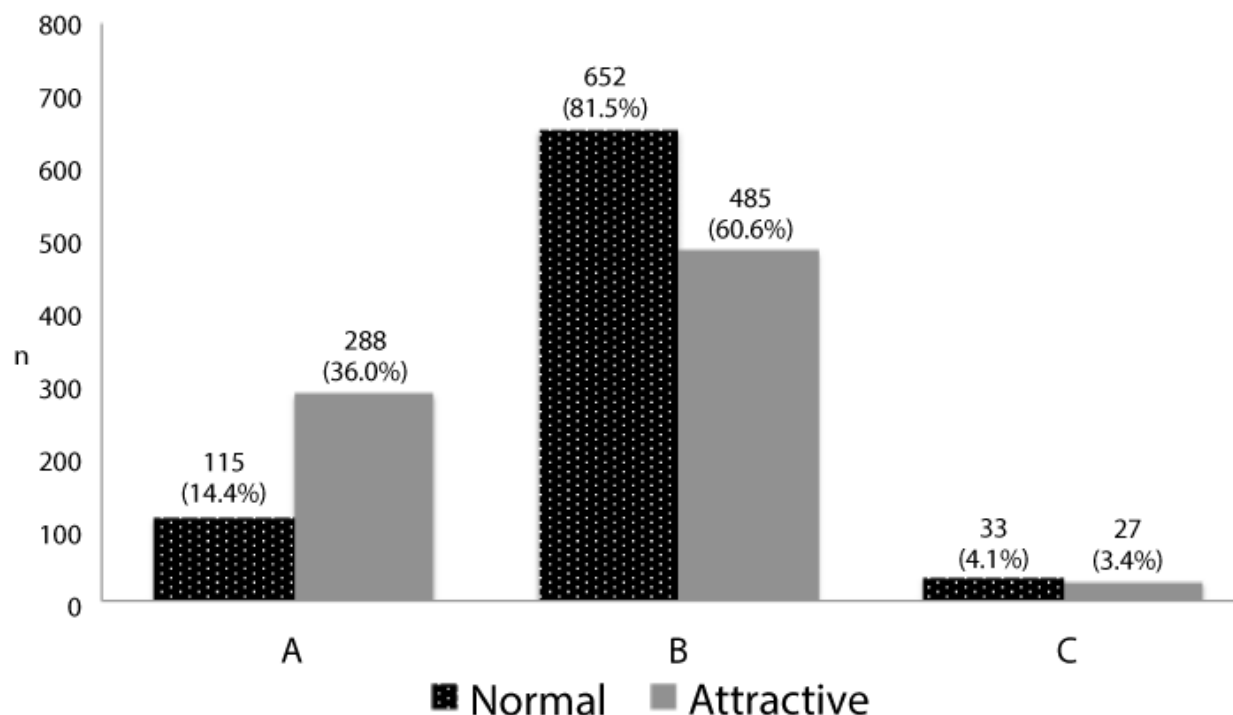


Figure 2: When dichotomized to a female and male group, female respondents selected answer choice C with the greatest protrusion of labia minora as most “normal” more frequently than male respondents, $X^2(2, 799) = 6.03, p < 0.05$. Overall, though, option C was chosen with the least frequency across both gender cohorts. Only 21 females and 12 males selected C as most normal; 12 females and 15 males, respectively, selected C as most attractive.

No statistical significance was found when comparing responses based upon age, sexual orientation, or country of origin (Table 2).

Variable	Answer Selection: Most Normal (%)			n	Pearson Chi Square Value, Degrees of Freedom	p-value	Answer Selection: Most Attractive (%)			n	Pearson Chi Square Value, Degrees of Freedom	p-value
	A	B	C				A	B	C			
Age (years)	88 (15.2)	467 (80.7)	24 (4.1)	579	1.17a, 2	0.56	205 (35.4)	353 (61.0)	21 (3.6)	579	0.64a, 2	0.73
>34	27 (12.2)	185 (83.7)	9 (4.1)	221			83 (37.6)	132(59.7)	6 (2.7)	221		
Country of origin												
	97 (13.8)	576 (82.2)	28 (4.)	701	1.68b, 2	0.43	253 (36.1)	423 (60.3)	25 (3.6)	701	0.7b, 2	0.70
	18 (18.2)	76 (76.8)	5 (5.0)	99			35 (35.4)	62 (62.6)	2 (2.0)	99		
Gender**												

	48 (14.0)	274 (79.9)	21 (6.1)	343	6.06a, 2	0.049	122 (35.6)	209 (60.9)	12 (3.5)	343	0.08a, 2	0.96
	67 (14.7)	377 (82.7)	12 (2.6)	456			166 (36.4)	275 (60.3)	15 (3.3)	456		
.												
Sexual Orientation											3.18b, 2	0.20
	108 (14.7) Other 62	601 (81.4)	29 (3.9)	738			271 (36.7)	441 (59.8)	26 (3.5)	738		
	7 (11.3)	51 (82.3)	4 (6.4)	62			17 (27.4)	44 (71.0)	1 (1.6)	62		
a 0 cells (0%) have expected count less than 5 b1 cell (16.7%) has expected count less than 5												

Table 2: Most Normal and Most Attractive appearing female external genitalia by demographic variable.

In total, 29% (230/800) of respondents left a free text response after choosing the most “normal” graphic, and 29% (234/800) wrote a free text response after the most attractive graphic. Fifty-two responses were excluded because they were determined by reviewing authors to be irrelevant or inapplicable to the posed questions. The remaining responses were categorized and compiled in Table 3 according to identified gender. Fourteen respondents stated that all three options

appeared “normal” [n=11 (6 male; 5 female)] or “attractive” [n=3 (3 male)]. These were not categorized. Appearance was the most commonly cited reason for which an image was selected as most “normal” or most “attractive”, across all gender identities. Responses were considered appearance related if they mentioned such key words as “size,” “shape,” or “symmetry” (Table 3).

Female Respondents									
	Reason n								
Answer Selection	Appearance	Function	Clean/Neat/Healthy	Age/Youth/Virginity	Culture/Media	Personal Experience	Represents Self	Common/Natural/Average	
Normal									Total*
A	5	0	0	3	0	1	2	3	14
B	20	0	0	2	4	12	12	18	68
C	1	0	0	0	0	1	1	1	4
Attractive									
A	22	1	0	1	1	0	0	0	25
B	26	6	0	3	1	1	2	23	62
C	3	0	0	0	0	0	0	0	3
Male Respondents									
	Reason n								
Answer Selection	Appearance	Function	Clean/Neat/Healthy	Age/Youth/Virginity	Culture/Media	Personal Experience	Represents Self	Common/Natural/Average	
Normal									Total*
A	2	3	2	2	0	2	0	1	12

B	31	3	3	7	1	20	0	21	86
C	2	0	0	1	0	2	0	2	7
Attractive									
A	16	8	12	6	1	3	0	1	47
B	23	9	7	10	0	4	0	11	64
C	4	2	0	0	0	0	0	0	6
*Totals reflect the responses that could be categorized. Providing reasoning for response was optional.									

Table 3: Free Responses Categorized by Reason for Answer Choice

Use of the words “Common,” “Natural,” and “Average,” as descriptors was found second most frequently. Other reasons popular among female respondents were self-representation and personal experience. The latter was also popular among male respondents, but they also more frequently commented on function, age, and cleanliness. Responses were categorized to “Function,” when they mentioned the genitalia in the context of sex. For example, some commented that option A perhaps had been engaged in less sexual activity than the other two options. The “Age/Youth/Virginity” category refers to responses suggesting that the image appeared to represent female genitalia of a certain age. Only male respondents referenced the apparent cleanliness, neatness, or healthiness of the genitalia in their comments. Several respondents, both male and female, suggested that their opinions were based on popular culture and media standards or pornography. Specific examples of responses in each category can be found in Table 4.

	Most Normal	Most Attractive
Response Categories	Examples (answer selection)	Examples (answer selection)
Appearance	“It’s the most symmetrical.” (A) “Discernable anatomy without excessive redundancy of tissue.” (B) “Doesn’t look too closed or too open. Can see the clit.” (B)	“I’m attracted to the delicate folds and gentle curves.” (C)
Function	“Medium tightness.” (B)	“It seems less sexually active.” (A)
Clean/Neat/Healthy	“Appears healthy.” (A)	“I think the fewer folds, the less messy it gets with menstruation.” (A)
Age/Youth/Virginity	“It appears mature and organic.” (C)	“Looks like a virgin.” (A)
Culture/Media	“Probably because I was brainwashed by pornography.” (B)	“Probably because it’s the one that I’ve seen the most in the media.” (A)
Personal Experience	“What I’ve grown up seeing (i.e. female family members,	“Looks like my significant other’s.” (B)

	myself, female partners).” (B)	
Represents Self	“Because it’s the one I have.” (A)	“Because that’s what mine look like.” (B)
Common/Natural/Average	“Average length I suppose.” (B)	“Looks like a natural woman’s.” (B)

Table 4: Examples of responses to open-ended questions by category.

Discussion

The response distribution in other regions of the world, including non-Westernized countries, was no different than the USA, which may suggest that the depiction of female genitalia made popular in Western cultures exists in other countries. Surely, a larger sample size of international respondents, particularly from non-western countries, is necessary to draw conclusions in this regard. Other cultures have historically embraced wider labia minora, particularly in Japan where the “winged butterfly” appearance of the labia minora is admired and various African societies that include labial stretching among their traditions [9,28,29].

Of the participants who provided an explanation of their choice, the majority of respondents, both male and female, commented on overall appearance, such as shape or symmetry. Heterosexual male respondents were more likely to consider factors that sexualized the genitalia. While many respondents related their conceptions of normality and attractiveness to personal experience, others simply alluded to the images depicting what they considered to be the most common, natural, or average version of genitalia. This is alarming because all three images are normal variations, and respondents most associated these characteristic with the two more extreme images of nonvisible or barely visible genitalia. If not from personal experience, it raises the question of how they formed these opinions. While only a few directly addressed the impact of media or pornography, it is quite possible that the many respondents who alluded to a most common, natural, or average-appearing vulva developed their opinions from this source.

Only fourteen respondents, primarily men, actually noted that all three images appeared “normal” or “attractive”, suggesting an awareness of the natural variation of labia. Still, the variety of opinions regarding vulvar appearance suggests that a range of factors motivate persons to make judgments regarding normality and attractiveness.

These reasons should be elicited from a patient when in consultation for labiaplasty.

Undoubtedly the decision to operate on a patient should only come after careful conversation and consideration of the patient's physical and mental health, including an assessment for body dysmorphic disorder. It is imperative for physicians to appropriately counsel patients who desire elective surgery, including FGCS. Risks, benefits and realistic expectations of the procedure should be discussed, and the surgeon should abide by the guiding bioethical principles of medicine-1) patient autonomy, 2) non-maleficence, 3) beneficence, and 4) justice-to ensure that surgery is performed on the appropriate candidate [9].

Discussion of normal physiologic variants of genitalia is also an important component of pre-operative counseling. If societal norms inappropriately impact aesthetic expectations for female genitalia, the resulting disconnect between popular beliefs and physiologic norms could potentiate unrealistic patient outcomes, patient dissatisfaction, and surgery that is physiologically unnecessary and possibly dangerous. For example, patients may request complete amputation or over-reduction of the labia minora, but these should not be performed due to the physiologic importance of the labia minora [4,5]. If this does occur, treatment of these deformities and resulting sequelae is difficult [30]. A conversation about the wide range of normal genitalia with a patient may alleviate her concern about the appearance of her own vulva [12]. Our data suggest that genitalia with barely visible labia, as opposed to the extreme of nonvisible labia, are actually considered the most "normal" and "attractive", and a presentation of these results to patients could possibly alleviate their concerns or guide them toward a less extreme reduction procedure. It may also be prudent for the surgeon to dissuade a patient from surgical intervention if, in accordance with professional guidelines and policy statements, the surgeon has performed screening tests to determine an underlying cause of a patient's dissatisfaction that may be more appropriately treated. Patients may benefit from resources such as The Labia Library that illustrate the great variation of female genitalia.

It is important to note that our study is not without limitations. Because we used an Internet-based survey, we could not prevent multiple completion attempts or determine a response rate. However, this distribution method allowed us to achieve a larger, more diverse sample size. Most studies that have addressed preferences for female genitalia appearance have studied just women, often only those who obtain surgical consultations for labiaplasty, and our method afforded us a vaster sample population [17,22,31,32].

The use of graphically designed images rather than photographs may have impacted some respondents' interpretations of answer choices and affected their responses. Depicting the anatomy from the lithotomy position may have also influenced results because women typically view their labia from the standing position [33]. However, our survey was not solely intended for women, and the lithotomy position was felt to better convey the difference in vulvar anatomy across answer choices to all those completing the survey.

We used a convenience sample of contacts that likely was not a representative sample of the population at large, given the similarity of the study authors' personal networks. Likewise, this survey did not take into the account the opinions of persons without Internet access. These factors likely limited external validity. We also ordered our answer selections in ascending size. This lack of randomization may have prompted some respondents to select choice "B," simply because it was

in the middle of two extremes, which might have introduced response bias. Furthermore, we used a forced-choice response format. Arguably, a Likert-type scale may have been more appropriate to assess subjective perceptions of normality and attractiveness. Instead, we included open-ended text boxes to gain increased insight into respondents' choices.

The limitations of our survey restrict the strength of our conclusions, particularly with regard to generalizability, but they also highlight important future directions. The results of our study, particularly the qualitative data, are not only interesting but also provide useful insight into opinions of female genitalia and lend themselves to a productive conversation between a physician and patient considering labiaplasty.

Conclusion

As the media and pornography continue to portray female genitalia as homogenously void of visible labia minora and censor other anatomical variations, people will likely continue to consider this the most normal and attractive, which our results have shown. As long as this remains the popular standard, it is likely women will continue seeking labiaplasty. This study underscores the need for physicians to engage in thorough counseling with patients who present for labiaplasty, including an assessment of their reasons for dissatisfaction with their genitalia and a discussion of normal physiologic variants. Our results do allow us to be cautiously optimistic, however, because the most extreme variant of genitalia-those with completely nonvisible labia minora-were not selected as the most normal or attractive depiction. This result may be useful in discouraging patients who seek extreme reduction or complete amputation of their labia minora. Still, with the vast majority of respondents selecting barely visible or nonvisible images of labia minora as most normal and attractive, the need for widespread education about the normal physiologic variation of female genitalia and more depictions of this variation in media outlets is quite evident.

References

1. Takacs P, Yavagal S, Medina CA (2014) Normal Vulvovaginal and Perineal Female Anatomy. *Aesthetic and Functional Surgery of the Genitalia*. *Semin Plast Surg* 25: 121-129.
2. Martin-Alguacil N, Schober J, Kow LM, Pfaff D (2006) Arousing properties of the vulvar epithelium. *J Urol* 176: 456-62.
3. Puppo V (2011) Embryology and anatomy of the vulva: the female orgasm and women's sexual health. *Eur J Obstet Gynecol Reprod Biol* 154: 3-8.
4. Schober J, Cooney T, Pfaff D, Mayoglou L, Martin-Alguacil N, et al. (2010) Innervation of the labia minora of prepubertal girls. *J Ped Adolesc Gyn* 23: 352-357.
5. Tan BK, Kang GC, Tay EH, Por YC (2014) Subunit principle of vulvar reconstruction: algorithm and outcomes. *Arch Plast Surg* 41: 280-286.
6. Crouch NS, Deans R, Michala L, Liao LM, Creighton SM, et al. (2011) Clinical Characteristics of Well Women Seeking Labial Reduction Surgery: a Prospective Study. *Br J Obstet Gynecol* 118: 1507-1510.
7. Lloyd J, Crouch NS, Minto CL, Liao LM, Creighton SM (2005) Female genital appearance: "Normality" unfolds. *Br J Obstet Gynecol* 112: 643-646.
8. Paarlberg KM, Weijnenborg PT (2008) Request for operative reduction of the labia minora: A proposal for a practical guideline for gynecologists. *J Psychosomatic Obstet Gynecol* 29: 230-234.
9. Dobbela JMLCL, Van Landuyt K, Monstrey SJ (2011) Aesthetic surgery of the female genitalia. *Semin Plastic Surg* 25: 130-141.

10. Barrett MM, Carlson JA (2014) A Clinicopathologic Study of Labia Minora Hypertrophy: Signs of Localized Lymphedema 18: 13-20
11. Liao LM, Creighton SM (2007) Requests for cosmetic genitoplasty: How should healthcare providers respond? *BMJ* 334: 1090-1092.
12. ACOG Committee Opinion No. 378: Vaginal rejuvenation and cosmetic vaginal procedures (2007) *Obstet Gynecol* 110: 737-738.
13. Reitsma W, Mourits MJE, Koning M, Pascal A, van der Lei B, et al. (2011) No (Wo)man is an island-the influence of physicians' personal predisposition to labia minora appearance on their clinical decision making: a cross-sectional survey. *J Sexual Med* 8: 2377-2385.
14. Cosmetic Surgery National Data Bank: Statistics 2013 (2014) *Aesthet Surg J* 34: 1S-22S.
15. Hospital Episode Statistics (2009) Number of Labial Reductions.
16. Bourke E (2009) Designer vagina craze worries doctors.
17. Goodman MP (2011) Female genital cosmetic and plastic surgery: a review. *J Sex Med* 8: 1813-1825.
18. Goodman MP, Placik OJ, Benson III RH, Miklos JR, Moore RD, et al. (2010) A Large Multicenter Outcome Study of Female Genital Plastic Surgery. *J Sex Med* 7: 1565-1577.
19. Veale D, Eshkevari E, Ellison N, Costa A, Robinson D, et al. (2014) Psychological Characteristics and Motivation of Women Seeking Labiaplasty. *Psychol Med* 44: 555-566.
20. Miklos JR, Moore RD (2008) Labiaplasty of the labia minora: patients' indications for pursuing surgery. *J Sex Med* 5: 1492-1495.
21. Braun V (2005) In Search of (Better) Sexual Pleasure: Female Genital 'Cosmetic' Surgery. *Sexualities* 8: 4.
22. Koning M, Zeijlmans IA, Bouman TK, van der Lei B. (2009). Female attitudes regarding labia minora appearance and reduction with consideration of media influence. *Aesthet Surg J* 29: 65-71.
23. McDougall LJ (2013) Towards a clean slit: how medicine and notions of normality are shaping female genital aesthetics. *Culture Health Sexuality* 7: 774-787.
24. Placik OJ, Arkins JP (2014) Plastic surgery trends Playboy magazine: the pudenda preoccupation. *Aesthet Surg J* 34: 1083-1090.
25. Michala L, Koliantzaki S, Antsaklis A (2011) Protruding labia minora: abnormal or just uncool? *J Psychosom Obstet Gynaecol* 32: 154-156.
26. Bramwell R, Morland C, Garden AS (2007) Expectations and experience of labial reduction: a qualitative study. *BJOG* 114: 1493-9.
27. Moran C, Lee C (2013) What's normal? Influencing women's perceptions of normal genitalia: an experiment involving exposure to modified and nonmodified images.
28. Scholten E (2009) Female genital cosmetic surgery-the future. *J Plast Reconstr Aesthet Surg*, 62: 290-291.
29. Perez GM, Namulondo H (2011) Elongation of labia minora in Uganda: including Baganda men in a risk reduction education programme. *Culture Health Sexuality* 13: 45-57.
30. Hamori CA, Salgado CJ, Dalke KA (2014) Female Aesthetic Genital Surgery. *Aesthetic and Functional Surgery of the Genitalia*. Nova Science Publishers: New York, NY.
31. Rouzier R, Louis-Sylvestre C, Paniel BJ, Haddad B (2000) Hypertrophy of labia minora: Experience with 163 reductions. *Am J Obstet Gynecol* 182: 35-40.
32. Munhoz AM, Filassi JR, Ricci MD, Aldrighi C, Correia LD, et al (2006) Aesthetic labia minora reduction with inferior wedge resection and superior pedicle flap reconstruction. *Plast Reconstr Surg* 118: 1237-1247.
33. Cihantimur B, Herold C (2013) Genital Beautification: A Concept That Offers More Than Reduction of the Labia Minora. *Aesthet Plast Surg* 37: 1128-1133.