

Prolonged QT Intervals in Isolated ACTH Deficiency: Case Report and Mini Review of Literature

Rikako Suzuki, Takeshi Hayashi^{*}, Hiroshi Asano, Kennosuke Ohashi, Masaya Sakamoto, Katsuyoshi Tojo and Kazunori Utsunomiya

Department of Diabetes, Metabolism and Endocrinology, The Jikei University School of Medicine, Tokyo, Japan

***Corresponding author:** Takeshi Hayashi, Department of Diabetes, Metabolism and Endocrinology, The Jikei University School of Medicine, Tokyo, Japan, Tel: +81-3-3433-1111; Fax: +81-3-3578-9753; E-mail: takeshihayashi@jikei.ac.jp

Equal Contributor: Hiroshi Asano, Department of Diabetes, Metabolism and Endocrinology, The Jikei University School of Medicine, Tokyo, Japan

Received date: May 23, 2016; **Accepted date:** June 20, 2016; **Published date:** June 25, 2016

Copyright: © 2016 Suzuki R, et al. This is an open-access article distributed under the terms of the Creative Commons Attribution License, which permits unrestricted use, distribution, and reproduction in any medium, provided the original author and source are credited.

Abstract

Isolated adrenocorticotrophic hormone (ACTH) deficiency is a rare disorder, characterized by secondary adrenal insufficiency. We experienced a case of isolated ACTH deficiency presented with prolonged QT intervals which was helpful in diagnosis. Hereby we report our case and review the previous cases. We describe a 77 year-old female whose major complaints were general malaise, anorexia, and depression. On admission, QT intervals of ECG were prolonged. Endocrine tests indicated that she was suffering from isolated ACTH deficiency. After hydrocortisone replacement therapy was started, QT intervals were shortened and all of her complaints were resolved. There are only six reports about isolated ACTH deficiency associated with prolonged QT intervals until now. Prolongation of QT intervals is known to be a risk factor for cardiovascular events such as ventricular fibrillation, but interestingly prolonged QT intervals associated with isolated ACTH deficiency infrequently cause lethal arrhythmia. The initial symptoms of adrenal deficiency in elderly patients are obscure and adrenal deficiency is often misdiagnosed as unidentified clinical syndrome. It is important to consider isolated ACTH deficiency when recognizing unexplained prolonged QT intervals.

Keywords: Isolated ACTH deficiency; QT prolongation; Hydrocortisone

Introduction

Isolated adrenocorticotrophic hormone deficiency (IAD) is a rare disorder, characterized by secondary adrenal insufficiency with low or absent cortisol production, normal secretion of pituitary hormones except ACTH and the absence of structural pituitary defects [1]. The clinical features include various symptoms such as vomiting, abdominal pain, myalgia, joint pain, severe hypotension, and hypovolemic shock due to glucocorticoid deficiency. Glucocorticoid replacement is required for the symptomatic patients. Since the reports in the 1950s, ECG abnormalities such as flat or inverted T waves, prolonged QT intervals are known to occur in adrenal insufficiency [2-4]. There are six reports suggesting that sudden cardiac arrest occurs in IAD due to prolonged QT intervals [5-10]. Although ECG abnormalities are modulated after hydrocortisone replacement, the mechanism by which hydrocortisone may affect ECG still remains unclear. Here we report a case of IAD whose ECG abnormalities were reversed with hydrocortisone replacement, suggesting a role played by glucocorticoids in the modulation of QT intervals. Also we show the characteristics of the six cases of IAD with QT prolonged intervals causing lethal arrhythmia.

Case Presentation

A 77 year-old female patient was admitted to our hospital with major complaints of general malaise, appetite loss, depression and weight loss (7 kg over one month). First she visited the psychiatrist, and hyponatremia (130 mmol/l) was detected by blood test. The psychiatrist prescribed olanzapine for her depression for 2 weeks and

indicated more salt intake to correct hyponatremia, which did not improve her complaints. Endocrinological examination revealed low serum ACTH, low cortisol and elevated anti-diuretic hormone.

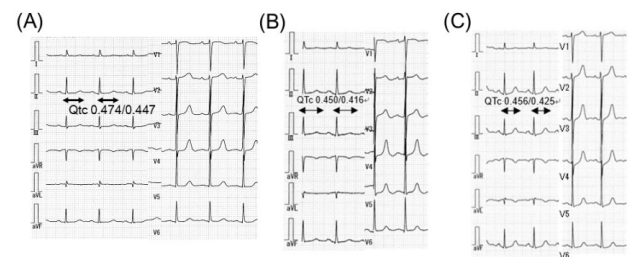


Figure 1: ECG on referral (before hydrocortisone replacement) demonstrated negative flat T waves and prolonged QTc intervals (0.474 sec) in all leads. (B) ECG three days after hydrocortisone replacement therapy showed flat T waves and prolonged QTc intervals of ECG were normalized (0.45/0.416 sec). (C) ECG three months after hydrocortisone replacement therapy kept flat T waves and normal QTc intervals (0.456/0.425 sec).

She was suspected to have secondary adrenal insufficiency, and referred to our hospital. She was disoriented and the level of consciousness was mildly depressed. Her height was 151.5 cm, body weight 37.1 kg, body mass index 16.2 kg/m², blood pressure 96/60 mmHg, heart rate 84 beats per minute and regular. On physical examination, her palpebral conjunctiva was pale. Her skin and her tongue were not pigmented. No neurological defect was observed.

ECG demonstrated negative flat T waves and prolonged QTc intervals (0.474 sec) in all leads (Figure 1).

Laboratory tests were as follows; normocytic normochromic anemia (hemoglobin 9.5 g/dl, hematocrit 27.8%) and white blood cell count of 4800/ μ l. The serum level of sodium was low, while potassium was normal. Other routine chemistries and urinalysis data were all within normal range. Endocrinological examination revealed very low serum concentrations of ACTH and cortisol. Thyroid-stimulating hormone was elevated although free T3 and free T4 were within normal range (Figure 2). Thyrotropin-releasing hormone test, growth hormone-releasing test and luteinizing hormone-releasing hormone test

demonstrated the normal response of each hormone. However, neither ACTH nor cortisol responded to the stimulation with corticotropin-releasing hormone. The rapid ACTH injection test showed a slight increase in serum cortisol (Figure 2). Magnetic resonance imaging revealed no organic lesions or atrophy of pituitary gland. These data indicated that she was suffering from isolated ACTH deficiency. On the basis of this diagnosis, hydrocortisone replacement was started. After hydrocortisone replacement was started, all of her complaints were improved and flat T waves and prolonged QTc intervals of ECG were normalized (0.45/0.416 sec) as shown in Figure 1.




Figure 2: (A) Laboratory Data. Parenthesis denotes normal range. (WBC: White Blood Cell, RBC: Red Blood Cell, Hb: Hemoglobin, Ht: Hematocrit, Plt: Platelet, AST: Aspartate Aminotransferase, ALT: Alanine Aminotransferase, LDH: Lactase Dehydrogenase, ChE: Cholinesterase, T-Bil: Total Bilirubin, ALP: Alkaline Phosphatase, γ -GTP: γ -Glutamyl Transpeptidase, TP: Total Protein, Alb: Albumin, UN: Urea Nitrogen, Cr: Creatinine, Na: Sodium, K: Potassium, Cl: Chloride, Ca: Calcium, Fe: Iron, UIBC: Unsaturated Iron Binding Capacity, TIBC: Total Iron Binding Capacity, CRP: C-reactive Protein, U-Cr: Urinary Creatinine, U-Na: Urinary Sodium, U-K: Urinary Potassium, U-Cl: Urinary Chloride.) (B) Endocrinological data. Parenthesis denotes normal range. (GH: Growth Hormone, IGF-I: Insulin-like Growth Factor I, LH: Luteinizing Hormone, FSH: Follicle Stimulation Hormone, PRL: Prolactin, ADH: Antidiuretic Hormone, E2: Estradiol, ACTH: Adrenocorticotropic Hormone, PAC: Plasma Aldosterone Concentration, PRA: Plasma Renin Activity, TSH: Thyroid-stimulating Hormone, FT3: Free Triiodothyronine, FT4: Free Thyroxine, Tg: Thyroglobulin, TPO: Thyroid Peroxidase, TRAb: Thyroid-stimulating Hormone Receptor Antibody.) (C) Thyrotropin-releasing hormone test, growth hormone-releasing test, luteinizing hormone-releasing hormone test, and corticotropin-releasing hormone test demonstrated normal response of each hormone. Neither ACTH nor cortisol responded to the stimulation with corticotropin-releasing hormone. (D) The rapid ACTH injection test showed significant increase in serum cortisol, suggesting that secretion of cortisol depended on ACTH.

Discussion

Since the 1950s, various ECG abnormalities have been reported to occur in adrenal insufficiency [3] and in hypopituitarism [4]. ECG abnormalities include flat or inverted T waves, prolonged QT intervals, low voltage, prolonged PR or QRS intervals, and depressed ST segment. In some cases, these ECG changes cause lethal arrhythmia (Table 1) [5-10]. Mean QTc intervals is 0.55 seconds. Mean age of these patients is 55.8 years old. The male to female ratio is 2:4 in IAD patients with prolonged QT intervals, although the male to female is

1.2 - 3.6:1 in IAD, with the disease being slightly more common in men [11]. Mean age of female patients is younger than that of male patients (48.25 years old versus 71.5 years old). It is known that estrogens prolong QTc intervals in animal experiments, which might explain why young female patients are more common in isolated ACTH deficiency with prolonged QT intervals [12]. The serum sodium level was normal in four out of six patients (66.7%). QTc intervals were shortened in all of the six cases after hydrocortisone replacement therapy was started.

| | Authors | Age, sex | C.C. | Na (mEq/l) | K (mEq/l) | Mg (mEq/l) | ACTH (pg/ml) | Cortisol (mg/dl) | ECG (QTc intervals) |
|---|----------------------|----------|------|------------|-----------|------------|--------------|------------------|---|
| 1 | Nishizawa et al. [5] | 72, M | LOC | 136 | 3.7 | 2.1 | 5 | 1 | QT prolongation, Vf |
| 2 | Takeda et al. [6] | 35, F | LOC | 138 | 3.2 | 2.4 | <5.0 | 1.4 | QT prolongation (0.64), Vf |
| 3 | Gotyo et al. [7] | 70, M | CPA | 139 | 3.9 | - | <5.0 | 0.8 | QT prolongation, torsade de pointes, Vf |
| 4 | Nakano et al. [8] | 38, F | LOC | 132 | - | - | <5.0 | 2.2 | QT prolongation (0.474), torsade de pointes |
| 5 | Murakami et al. [9] | 62, F | LOC | 124 | 3.7 | 1.8 | <5.0 | 0.9 | QT prolongation (0.582), CPA |
| 6 | Kakizawa et al. [10] | 58, F | LOC | 125.2 | 4.9 | 1.8 | <2.0 | <1.0 | QT prolongation (0.489), Vf |

Table 1: Cases with prolonged QT intervals due to isolated ACTH deficiency.

Although the pathogenesis of these ECG abnormalities in glucocorticoid insufficiency still remains uncertain, a couple of speculations have been offered. It could be considered that changes in distribution of electrolytes within intravascular and extravascular compartments due to glucocorticoid deficiency may result in abnormal potentials of ECG [13]. However, in some cases including this case, the replacement of electrolyte did not correct abnormalities in the ECG [6,10]. This fact evokes the hypothesis that glucocorticoid may directly affect action potential of myocardial membrane. Busjahn and coworkers have demonstrated that serum glucocorticoid regulated kinase (sgk1) in the heart up-regulates the activity of the slowly activating K⁺ channel KCNE1/KCNQ1. It is also reported that defective KCNE1 and/or KCNQ1 lead to long QT syndrome [14]. Suppressed activity of sgk1 downregulates KCNE1/KCNQ1 in glucocorticoid insufficiency and thus could lead to prolongation of QT intervals (Figure 3).

Oakley and coworkers recently demonstrated that deficiency of glucocorticoid signaling in cardiomyocytes participates in spontaneous cardiac hypertrophy, heart failure, and death, indicating an obligate role played by glucocorticoid receptor (GR) in maintaining normal cardiovascular function. In the GR deficient hearts, the expression of ryanodine receptor 2 (RyR2) is reportedly suppressed in the cardiomyocytes of GR deficiency. RyR2 is involved in abnormal calcium handling in cardiac hypertrophy and heart failure [15]. To facilitate coordinated Ca-induced Ca release, groups of RyR2 are localized in discrete areas in the sarcoplasmic reticulum (SR) membrane directly adjacent to L-type Ca channels within the T-tubules of the sarcolemma [16]. RyR2 loss-of-function can lead to fatal arrhythmia as well as RyR2 gain-of-function [17]. Suppression of RyR2 would be an alternative mechanism by which fatal arrhythmias occur in the patients with adrenal insufficiency. Hence, it could be considered that glucocorticoid replacement might shorten QT intervals by stimulating the slowly activating K⁺ channel KCNE1/KCNQ1, and prevent lethal arrhythmia by enhancing the expression of RyR2 (Figure 3). In this case report, we could not examine these speculations which should be investigated using *in vivo* and *in vitro* settings of glucocorticoid deficiency.

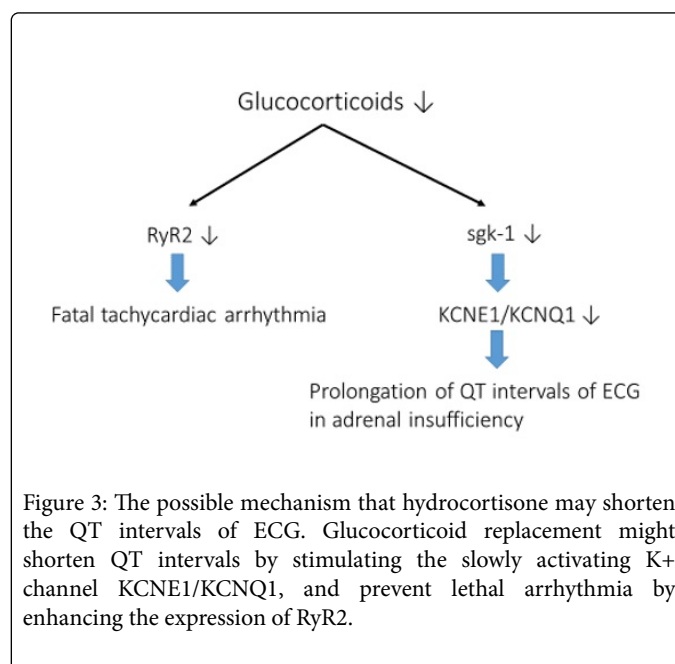


Figure 3: The possible mechanism that hydrocortisone may shorten the QT intervals of ECG. Glucocorticoid replacement might shorten QT intervals by stimulating the slowly activating K⁺ channel KCNE1/KCNQ1, and prevent lethal arrhythmia by enhancing the expression of RyR2.

Conclusion

Long QT syndrome is one of the symptoms of isolated ACTH deficiency. Long QT syndrome is known to be a risk factor for cardiovascular events, and prolonged QTs can be reversed by glucocorticoid replacement. We point out the possible mechanism whereby hydrocortisone may contribute to QT intervals.

References

1. Andrioli M, Pecori Giraldi F, Cavagnini F (2006) Isolated corticotrophin deficiency. *Pituitary* 9: 289-295.
2. Somerville W (1950) The effect of cortisone on the cardiogram in chronic adrenal insufficiency. *Br Med J* 2: 860-862.
3. Somerville W, Levine HD, Thorn GW (1951) The electrocardiogram in Addison's disease. *Medicine* 30: 43-79.

4. Sheehan HL, Summers VK (1949) The syndrome of hypopituitarism. *Q J Med* 18 : 319-378.
5. Nishizawa S, Nakamura T, Hamaoka T, Matsumuro A, Sawada T, et al (2009) Lethal arrhythmia and corticosteroid insufficiency. *Am J Emerg Med* 27: 1167 e1161-1163.
6. Takeda H, Endo N, Kobayashi J, Niitsuma T, Miura E, et al (2002) Ventricular fibrillation and long QT interval in a case with secondary adrenal insufficiency. *Shinzo* 34: 148-153.
7. Gotyo N, Kida M, Horiuchi T, Hirata Y (2009) Torsade de pointes associated with recurrent ampulla cardiomyopathy in a patient with idiopathic ACTH deficiency. *Endocr J* 56: 807-815.
8. Nakano T, Sato R, Watanabe T, Azegami K, Okishige K, et al (2007) Isolated ACTH Deficiency Presenting with QT prolongation and Ventricular Fibrillation. *Folia Endocrinol Japoni (Jpn)* 82: 949.
9. Murakami M, Katabami T, Kato H, Asai S, Nishine A, et al (2011) A Case of Isolated ACTH Deficiency Presenting with Ventricular Fibrillation. *Folia Endocrinologica Japonica (Jpn)* 87: 25-27
10. Kakizawa K, Okawa Y, Nagayama K, Oki Y, Nakamura H, et al (2012) A Case of Isolated ACTH Deficiency Presenting with Ventricular Fibrillation due to prolonged QT intervals. *Folia Endocrinologica Japonica (Jpn)* 88: 15-17.
11. Goto Y, Tatsuzawa K, Aita K, Furuno Y, Kawabe T, et al (2016) Neurological symptoms in a patient with isolated adrenocorticotropin deficiency: case report and literature review. *BMC Endocrine Disorders* 16: 2.
12. Drici MD, Burklow TR, Haridasse V, Glazer RI, Woosley RL (1996) Sex hormones prolong the QT interval and downregulate potassium channel expression in the rabbit heart. *Circulation* 94: 1471-1474.
13. Wilson GM, Miller H (1953) Exchangeable sodium in Addison's disease in relation to the electrocardiogram and the action of cortisone. *Clin Sci (Lond)* 12: 113-129.
14. Busjahn A, Seebohm G, Maier G, Toliat MR, Nurnberg P et al (2004) Association of the serum and glucocorticoid regulated kinase (sgk1) gene with QT interval. *Cell Physiol Biochem* 14: 135-142.
15. Oakley RH, Ren R, Cruz-Topete D, Bird GS, Myers PH et al (2013) Essential role of stress hormone signaling in cardiomyocytes for the prevention of heart disease. *Proc Natl Acad Sci U S A* 110: 17035-17040.
16. Broun MJ, Asghari P, Wambolt RB, Bohunek L, Smits C, et al (2012) Cardiac ryanodine receptors control heart rate and rhythmicity in adult mice. *Cardiovasc Res* 96: 372-380.
17. Wehrens XH, Marks AR (2003) Altered function and regulation of cardiac ryanodine receptors in cardiac disease. *Trends Biochem Sci* 28: 671-678.