

Rupture of Hypogastric Artery Aneurysm Following Failed Endovascular Repair: A Case Report

Marika Gassner* and Sachinder S. Hans

Division of Vascular Surgery, Henry Ford Macomb Hospital, Clinton Township, Michigan, USA

Abstract

Hypogastric artery aneurysms are usually associated with aortic and common iliac aneurysm and rarely occur in isolation [1-6]. The majority of hypogastric artery aneurysms are incidentally detected on imaging of the abdomen or pelvis for unrelated complaints. Those that present in extremis are associated with acute rupture and carry a high mortality rate. [1,2] Herein we present a case of an incidentally found isolated right hypogastric artery aneurysm treated initially with endovascular repair. The aneurysm subsequently ruptured and was treated successfully with open repair.

Keywords: Hypogastric; Artery; Aneurysm**Introduction**

Hypogastric artery aneurysms are usually associated with aortic and common iliac aneurysm and rarely occur in isolation [1-6]. The majority of hypogastric artery aneurysms are incidentally detected on imaging of the abdomen or pelvis for unrelated complaints. Those that present in extremis are associated with acute rupture and carry a high mortality rate [1,2]. Herein we present a case of an incidentally found isolated right hypogastric artery aneurysm treated initially with endovascular repair. The aneurysm subsequently ruptured and was treated successfully with open repair.

Case Report

A 90 year old male presented to his primary care physician with complaints of left lower quadrant pain and bulging mass. On physical examination patient was found to have a palpable mass in the left lower quadrant of the abdomen. A computerized tomographic scan (CT scan) of the abdomen demonstrated a left spigelian hernia. A large incidental right internal iliac artery aneurysm measuring 4.4x5.5 cm in cross section and extending approximately 5.3 cm in cranio-caudal length was also detected. Moderate thrombus was noted in aneurysmal wall (Figure 1).

There was no accompanying aortic aneurysm noted on CT scan. The patient then underwent a retrograde aortography via retrograde femoral approach. The previously identified right hypogastric aneurysm was again noted, along with a small right common iliac artery aneurysm. Two tornado coils 14x8 mm followed by 14x6 mm were deployed into the outflow tracts of the aneurysm. We were unable to completely occlude the outflow vessels. However, near complete occlusion was obtained and we believed that thrombosis following inflow occlusion would result in satisfactory outcome. An Amplatzer vascular plug 16mmx12mm was deployed at the mouth of the aneurysm (Figure 2). Post deployment images demonstrated adequate exclusion of the aneurysm.

The patient presented to the emergency department five weeks later with acute onset abdominal pain and urinary retention. The patient was on warfarin treatment for atrial fibrillation and on admission had an International Normalized Ratio (INR) of 5.4. A CT angiogram scan of the abdomen was obtained demonstrating recurrence of the previously treated hypogastric aneurysm (now 7.2 cm x7.2 cm) with evidence of contrast extravasation (Figure 3).

The patient received 5 units of fresh frozen plasma and was taken emergently to the operating room. He underwent an exploratory laparotomy with isolation and ligation of the ruptured right hypogastric

artery aneurysm. The amplatzer plug was found lying freely in the aneurysmal sac. At that time the outflow tract vessels were also ligated. The left spigelian hernia was also repaired prior to closure. Intraoperatively we encountered significant venous bleeding and the patient had a 1500cc blood loss. He received 5 units of packed red blood cells during the procedure. Post operatively the patient was admitted to the intensive care unit where his recovery was complicated by an acute DVT of the left lower extremity, aspiration pneumonia and prolonged ileus with malnutrition requiring short term total parenteral nutrition. Following discharge the patient was sent to a rehab facility and home 3 weeks later. He was seen in re-evaluation six months post operatively and a repeat CT scan demonstrated a stable hematoma post ligation without evidence of extravasation with a therapeutic INR.

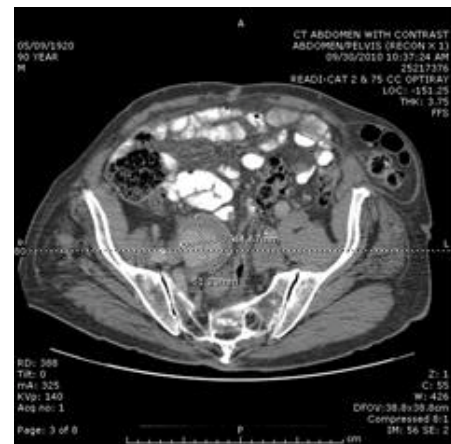

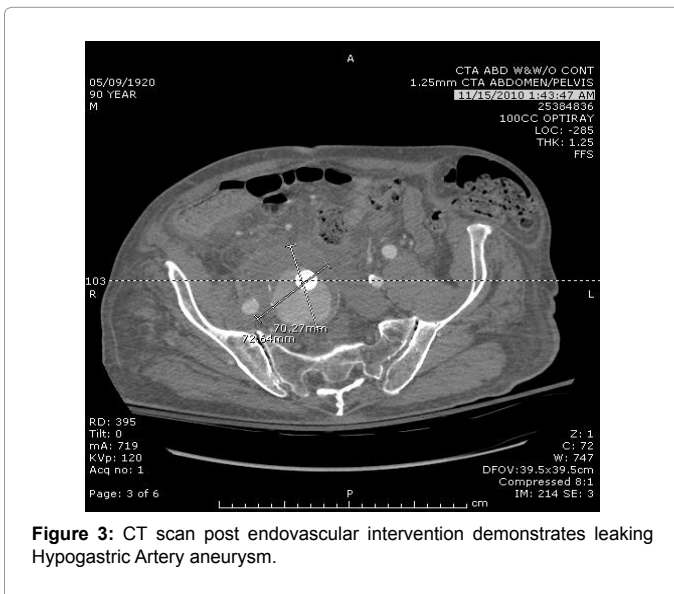
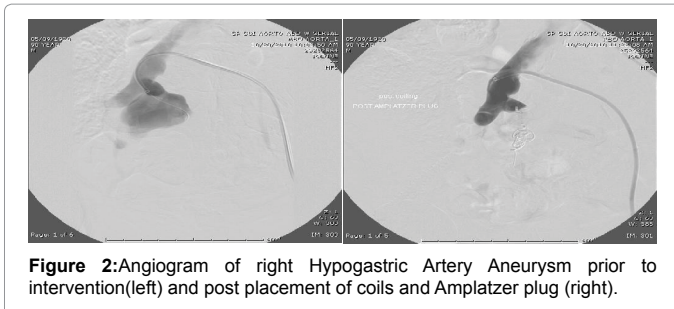
Figure 1: CT scan demonstrating right Hypogastric Artery Aneurysm and left Spigelian Hernia.

*Corresponding author: Gassner M, Division of Vascular Surgery, Henry Ford Macomb Hospital, Clinton Township, Michigan, USA, Tel: 5039367375; E-mail: Gassnermy@gmail.com

Received June 20, 2015; Accepted August 11, 2015; Published August 18, 2015

Citation: Gassner M, Hans SS (2015) Rupture of Hypogastric Artery Aneurysm Following Failed Endovascular Repair: A Case Report. *Surgery Curr Res* 5: 243. doi:10.4172/2161-1076.1000243

Copyright: © 2015 Gassner M, et al. This is an open-access article distributed under the terms of the Creative Commons Attribution License, which permits unrestricted use, distribution, and reproduction in any medium, provided the original author and source are credited.



Discussion

Isolated hypogastric aneurysms are rare, with an incidence rate of 0.4% of all aorto-iliac aneurysms. The incidence of rupture is as high as (33%) [2]. Rupture of the hypogastric aneurysm is often reported as the initial presentation, and therefore carries a high mortality rate of up to 58% [1,3]. The average size of hypogastric aneurysms found incidentally is 4-5cm. The average size of rupture of hypogastric aneurysms is 6.0 cm. Repair is recommend in any hypogastric aneurysm larger than 3 cm in anterior-posterior/ transverse diameter [1,4].

Patients may present with symptoms caused by compression of pelvic structures and can include genitourinary tract obstruction, thrombosis of the iliac vein, or lumbosacral nerve root compression.

Various treatment techniques are reported in the literature, with none clearly superior to the others, this is likely due to the small number of reported cases. Endovascular repairs are becoming a more common treatment option, even in the emergent setting, with improved technical skills and equipment becoming more readily available. When performed electively, this approach carries a less than 1% mortality rate. In the emergent setting endovascular repair has been associated with a 50% incidence of subsequent rupture with a 7% incidence of Type I endoleak [7-10]. In our patient failure of endovascular exclusion was due to the short aneurysmal neck. The angulated neck and large size precluded us from embolizing all of the outflow tracts. The most

common complication following endovascular repair is a reported 30-40% incidence of buttock claudication due to complete occlusion of the hypogastric artery, and in many cases all collateral outflow tracts [5]. An additional technical consideration for our case would have been placement of a covered stent into the external iliac thereby further occluding the inflow to the hypogastric artery. Given the technical challenge and orientation of the aneurysmal neck in this case this alternative may have decreased the risk of subsequent rupture. In this case rupture of the aneurysm post endovascular intervention was primarily due to blood flow from the outflow tract vessels in the setting of supra-therapeutic anticoagulation.

The alternative to endovascular repair is standard open repair. This option carries a mortality rate of up to 13% [5,6]. Likely due to the fact that patients typically undergoing open procedures are those that present initially with rupture and are unstable. Open repair options include simple ligation, interposition graft if necessary, or aorto-iliac reconstruction. The latter is usually reserved for those patients with concomitant distal aorto-iliac occlusive or aneurysmal disease [11,12].

We would emphasize that better occlusion of the outflow tracts, along with optimal control of INR in the post intervention period may have resulted in a more successful outcome from an endovascular approach in this case. Using an Endovascular approach may have avoided the prolonged hospital stay and complications of emergent open procedure in this elderly male with multiple comorbidities. Ultimately management approach must be individualized according to the skill set and resources available to the surgeon.

References

1. Parry DJ, Kessel D, Scott DJ (2001) Simplifying the internal iliac artery aneurysm. *Ann R Coll Surg Engl* 83: 302-308.
2. Kelckhoven BJ, Bruijninx BMA, Knippenberg B, Overhagen HV (2007) Ruptured Internal Iliac Artery Aneurysm: Staged Emergency Endovascular Treatment in the Interventional Radiology Suite. *Cardiovasc Intervent Radiol* 30: 774-777.
3. Dix FP, Titi M, AL Khaffaf H (2005) The isolated internal iliac artery aneurysm; A review. *Eur J Endovasc Surg* 30: 1119-129.
4. McCready RA, Pairolero PC, Gilmore JC, Kazmier FJ, Cherry KJ Jr, et al. (1983) Isolated Iliac Artery Aneurysm. *Surgery* 93: 699-703.
5. Kashi C (2006) Spontaneous Rupture of Hypogastric Artery Aneurysm into the Bladder: A Case Report and Review of the Literature. *Ann Vasc Surg* 20: 134-137.
6. Zimmer PW, Raker EJ, Quigley TM (1999) Isolated Hypogastric Artery Aneurysms. *Ann Vasc Surg* 13: 545-549.
7. Kim JK, Noll RE Jr, Sternbergh WC 3rd, Tonnessen BH (2008) Endovascular Repair of a Ruptured Internal Iliac Artery Aneurysm With a Novel Application of the Aorto-uni-iliac Converter Device. *Vasc Endovascular Surg* 42: 466-470.
8. Chandra A, Kansal N (2009) Hybrid Repair of Isolated Internal Iliac Artery Aneurysm. *Vasc Endovascular Surg* 43: 583-588.
9. Cheong SK, Varcoe RL (2010) A Tapered Contralateral Endurant Stent Graft Limb, Deployed "Up-And-Over" to Treat a Symptomatic Internal Iliac Aneurysm. *Vasc Endovascular Surg* 44: 475-478.
10. Brin BJ, Busuttill RW (1982) Isolated Hypogastric Artery Aneurysms. *Arch Surg* 117:1329-1333.
11. Sorelli (2009) A surgical emergency. *BMJ* 339: b2302-b2302.
12. McFarlane MEC (2009) Internal iliac artery aneurysm-colonic fistula: a rare presentation of massive lower gastrointestinal haemorrhage: report of a case. *European Surgery* 41.