

Snodgrass Repair of Hypospadias (10 years Experience of a Modified Technique)

Shoeib MA*

Department of Plastic Surgery, Sohag Faculty of Medicine, Sohag, Egypt

*Corresponding author: Shoeib MA, MD Department of Plastic Surgery, Sohag Faculty of Medicine, Sohag, Egypt – 82542, E-mail: mrahmoni@yahoo.com

Received date: October 2, 2015, Accepted date: November 20, 2015, Published date: November 28, 2015

Copyright: © 2015, Shoeib MA. This is an open-access article distributed under the terms of the Creative Commons Attribution License, which permits unrestricted use, distribution, and reproduction in any medium, provided the original author and source are credited.

Introduction

Surgical reconstruction is the only possible therapeutic option for hypospadias [1]. The primary objectives of the reconstruction are to create a vertically slit orthotopic meatus, straighten the penis in case of curvature and establish good cosmetic results that include a conically shaped glans. The optimal age for correction of hypospadias is between the 6th and the 24th month. Thanks to the possibility of topical application of dihydrotestosterone, it is possible to optimise the size of the penis at this early age of operation [2]. In the majority of cases, the operation can be done in one step. A two-step approach is rarely necessary, for example, in case of insufficiency of the urethral plate or hypoplastic skin as often found in Re-Do Hypospadias [3]. Lately, the concept of incision and tubularisation of the urethral plate with consecutive secondary healing, as popularised by Snodgrass et al., has revolutionized hypospadias surgery [4]. Its low complication rates, excellent cosmetic results and the simple surgical technique have made it very popular among hypospadias surgeons [5]. The initial concerns and, subsequently, reports about increased stenosis have become quite seldom [6,7].

As long as there is no penile curvature, this technique is the method of choice for distal hypospadias [7]. This method is increasingly applied for the repair of penile hypospadias as well [4]. Nonetheless, there are still complications mostly fistulas reported in [7]. In order to prevent fistulas, particularly healthy tissue from different areas is used to cover the neourethra using different techniques.

In our work we use an on lay graft from the inner aspect of the prepuce to be grafted to the raw area of the incised urethral plate before tubularization, and dartos flap to cover the repair.

Keywords: Hypospadias; Snodgrass; Dihydrotestosterone; Neourethra

Patients and Methods

A total of two hundreds twenty five patients randomly selected, were enrolled in our study in the last 10 years.

The age of the patients were 2-15 years with median age 8.5 years. All types of hypospadias were included except those with penoscrotal type, those with marked chordee that leads to devitalization of the urethral plate or the circumcised ones.

Because of late presentation of patients we did not use hormonal therapy preoperatively.

Each patient was done in one stage operation.

Surgical technique

The surgical procedure is performed with the patient under general anesthesia or caudal block one. The graft was harvested from the inner aspect of the prepuce (Figure1).

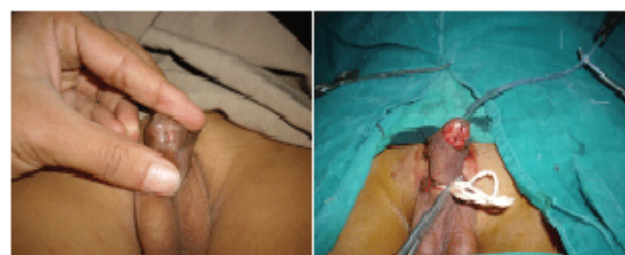

Figure 1: Pre, and intra-operative picture of the technique (distal penile hypospadias).

All grafts were accurately freed from adherent subcutaneous fat and connective tissue. The tailored graft was inserted between the split urethral plate, stitched to medial margins of the incised urethral plate using interrupted 6-0 absorbable sutures in a tension free manner.

The patch was fixed to the tunica albuginea using two to three stitches in the middle, guaranteeing sufficient blood supply. The edges of the incised urethral plate were then tubularized over an indwelling lenton catheter (6-14 Fr feeding tube) using 6-0 polydioxanone sutures. The glanular wings were separated from the distal urethral plate by parallel longitudinal incision, and reconstruction was started at the neomeatus proceeding to the corona with tension free closure. To provide a barrier layer for the neourethra, preputal dartos flap was placed over the neourethra as the second layer. It passes over the glans penis via a window to lie on the repair without any tension. Finally, the penile shaft skin is closed by transposing the dorsal skin to cover the repair in a tension free manner.

The catheter remained indwelling for 7-12 days (Figure 2).

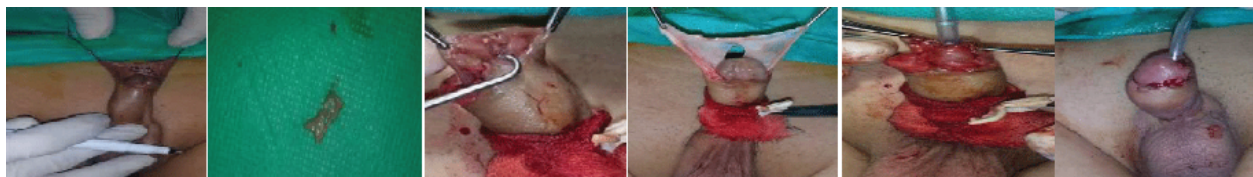

Figure 2: Illustrate the steps of the technique, upper right graft marking, middle graft harvested, left, graft in place, below right dartos flap dissected, middle, after tabularization left end result of the technique.

Results

The age of the patients were 2- 15 years with median age 8.5 years. The mean follow up was 10 months (range, 6 months to 4 years). Location of hypospadias was distal penile in 57 patients (25.3%), mid-penile in 112 (49.7%) and proximal penile in 56 patients (25%).

The following complications occurred in 20 patients (8.8%): fistula formation in 6 (2.6%), wound infections in 14 (6.2%), and no meatal stenosis in any of the cases. There were no cases of hematoma or other complications. The patients with wound infections were treated conservatively with complete healing within one week, except for 3 of them who develop fistula and included in the fistula complications. The mean time for catheter application were 8 days ranging from 7-12 days (Figures 3 and 4).

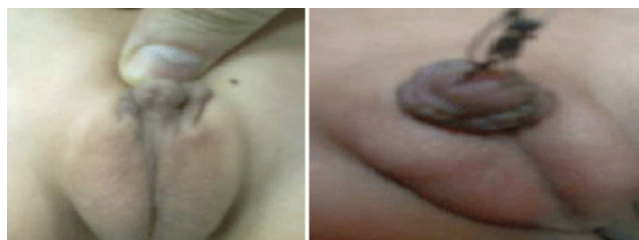

Figure 3: Preoperative and before catheter removal

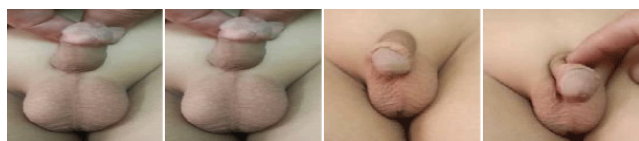


Figure 4: preoperative ,intra operative, and post operative.

Discussion

Several different surgical methods have been proposed to achieve normal appearing penis with low complications rates in the treatment of hypospadias.

At times in cases of proximal hypospadias the urethral plate is very narrow. Consequently, the urethral plate needs to be augmented or substituted for further tubularisation [8].

Some of these techniques use the penile skin while some other methods use extra penile tissues, including the buccal mucosa [9], the skin graft [10], but we used a local graft from the inner aspect of the

prepuce which is an easy technique, single procedure, in the same field of the operation, and without donor tissue morbidity as done by Kolon and Gonzales [11] who described a technique of 1-stage urethroplasty using an inner preputial based dorsal inlay graft. They used this technique in 32 patients and at 21 months of follow-up no patient had a stricture, fistula or diverticulum at the inlay graft site. Similarly Schwentner et al. [12] have reported on their experience with single stage dorsal inlay urethroplasty using skin grafts in 31 patients. After a mean follow-up of 30.71 months five patients underwent redo surgery, for a complication rate of 16.1%.

Snodgrass procedure or Incised Plate Urethroplasty is a method with high success rate; [13] however, urethra-cutaneous fistula is a common complication following this technique. [14]. To decrease the rate of this complication, a vascularized tissue is applied as a second layer between the neo-urethra and the skin coverage [15].

A study in Turkey demonstrated better cosmetic results using mucosal collars. In that study, fistula and meatal stenosis rates were 8.3% and 14%, respectively [16]. The use of the preputal inlay graft in our work plus the preputal vascularised dartos flap reduces the meatal stenosis, which is the main cause of fistula formation to zero, also reduces the rate of fistula to 2.6%.

Conclusion

Our results showed that Snodgrass technique in combination with inlay graft from the inner aspect of the prepuce is a reasonable method for hypospadias repair, resulting in good cosmetic appearance and low complication rates. By this modification, beside it is a single operation, avoidance of meatal stenosis decreases the likelihood of fistula formation, which is the most common complication.

References

1. Baskin LS, Ebbers MB (2006) Hypospadias: anatomy, etiology, and technique 41: 463-472.
2. Monfort G, Lucas C (1982) Dehydrotestosterone penile stimulation in hypospadias surgery 8: 201-203.
3. Perovia S, Vukadinovic V (1992) Penoscrotal transposition with hypospadias: 1-stage repair 148: 1510-1513.
4. Snodgrass W, Koyle M, Manzoni G, Hurwitz R, Caldamone A, et al. (1998) "Tubularized incised plate hypospadias repair for proximal hypospadias," *The Journal of Urology* 159: 2129-2131.
5. Snodgrass W (1994) Tubularized, incised plate urethroplasty for distal hypospadias 151: 464-465.
6. Snodgrass W, Koyle M, Manzoni G, Hurwitz R, Caldamone A, et al. (1996) Tubularized incised plate hypospadias repair: results of a multicenter experience. 156: 839-841.
7. Jayanthi VR (2003) The modified Snodgrass hypospadias repair: reducing the risk of fistula and meatal stenosis 170: 1603-1605.

-
8. Nerli RB, Guntaka AK, Patil RA, Patne PB (2014) Dorsal inlay inner preputial graft for primary hypospadias repair 11: 105-108.
 9. ML Djordjevic, SV Perovic, Z Slavkovic, and N Djakovic (2006) "Longitudinal dorsal dartos flap for prevention of fistula after a Snodgrass hypospadias procedure," *European Urology* 50:53-57.
 10. Ahmed S, Gough DC (1997) Buccal mucosal graft for secondary hypospadias repair and urethral replacement. 80: 328-330.
 11. Kolon TF, Gonzales ET Jr (2000) The dorsal inlay graft for hypospadias repair 163: 1941-1943.
 12. Schwentner C, Gozzi C, Lunacek A, Rehder P, Bartsch G, et al. (2006) Interim outcome of the single stage dorsal inlay skin graft for complex hypospadias reoperations 175: 1872-1876.
 13. Snodgrass W (1994) Tubularized, incised plate urethroplasty for distal hypospadias 151: 464-465.
 14. Duckett JW Jr, Kaplan GW, Woodard JR, Devine CJ Jr (1980) Panel: complications of hypospadias repair 7: 443-454.
 15. Yang SS, Chen SC, Hsieh CH, Chen YT (2001) Reoperative Snodgrass procedure 166: 2342-2345.
 16. Firlit CF (1987) The mucosal collar in hypospadias surgery 137: 80-82.