

# Synergistic 3D Approach with Plastic Surgery and Anaplastology to Achieve Optimal Facial Restoration after Oncologic Orbital Exenteration

Ryan J Jacobs, Katherine A Rodby, Karina P Quinn, Rosemary Seelaus and Anuja K Antony\*

University of Illinois at Chicago, Chicago, Illinois, USA

## Introduction

Reconstructive surgery after oncologic resection can restore form and function of critical areas of the face and body with native tissue. However, some defining structures cannot be adequately reconstructed without the use of prosthetics due to the lack of alternative tissue substitutes. Anaplastology provides an important service for difficult to reconstruct areas in order to achieve the best aesthetic outcomes, improving patient confidence and quality of life.

Tumors of the orbit often require complex surgical exenteration followed by adjuvant radiation treatment [1]. After extensive oncologic resections, initial reconstructions using distant tissue are required to fill the defect, recreate the basic form of the damaged structure, and allow for any other interim interventions [2-4]. A prosthetic can be utilized at a later stage to achieve the final result [5]. Thus, complete therapeutic and rehabilitative therapy of patients with orbital tumors requires the multidisciplinary collaboration of individuals across the medical and surgical fields. As acceptable results in craniofacial reconstruction require detailed planning and a high degree of surgical accuracy, three-dimensional (3D) imaging using Computer Tomography (CT) has been established as a standard to achieve this anatomical precision [6,7]. Technological advances including 3D photography, surface scanning, and 3D CT imaging have allowed for successful prosthetically-driven fabrication of facial prostheses, transforming a time consuming artistically driven process to that of a reconstructive biotechnology process [8]. In this same vein, we have found that technological advances such as 3D photography also facilitate multidisciplinary collaboration to effectively achieve a synchronized effort for facial restoration. Advantages of 3D photography over other current technology to obtain a realistic, accurate external surface image of the face include high-speed capture and decreased possibility of distortion due to facial movement when compared with laser scanning, as well as radiation-free and more ideal upright-positioned capture for optimal soft tissue contour when compared with 3D CT imaging; 3D photography is expanding the treatment planning process of visualization of the proposed facial prosthesis [8,9]. We highlight a recent case where the oncologic resection resulted in anophthalmia, with immediate Vertical Rectus Abdominus Myocutaneous (VRAM) free flap reconstruction to protect the exposed underlying vital structures. Preoperative planning between the anaplastologist and plastic surgeon with use of 3D photographic imaging allowed for an effective ophthalmic reconstruction.

A 45 year old Hispanic female developed squamous cell carcinoma of the lacrimal sac requiring orbital exenteration and a limited neck dissection. Immediate soft tissue coverage was obtained with a VRAM flap to obliterate the cavity and cover the underlying exposed dura and cranial contents, which was left bulky due to planned radiation therapy. Despite 50% volume reduction after radiation, the patient continued to have a bulky flap, preventing further reconstructive efforts and placement of an orbital prosthesis. The patient required two flap debulking surgeries in order to achieve an adequate flap thickness that

would not compromise space or stability of the prosthetic eye. After a significant but incomplete initial debulking, 3D images were taken for a detailed analysis and coordinated preoperative planning with the anaplastologist and plastic surgeon.

While the primary goal of reconstruction following orbital exenteration is lining or filling of the defect to protect the cranial contents, orbital exenteration without full rehabilitative efforts is debilitating to patients due to the resulting psychosocial disability [4,5]. Therefore, many patients strongly desire to obtain a prosthetic [2,3]. Typically, open cavity reconstruction of the orbital socket is the preferred method when postoperative use of an orbital prosthesis is planned [8]. However, in this case, closed cavity reconstruction was chosen over open cavity reconstruction to optimize flap viability and protect the cranial contents due to planned future radiation treatments. Due to the bulky nature of closed cavity reconstruction, unique challenges were encountered and more extensive reconstructive surgery was required to ensure a secure fit of an orbital prosthesis. The initially bulky VRAM flap limited the ability to place an orbital prosthesis, thus hindering anaplastologist prosthetic rehabilitative efforts. However, there was concern that overly aggressive debulking would potentially compromise flap perfusion in the setting of previous radiation. Furthermore, irradiated sites have been shown to be at greater risk for tissue necrosis when subjected to prosthetics and implant surgery [10].

As a result of these concerns, further reconstructive efforts after the initial incomplete debulking were coordinated preoperatively between the anaplastologist and plastic surgeon. 3D photographic imaging of the patient was first performed. Difference mapping using superimposition of the non-exenteration side over the exenteration side enabled an accurate determination of tissue defects and depth differences (Figure 1). Additional cross sectional analysis allowed for differential assessment of canthus position bilaterally, supplementing clinical judgment in the planning of prosthetic positioning and placement (Figure 2). Furthermore, use of 3D photographic imaging over traditional CT circumvented additional radiation exposure.

After analysis of the 3D imaging, synergistic planning between the anaplastologist and plastic surgeon enhanced the ability of the plastic surgeon to precisely debulk the VRAM flap for placement of a prosthetic while ensuring adequate flap volume and orbital coverage

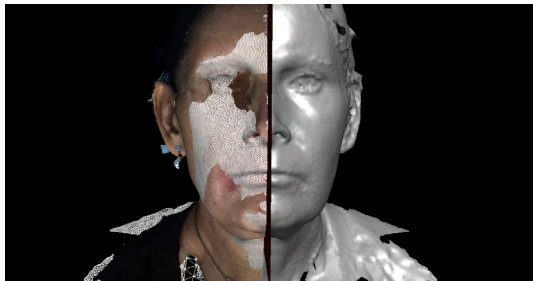\*Corresponding author: Anuja K. Antony, University of Illinois at Chicago, Chicago, Illinois, USA, E-mail: [akantony@uic.edu](mailto:akantony@uic.edu)

Received December 02, 2013; Accepted December 20, 2013; Published December 24, 2013

Citation: Jacobs RJ, Rodby KA, Quinn KP, Seelaus R, Antony AK (2013) Synergistic 3D Approach with Plastic Surgery and Anaplastology to Achieve Optimal Facial Restoration after Oncologic Orbital Exenteration. Anaplastology 3: e111. doi: [10.4172/2161-1173.1000e111](https://doi.org/10.4172/2161-1173.1000e111)

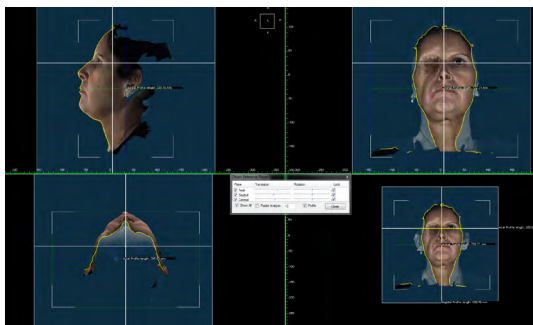
Copyright: © 2013 Jacobs RJ, et al. This is an open-access article distributed under the terms of the Creative Commons Attribution License, which permits unrestricted use, distribution, and reproduction in any medium, provided the original author and source are credited.

**DIFFERENCE MAPPING: SUPERIMPOSITION OF NON-TREATMENT SIDE OVER TREATMENT-SIDE**



**Figure 1:** Difference Mapping: Superimposition of Non-Treatment side over Treatment-side using three dimensional photographic analysis.

**CROSS-SECTIONAL COMPARISON THROUGH CANTHI**



**Figure 2:** Cross-sectional comparison of Treatment and Non-treatment sides through the canthi in multiple views.

to prevent future complications. After debulking, the anaplastologist was able to securely position the prosthetic and achieve a functionally and aesthetically acceptable result. Reconstructive planning for optimal aesthetic and functional outcome is better realized when the coordinated multidisciplinary efforts of the reconstructive surgeon and the anaplastologist are further enhanced with the evolution of 3D photographic imaging technology.

**References**

1. Weizman N, Horowitz G, Gil Z, Fliss DM (2013) Surgical management of tumors involving the orbit. *JAMA Otolaryngol Head Neck Surg* 139: 841-846.
2. Pryor SG, Moore EJ, Kasperbauer JL (2005) Orbital exenteration reconstruction with rectus abdominis microvascular free flap. *Laryngoscope* 115: 1912-1916.
3. Hanasono MM, Lee JC, Yang JS, Skoracki RJ, Reece GP, et al. (2009) An algorithmic approach to reconstructive surgery and prosthetic rehabilitation after orbital exenteration. *Plast Reconstr Surg* 123: 98-105.
4. Santamaria E, Cordeiro PG (2006) Reconstruction of maxillectomy and midfacial defects with free tissue transfer. *J Surg Oncol* 94: 522-531.
5. Taylan G, Yildirim S, Aköz T (2006) Reconstruction of large orbital exenteration defects after resection of periorbital tumors of advanced stage. *J Reconstr Microsurg* 22: 583-589.
6. Perry M, Banks P, Richards R, Friedman EP, Shaw P (1998) The use of computer-generated three-dimensional models in orbital reconstruction. *Br J Oral Maxillofac Surg* 36: 275-284.
7. Kubal WS (2008) Imaging of orbital trauma. *Radiographics* 28: 1729-1739.
8. Davis BK (2010) The role of technology in facial prosthetics. *Curr Opin Otolaryngol Head Neck Surg* 18: 332-340.
9. Pan J, Zhao Y, Wu G (2006) Application of phase measuring profilometry in digital data acquisition for CAD/CAM of unilateral orbital prosthesis with remaining eye open. *J US China Med Serv* 3: 13-18.
10. Schoen PJ, Raghoobar GM, van Oort RP, Reintsema H, van der Laan BF, et al. (2001) Treatment outcome of bone-anchored craniofacial prostheses after tumor surgery. *Cancer* 92: 3045-3050.