

Tumor Management Phyllodes in an 11-Year-Old Girl: A Case Report

Benda Arcos-Vera^{1*}, Jose Cruz Ubias-Osorio² and Dante Arcos-Vera³

¹Department of General Surgery, Medical Center ISSEMYM Toluca, Mexico

²Maternal and Child Hospital ISSEMYM Toluca, Mexico

³Department of Gynecology and Obstetrics, Monica Pretelini Maternal and Perinatal Hospital, Toluca, Mexico

*Corresponding author: Benda Arcos-Vera, Department of General Surgery, Medical Center ISSEMYM Toluca, Mexico, Tel: 7222753288; E-mail: perladeshicon@hotmail.com

Received date: October 23, 2018; Accepted date: January 30, 2019; Published date: February 6, 2019

Copyright: © 2019 Vera BA, et al. This is an open-access article distributed under the terms of the Creative Commons Attribution License, which permits unrestricted use, distribution and reproduction in any medium, provided the original author and source are credited.

Abstract

Introduction: The tumor Phyllodes is a rare tumor in the breast with an incidence of 1: 100,000 inhabitants and it presents from 0.3% to 0.9% of breast tumors, mostly at the age of 35 to 55 years, being uncommon at the extremes of life.

Clinical case: The first case report is presented at the ISSEMYM maternity hospital in Toluca of an 11 year old girl who was admitted to the emergency department for having a tumor in the right breast that has been growing rapidly for a week (10 × 9 × 5 cm) causing itching, hyperemia, painful palpation, which did not remit with medical management, is valued by the pediatric oncological surgery service, which proposed emergency surgical treatment (tumorectomy) since it did not involve the mammary gland and was not observed by malignancy data (by Ultrasound and Tomography); the histopathological result was Phyllodes tumor. Follow-up was given in the outpatient clinic at a month and the sixth month with imaging control without evidence of tumor activity.

Conclusion: The majority of lesions in children and adolescents are benign and the surgery that deforms the normal anatomy of the breast should be avoided.

Keywords: Breast tumor; Phyllodes tumor; Surgery

Introduction

We present the first case report of Phyllodes tumor in the ISSEMYM Maternal and Child Hospital of 11-year-old female, its diagnosis, and surgical management. The term Phyllodes by its Greek etymology means: As a leaf [1], which describes the papillary projections that are seen in the pathological examination; within their histological prognosis, 35%-64% is benign, 15%-35% malignant and the rest borderline [2], with a risk of malignancy of 2.1 per million women.

The majority of the tumors in children and adolescents are benign and limited, even so, the breast tumor findings can confuse the patient [3] so the proper diagnosis must be made. The Phyllodes tumor is a rare fibroepithelial tumor with a high risk of recurrence, sometimes degenerating into sarcomatous lesions with lack of epithelial component [4].

The phyllodes tumor usually occurs in women between 35 to 55 years old; although it can occur at the extremes of life, this presentation is rare. Its incidence is greater in Latin America; as regions of Mexico, Central America and South America which have three times greater risk of suffering it. The main lineage presented is epithelial and the second group corresponds to non-epithelial tumors, in this group is the phyllodes tumor, which is a rare fibroepithelial lesion that accounts for 0.3%-0.9% of breast tumors. It was first described by Johannes Muller [2,5], initially calling it cystosarcoma phyllodes [5] and since its discovery, it has received more than 60 different names. Later in 1981, it coined the term phyllodes tumor by the World Organization of Health.

Due to its low incidence, there are not many studies regarding its etiology and prognostic factors, however, factors predisposing to a history of fibroadenoma have been identified, the Li-Fraumeni syndrome, autosomal dominant syndrome, in which there is overexpression of the p⁵³ that favors the appearance of multiple tumors in which there is a predisposition to develop Phyllodes breast tumors [5].

Clinical Case

Female, age 11, with a history of a maternal grandfather with Type II Diabetes Mellitus, and asthmatic maternal grandmother, denies cancer history/tumors in her family, is asthmatic as well as her 3 siblings. Her condition began 8 days before her admission with volume increase in the right breast at the beginning of 2 × 2 × 2 cm, indurated, mobile that generated itching, painful on palpation, nipple with no discharge, without weight loss; so they come to the doctor, performing ultrasound that reported phyllodes tumor of 7 × 7 × 5 cm, with intrinsic vascularity, without lymph node growth (Figure 1) valued by the gynecology and pediatric services. Giving medical treatment with ibuprofen, dicloxacillin and paracetamol which showed no improvement and increased its symptoms; therefore they come to a new assessment four days later with a new ultrasound reporting a discrete lobulated tumor of 8 × 8 × 5 cm in diameter, hypoechoic discretely heterogeneous with bright punctate images suggestive of microcalcifications, axillary region with oval hypovocal ganglia of 4-7 mm in diameter with echogenic hilum, with an echographically benign appearance-compatible with phyllodes tumor (Figure 2). When presenting a significant increase in size and pain, it is sent to this institution to be evaluated by the pediatric oncological surgery service.

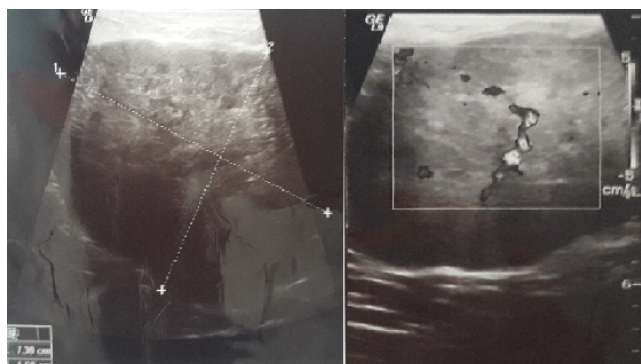


Figure 1: Tumor phyllodes of approximately $73 \times 70 \times 56$ mm, with intrinsic vascularity, without ganglionic growth.

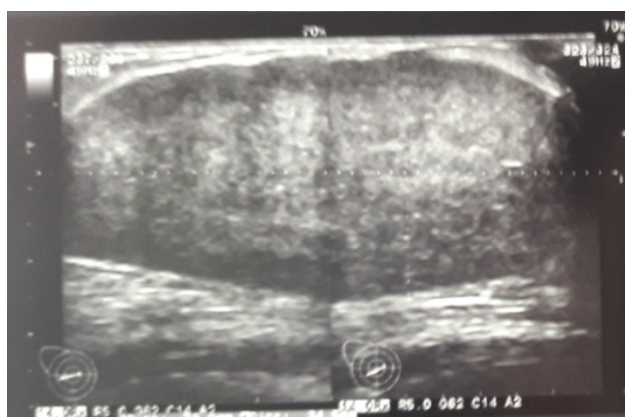

Figure 2: Phyllodes tumor, a discrete lobulated tumor of $83 \times 80 \times 53$ mm in diameter, hypoechoic, discretely heterogeneous with bright punctate images suggestive of microcalcifications, an axillary region with ovoid hypoechoic ganglia of 4-7 mm in diameter with echogenic hilum, echographically benign appearance without observing left axillary nodes.

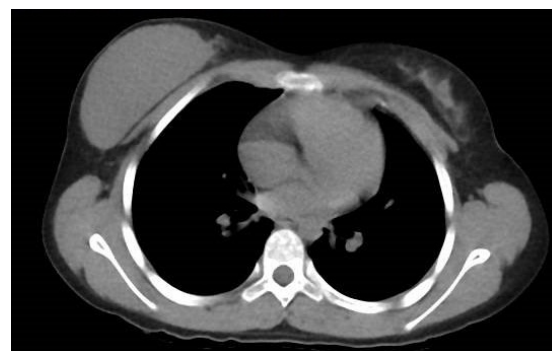

Figure 3: Simple chest tomography in which homogenous tumor is observed in right breast of approximately 95×60 mm with rounded edges which do not invade the pectoralis major muscle, left breast without evident alterations, without evidence of tumor activity in the lungs.

An assessment is requested by the pediatric oncological surgery service deciding surgical management urgently-right breast lumpectomy. In the operating room under general anesthesia, dorsal decubitus position (Figure 4) asepsis of the thorax and abdomen, sterile fields are placed, a peri-areolar incision with an omega-shaped extension is made, it is incised by subcutaneous planes, finding a tumor-independent mammary gland. The tumor was resected manually and with electrocautery, complete resection of the tumor was performed, which average approximately $10 \times 9 \times 5$ cm (Figure 5), hemostasis is verified, surgical wound is closed by subcutaneous planes with long absorbable suture material. Duration 3 zeros with simple points, skin monocryl 4 zeros submerged without incident (Figure 6). The compressive bandage is placed, and it is discharged the following postoperative day, attending a medical consultation at 4 weeks with adequate postoperative evolution, with a report of pathology reporting phyllodes tumor, ultrasonographic control was requested and it was reviewed in the sixth month without evidence of tumor.

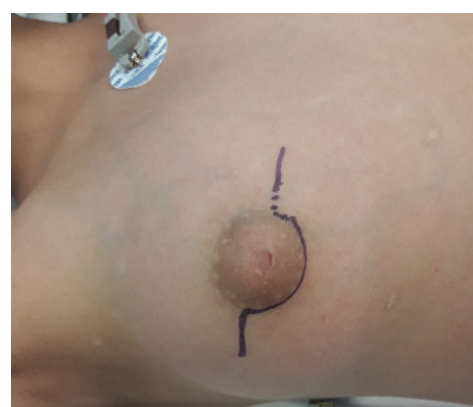

Figure 4: Right breast with La tumor of approximately $10 \times 9 \times 5$ cm, with defined edges, mobile, painful on palpation, a collateral venous network which reaches the infraclavicular region, surgical marking was done on the right Breast.

At his entry, he presents vital signs within normal parameters. Physical examination revealed an increase in the volume of the right breast, as well as an increase in the ipsilateral vascular venous network, a mobile tumor was felt, painful on superficial palpation, regular borders, occupied 3/4 of the mammary gland (external quadrants and upper right internal superior of approximately $10 \times 9 \times 5$ cm), left breast without alterations, no ganglion chains were palpated, rest without evident alterations. The following were requested for clinicians: Blood count, coagulation times, blood chemistry of 6 elements, gynecological profile, finding normal, and group B positive. Within the cabinet studies, a simple chest tomography was performed, observing right breast tumor of approximately 9×6 cm, with rounded edges, no invasion of major pectoral muscle, left breast without evident alterations (Figure 3).

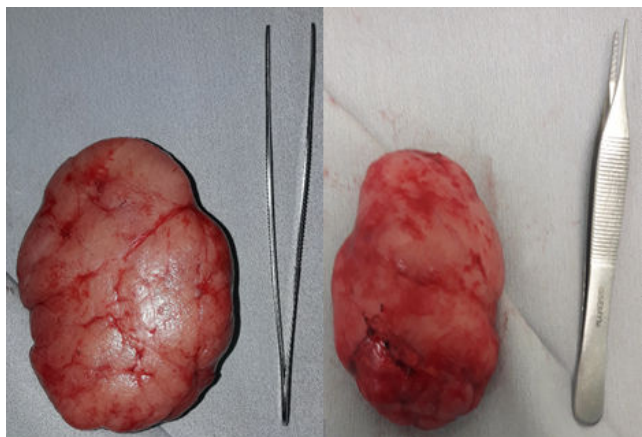


Figure 5: Tumor phyllodes of approximately $10 \times 9 \times 5$ cm in its anterior (left) and posterior (right) face, with regular edges of reddish yellow color, of solid consistency at 100%.

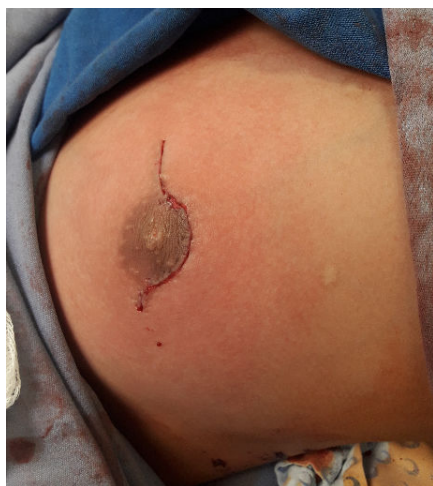

Figure 6: Right breast at the end of surgery, the four quadrants with hyperemia are observed.

Discussion

The Phyllodes tumor presents a size between 1-40 cm, with an average of 5 cm. This tumor has a size relation with risk of malignancy, being 73% of benign Phyllodes tumors <5 cm, while >7 cm are related to malignancy. The case presented shows a 10 cm tumor without invasion of the mammary gland without apparently malignant data in females aged 11 years at this age. The tumors are mostly benign, so it was decided to conserve the mammary gland and tumorectomy was performed instead of wide resection. Macroscopically, the smaller tumors resemble fibroadenomas with a white-gray fibrous appearance, while the larger ones resemble sarcomas. Recent reviews indicate that the older age presented at the time of diagnosis, they are related to a higher histological grade [5].

With respect to the clinical picture; patients may present with mammary tumor, mobility, hypersensitivity or pain as well as an

increase in the size of slow progression, adequate circumscribed borders, although there are also reports of rapid growth, as in this case, presenting a rapid, painful growth, with mobile borders, circumscribed. This can result in shiny skin, which may become translucent, with the increased venous network; the attenuated ulcerations of the skin are secondary to ischemia. Pain, nipple retraction, and skin fixation occur in benign as well as malignant tumors, so the symptoms do not necessarily indicate the nature of the tumor. Palpable axillary lymphadenopathies can be identified in 20% of patients but nodal metastases are uncommon. The Phyllodes tumor is most commonly found in the right breast [2,6], being bilateral in 1/3 of the cases. 35% of tumors are located in the upper external quadrant, 15% in the upper internal quadrant, 10% to 25% in the lower external and less than 10% in the internal lower quadrant. In 35% of patients, it is presented in a multicentric manner. The malignant forms present hematogenous metastasis mainly to the lung and bone, with nodal involvement being rare ($<1\%$ of cases), so the determination of sentinel lymph node is not indicated, let alone the performance of lymphadenectomy. Although up to 20% of cases can be palpated, adenopathies can be felt, they are usually secondary to an infectious process, in our case no adenopathies were palpated. The majority of mammary gland tumors in girls and adolescents are benign and symptomatic (mass effect, pain, etc.) and usually when they increase in size it is rare that they present regression [7].

An important problem is a diagnosis that involves the Phyllodes tumor, is that fine needle aspiration biopsy, mammography and ultrasound studies are not able to distinguish between fibroadenoma and phyllodes tumor. However, ultrasound is the most appropriate imaging study for the prepubertal and pubertal breast, since it allows recognizing the normal breast parenchyma [8]. The definitive diagnosis occurs in only one-third of the mammographic studies. Necrosis within the tumor is the main feature of the malignant Phyllodes tumor; however, histopathological confirmation is mandatory. A diagnostic fine needle aspiration biopsy is performed in only 70% of phyllodes tumors, with a false-negative rate close to 40%. The true cut needle biopsy is considered a highly accurate method to rule out malignancy with a sensitivity of approximately 95% to 97%, which is not done in our institution for administrative reasons. The determination of certain tumor markers such as MIB-1, p^{53} , p^{16} , p^{21} , KI-67, EGF (Epithelial Growth Factor) allows to predict the behavior and prognosis of the disease [5,9].

An appropriate excisional biopsy with margins >1 cm is recommended, if one thinks of phyllodes tumor, this being the main option for small tumors. Total mastectomy is suggested for tumors larger than 5 cm or malignant tumors, although the relationship between the size of the lesion and the size of the breast should be considered. The dissection of regional nodes is not indicated. The first goal of treatment is to reach negative margins. Local recurrence can be treated with additional local excision or mastectomy. Removal of the pectoral fascia or muscle is not routinely indicated unless this tissue is involved. When the initial excision of the tumor does not have the margin >1 cm, it is recommended to make a rescission to obtain an adequate margin and prevent local recurrence. In the case of local recurrence, rescission with margins $>2-3$ cm is recommended. In most cases, wide excision with adequate margins can be achieved without a mastectomy. Currently, surgical treatment is the main therapeutic option, making the removal of the tumor with free margins or simple mastectomy, depending on the case [9]. However, conservative treatment is the guideline in children and adolescents due to the

extremely low risk of breast cancer and the risk of performing an open biopsy or surgery for the development of the mammary gland.

The National Comprehensive Cancer Network (NCCN) indicates a resection with margins of at least 1 cm unless the size does not allow a good resection or an adequate aesthetic result. In a review, it was shown that when comparing local resection with wide local resection, recurrence decreased from 21% to 8%, from 46% to 29% and from 65% to 36%, in benign, borderline and malignant TF respectively [10].

With respect to radiotherapy (Table 1), local recurrence decreases and survival improves [2].

Radiation Therapy Indications
Regional recurrent disease
Borderline
Malignant
The adjuvant in tumors larger than 5 cm
Margins uncertain or less than 0.5 cm
Positive margins after mastectomy or conservative surgery

Table 1: Indications of radiotherapy in phyllodes tumor.

Chemotherapy in the primary and adjuvant treatment is not defined; if it could be used as a palliative treatment. Ifosfamide alone or in combination with doxorubicin or cisplatin can prolong survival and delay the progression of metastases in cases of high-grade phyllodes tumor. Up to 40% of phyllodes tumors have hormone receptors to estrogen; however, the role of hormone therapy has not been demonstrated.

Forecast

The most frequent metastases affect the lung, pleura, and bones. The benign and malignant phyllodes tumors recur locally in 25% and the latter variant having the potential for metastasis, mainly by hematogenous route. The data show that a large part of tumors larger than 10 cm have a recurrence rate seven times higher, while positive margins have a four times higher risk of recurrence, however in a retrospective study conducted by Morante et al. A total of 157 cases of phyllodes tumor determined that excision margins, whether free or compromised, were not significant factors for local or distant recurrence [11]. However, all phyllodes tumors can recur, regardless of their histology. Six-monthly examination of the breast is indicated, in conjunction with breast ultrasound and according to age, also mammography. Other imaging studies such as tomography or

magnetic resonance are requested depending on the clinical evolution of the patient.

Conclusion

The Phyllodes tumor is a very rare tumor and is more frequent in the fourth decade, although it can also occur at the extremes of life in a lesser proportion; in this case I debut at the age of 11 years as a tumor of rapid growth, mobile, with regular borders, painful on palpation, so emergency surgical management was decided. It is well known that the differential diagnosis is made with fibroadenomas, however, none of the imaging studies corroborates the diagnosis, and the definitive diagnosis is anatomopathological. The treatment of choice is surgical with resection margins >1 cm, leaving the use of radiotherapy and chemotherapy for aggressive forms, however, the majority of lesions in girls and adolescents are benign and that surgery that deforms the normal anatomy of the breast should be avoided, so you have to identify cases; in this case, we opted for lumpectomy, achieving adequate postoperative evolution without recurrence at 6 months with ultrasonographic control.

References

1. Torres AL (2013) Tumor phyllodes in adolescent. Presentation of a case. *Finlay Magazine* 3: 202-205.
2. Jimenez J, Marquez G, Olaya EJ, Gomez D, Arteaga AC (2013) Tumor phyllodes. *Perinatol Reprod Hum* 27: 106-112.
3. Greydanus DE, Matysina L, Gains M (2006) Breast disorders in children and adolescents. *Prim Care* 33: 455-502.
4. Chaney AW, Pollack A, McNeese MD, Zagars GK, Pisters PW (2000) Primary treatment of cystosarcoma phyllodes of breast. *Cancer* 89: 1502-1511.
5. Orribo O, Rodriguez R, Melgar L, Fernandez F, De La Torre FJ (2011) Phyllodes breast tumors: Clinic, treatment and prognosis. *Rev Chil Obstet Gynecol* 76: 389-394.
6. Torres L, Oliver M, Branch J, Monzon M (2007) Tumor phyllodes of the breast. Characterization in the province cienfuegos study of 20 years. *Rev Electron Biomed/Electron J Biomed* 2: 29-33.
7. Ruano JM, Duarte JC, Calderon CA, Cuevas P, Palafox R (2005) Masses of the mammary gland in pediatrics. *Acta Medica Grupo Angeles* 3: 165-177.
8. Mujica AC (2010) Breast Cancer in Adolescence. *SOGIA* 17: 8-12.
9. Neto WGC, Dalri LF, Chaves R, Luna CR, Field FRR, et al. (2015) Giant phyllodes tumor in an 11-year-old adolescent. *Adolesc Saude, Rio de Janeiro*, 12: 78-82.
10. Ibanez G, Marambio A, Jans J, Gamboa J, Donis P, et al. (2010) Filoid tumor of the breast. *Rev Chilena de Cirugia* 62: 119-124.
11. Morante Z, Araujo J, Sources H, Neciosup S, Mas L, et al. (2015) Phylloid tumor of the breast. Characteristics and prognosis in a retrospective cohort with 7 years of follow-up. *Carcinos* 5: 10-18.