

## Vomiting in Mild Head Injury, an Indicator for CT Scan

Muhammad Rafay\*, Farhad Hussain, Farhan Gulzar, Noor ul Ain, Salman Sharif

Department of Neurosurgery, Liaquat National Hospital, National Stadium Road, Karachi, Pakistan

### ABSTRACT

**Background:** Following head trauma, a CT scan of brain is considered as investigation of choice. We have noticed that many of the patients with one or more episodes of vomiting after mild head trauma have their CT scan within normal limits. Considering that, the aim of this study is to reconsider whether the vomiting is a good indicator of getting a CT scan or not.

**Methods:** This is a retrospective study. This study includes 370 patients with head trauma. The duration of the study is from April 2017 to October 2017. These patients were admitted to the Department of Neurosurgery, Liaquat National Hospital Karachi Pakistan. All the patients were retrospectively analyzed in terms of their CT scan findings.

**Results:** We selected 370 patients with a mild head injury and with one or more episodes of vomiting. Then we compare these patients in terms of their CT scan findings. A total of 370 patients were selected and analyzed for the study. 145 (39%) patients with vomiting had positive CT scan for any findings (i.e. SDH, EDH and contusions). While remaining 225 (61.0%) patients with head injury and vomiting had normal CT scan findings.

**Conclusion:** In mild head injury with one or multiple episodes of vomiting, majority of the patients had normal CT scan of brain. While around one-third of the patients had positive CT scan findings. So use of CT scan in mild head trauma patient with vomiting is still debatable and need more evidence and studies in this regard.

**Keywords:** Head trauma; CT scan; Mild head trauma; Neurosurgery

**Abbreviations:** CT: Computed Tomography; NICE: National Institute for Clinical Excellence; WHO: World Health Organization; EDH: Extra Dural Hemorrhage; SAH: Sub Arachnoid Hemorrhage; SDH: Sub Dural Hematoma; RTA: Road Traffic Accidents; GCS: Glasgow Coma Score

### INTRODUCTION

Following head trauma, the CT scan of brain is considered as an investigation of choice. It is quick and reliable test and helpful in detection of an intracranial lesion, prognostication, treatment and decision making. With a sensitivity and specificity up to 100% for detecting surgically significant head injuries [1]. In various guidelines, the indication of CT scan varies on a number of clinical predictors to obviate unnecessary CT scans. NICE guidelines provide a guide for the care of patients with head trauma [1]. Nowadays Canadian CT Head Rule is the most widely validated rule, with a sensitivity of 99%-100% and a specificity of 48%-77% [2].

Vomiting is considered as a good indicator to get a CT scan. But we observed that in most of the patients in mild head trauma, CT scan turned out to be normal even with multiple episodes of vomiting.

The National Institute for Health and Clinical Excellence head injury guidelines advise CT imaging within 1 hour if there is more than one episode of vomiting after head injury in adults and three or more episodes for children. But they found that only 13 to 45% of cases have abnormal findings on CT scan [3]. According to one study, only 15% of patients with mild traumatic brain injury have abnormal CT scan findings, and less than 1% require any neurosurgical intervention [2].

**Correspondence to:** Farhad Hussain, Department of Neurosurgery, Liaquat National Hospital, Karachi, Pakistan, Tel: +923003791958; E-mail: petarian1070@gmail.com

**Received date:** October 5, 2019; **Accepted date:** October 10, 2019; **Published date:** October 20, 2019

**Citation:** Rafay M, Hussain F, Gulzar F, Ain NU, Sharif S (2019) Vomiting in Mild Head Injury, an Indicator for CT Scan. *Surgery Curr Res* 9:331 doi: 10.35248/2161-1076.19.9.331

**Copyright:** © 2019 Rafay M, et al. This is an open-access article distributed under the terms of the Creative Commons Attribution License; which permits unrestricted use; distribution; and reproduction in any medium; provided the original author and source are credited.

Also a study of 152 patients stated that vomiting was associated with positive CT findings in 40-45% of cases [4]. Another large study suggested that vomiting is neither a high nor a medium risk factor in the decision rule for the use of CT head scans in children with minor head injuries [5].

We have noticed that many of the patients with one or more episodes of vomiting after mild head trauma have their CT scan within normal limits. Considering that, the aim of this study is to reconsider whether vomiting is a good indicator of getting a CT scan or not.

## MATERIAL AND METHODS

### Setting

This is a retrospective study. This study includes 370 patients with head trauma, as calculated by WHO sample size calculator. These patients were admitted to the Department of Neurosurgery, Liaquat National Hospital Karachi Pakistan. The patients are categorized as mild, moderate and severe injury according to GCS and their CT scan findings were compared with their clinical presentation and indicators.

### Duration

The duration of the study is from April 2017 to October 2017.

### Participants

We analyzed 370 patients with head trauma who were admitted during a defined period of time. All the patients with intoxication and metabolic derangements were excluded from the study.

### Operational definition

According to the World Health Organization head injury can be categorized as mild, moderate and severe depending upon Glasgow comma score.

**Mild head Injury:** A Glasgow Coma Scale score of 13-15 is defined as a mild head injury.

**Moderate head injury:** A Glasgow Coma Scale score of 9-12 is defined as moderate head injury.

**Severe head injury:** A Glasgow Coma Scale score of 3-8 is defined as a severe head injury.

**Ethics:** The institutional review board approved the research protocols.

### Outcome assessment

All the patients were retrospectively analyzed. Those patients of head trauma who presented with one or more episodes of vomiting were compared with their CT findings and their results were postulated.

## Data retrieval

The demographic data, clinical characteristics and CT scan findings were retrieved from the data bank of Neurosurgery Department and from the Health information and management services department by the residents.

## Inclusion criteria

All the patients with closed head trauma presented to us with vomiting.

- CT scan within 6 hours
- Age between 14 years to 60 years
- Mild head injury
- Exclusion criteria
- All the patients with intoxication and metabolic derangements were excluded from the study
- Open head injury
- Patients without symptoms of vomiting
- Age below 14 years and above 60 years
- Moderate and severe head injury

## RESULTS

Table 1: Demography.

Population	Percentage
Male	63%
Female	37%
RTA	73%
Assault	10%
Motorbike injury	77%
With helmet	36%
Without helmet	64%

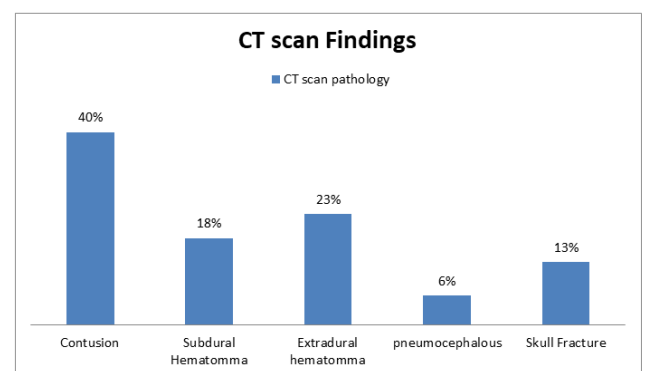
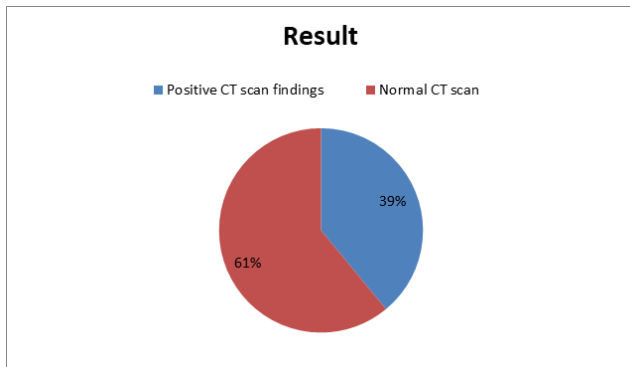


Figure 1: 61% of patients are with mild head injury and vomiting but with normal CT brain and 39% are with abnormal CT brain.



**Figure 2:** This bar chart showed the different types of brain injuries in patients with positive CT scan findings.

In our study we selected the patients with mild head injury, according to the sample size as calculated by WHO sample size calculator, and with one or more episodes of vomiting. Case study demography is been shown in Table 1. Then we compare these patients in terms of their CT scan findings. Total 370 patients were selected and analyzed for the study. 145 (39%) patients with vomiting had positive CT scan for any findings (i.e. SDH, EDH and contusions) (Figure 1). while remaining 225 (61.0%) patients with head injury and vomiting had normal CT scan finding (Figure 2).

## DISCUSSION

In the trauma and emergency departments, head injuries are commonly managed, among them 70-80% are mild in nature [6].

Most of the head injury patients are conscious on arrival and do not have a neurological deficit. However, such apparently minor head injury can rarely develop an intracranial hematoma, deteriorate, and die causing potential problems for neurosurgeons [7]. There is controversy regarding the policy for hospital admission and evaluation with CT scans for these patients.

A CT scan is desirable for patients with minor head injury as it is useful for the detection of a clinically significant intracranial lesion, prognostication, and decision for discharge [8]. Specifically talking about under-developed parts of world, unnecessary CT scans impose an extra financial burden and unnecessary waste of resources. So one needs to keep in mind these factors while advising CT scans.

To obviate unnecessary CT scans, many guidelines are available for indication of a CT scan for minor head injury in adults [9].

Among these, the Canadian CT Head Rule is the most widely validated rule, with a sensitivity of 99%-100% and a specificity of 48%-77% [9].

Other rules differ considerably in population, predictors, outcomes, methodological quality, and performance. Many of them are not validated in a separate population, and their impact on practice has not been assessed.

Specifically talking about the vomiting in mild head injury patients, in our population 39% patients with vomiting have positive CT scan findings (contusion, EDH, SDH, SAH). The rest of the 61% of patients with vomiting had Normal CT scans without any significant brain parenchymal injury.

We had some limitations with our study as can be seen with the number of clinical predictors used in the study.

Our study predicts that in mild head trauma with vomiting, more than one-third percentage of patients had any significant CT scan findings while rest of the patients had normal CT scan brain.

Vomiting can be used as an indicator of CT scan after mild head trauma but not necessarily immediately, but we can delay and can observe if there is a need for CT scan [1].

## CONCLUSION

In mild head injury with one or multiple episodes of vomiting, majority of the patients had normal CT scan brain. While around one-third of the patients had positive CT scan findings. So use of CT scan in mild head trauma patient with vomiting is still debatable and need more evidence and studies in this regard.

## REFERENCES

1. National Collaborating Centre for Acute Care (UK). Head injury: Triage, assessment, investigation and early management of head injury in infants, children and adults. 2007.
2. Mishra RK, Munivenkatappa A. Clinical predictors of abnormal head computed tomography scan in patients who are conscious after head injury. *J Neurosci Rural Pract.* 2017;8:64-67.
3. Bainbridge J, BChB, FRCe, Khirwadkar H. Vomiting-is this a good indication for CT head scans in patients with minor head injury? *Br J Radiol.* 2012;85:183-186.
4. Rahman YS, Den AS, Maull K. Prospective study of validity of neurologic signs in predicting positive cranial computed tomography following head trauma. *Prehosp Disaster Med.* 2010;25:59-62.
5. Osmond MH, Klassen TP, Wells GA, Correll R, Jarvis A, Joubert G, et al. CATCH: A clinical decision rule for the use of computed tomography in children with minor head injury. *CMAJ.* 2010;182:341-348.
6. Vos PE, Alekseenko Y, Battistin L, Ehler E, Gerstenbrand F, Muresanu DF, et al. Mild traumatic brain injury. *Eur J Neurol.* 2012;19:191-198.
7. Pandor A, Goodacre S, Harnan S, Holmes M, Pickering A, Fitzgerald P, et al. Diagnostic management strategies for adults and children with minor head injury: A systematic review and an economic evaluation. *Health Technol Assess.* 2011;15:1-202.
8. Stiell IG, Clement CM, Rowe BH, Schull MJ, Brison R, Cass D, et al. Comparison of the Canadian CT head rule and the new orleans criteria in patients with minor head injury. *JAMA.* 2005;294:1511-1518.
9. Stiell IG, Wells GA, Vandemheen K, Clement C, Lesiuk H, Laupacis A, et al. The Canadian CT head rule for patients with minor head injury. *Lancet.* 2001;357:1391-1396.