

A Report of Two Cases with Different Methods of Indexing for Orbital Prosthesis in Craniofacial Rehabilitation

Ajay Jain*, Sridevi Ugrappa, See Gaik Lan

Associate Professor, Faculty of Dentistry, AIMST Dental Institute, AIMST University, Semeling 08100 Bedong, Kedah, Malaysia

ABSTRACT

Prosthetic rehabilitation of an orbital defect plays an important role in restoring the aesthetics of the face; therefore psychology, well-being and social acceptance of the patient in the society. The most difficult task in fabricating an orbital prosthesis is maintaining the position of the eye shell in the silicone without positional discrepancy during processing. This paper describes two simplified techniques for the rehabilitation of two patients with an orbital defect, using two different indexing methods to maintain the integrity of an artificial eye with the silicone. The case report one discusses the technique of hollow orbital prosthesis fabrication by indexing on the rear side of an artificial eye and case report two discusses the technique of solid orbital prosthesis fabrication by indexing on the front side of the artificial eye. The techniques presented in this case report are easy to perform to fabricate hollow and solid orbital prosthesis whereby, the wholeness of silicone with the artificial eye is maintained by two different indexing methods. The technique described is a simple and easy way for the fabrication and rehabilitation of an orbital defect with hollow and solid orbital prosthesis using silicone, where retention is achieved by a combination of medical-grade adhesive and to a very small extent by bony and soft tissue undercut, hence providing a better aesthetic and psychological outcome.

Keywords: Custom made; Indexing; Orbital defect; Orbital exenteration; Orbital prosthesis

INTRODUCTION

Orbital defects commonly arise from post-operative treatment of tumors originating from the orbital contents, or due to the spread of tumors originating from paranasal sinus, palate, nasal cavity, overlying skin, and intra-oral mucosa. They can also result from mid-facial trauma associated with orbital fractures and damage to the orbital contents, and related surgeries. These defects lead to significant facial disfigurement, functional limitations, and negative psychological impact on the patient [1]. Prosthetic rehabilitation is an alternative treatment option for surgical reconstruction as these prostheses mimic the patient's missing structures and have an acceptable aesthetic outlook. They also permit hygiene maintenance around the defect and observation for tumor recurrence [2]. The main purpose of the maxillofacial prosthesis is to restore facial structures with artificial substitutes. Prosthesis for orbital defects is made from a variety of materials, such as polymethyl methacrylate, polyurethane elastomer, silicone elastomer, or urethane backed medical grade silicone and are mainly retained using mechanical means such as anatomical undercuts, spectacle frames, or by the use of osseointegrated extra-oral implants [3]. The most difficult task in

fabricating an orbital prosthesis is maintaining the position of the eye shell in the silicone without any positional discrepancy during processing [4]. This case report describes simplified techniques for the rehabilitation of two patients with an orbital defect, using two different indexing methods to maintain the integrity of an artificial eye with the medical-grade silicone.

CASE DESCRIPTION AND METHOD

Case report 1

A 45 years old female patient suffering from facial disfigurement with the loss of her right eye, was referred to the AIMST University Dental Clinic for maxillofacial prostheses. The patient visited the clinic with the stock eye in place to cover the defect (Figure 1a). History revealed exenteration of orbit on the right side when she was 5 years old, due to the eradication of retinoblastoma. Examination of the patient showed a large orbital defect on the right side with definite bony or soft tissue undercuts which would be assisting in the retention of the prosthesis. The slight opening was noted between the upper and lower conjunctival palpebral with no pain

*Corresponding to: Ajay Jain, Associate Professor, Faculty of Dentistry, AIMST Dental Institute, AIMST University, Semeling 08100 Bedong, Kedah, Malaysia, Tel: : +60109454204; E-mail: jainajay9@gmail.com

Received: March 16, 2021; Accepted: June 30, 2021; Published: July 07, 2021

Citation: Jain A, Ugrappa S, Lan SG (2021) A Report of Two Cases with Different Methods of Indexing for Orbital Prosthesis in Craniofacial Rehabilitation. *Reconstr Surg Anaplastol* 10: 185.

Copyright: 2021 © Jain A, et al. This is an open access article distributed under the terms of the Creative Commons Attribution License, which permits unrestricted use, distribution, and reproduction in any medium, provided the original work is properly cited.

and inflammation (Figure 1b). The patient had slight discomfort of using the stock eye over the defect and desired to replace it with the silicone prosthesis. The treatment aimed at the fabrication of hollow orbital prosthesis, partially retained by the medical-grade adhesive and partially by the bone and soft tissue undercuts so that tissues underneath are not disturbed. The treatment plan was explained to the patient and informed consent was obtained. Impression was made using polyvinylsiloxane impression material of light body consistency (3M ESPE Express STD, 3M ESPE Dental Products, ST Paul, MN, USA) and later it was backed up by the putty consistency polyvinylsiloxane impression material (3M ESPE Express STD, 3M ESPE Dental Products, ST Paul, MN, USA) and type-I gypsum products (UltraRock, Kalabhai Karson Pvt. Ltd, Mumbai, India) to prevent deformation of the impression (Figure 2). The impression was cast in type-IV gypsum product (Ultra Rock, Kalabhai Karson Pvt. Ltd, Mumbai, India) to obtain the facial moulage of the patient. An eye shell matching the sclera and iris color of the patient's left eye was selected from an array of stock acrylic eye shells and trimmed accordingly. Measurements were made from the patient's facial midline to the center of the pupil, and from the inner canthus of the eye to the nasal bridge. Both the measurements were made when the patient was asked to look and fix the contralateral eye at distant gaze. These measurements were transferred to the cast to aid in the position of the ocular portion of the orbital prosthesis. The wax pattern was completed using modeling wax (Metrowax, Metrodent Ltd. Huddersfield, England) on the model and the patient was called for the try-in (Figure 3). After successful try-in, the tried-in wax pattern was transferred onto the duplicated model. Now, the most critical step is to maintain the integrity of the eye with the silicone during processing. The rear surface of the stock eye was indented with an arrow shape around 2-3 mm depth (Figure 4a). While indentation, make sure that the arrow pointing towards the mid-line of the facial moulage. The depth of the arrow will act as orientation notch for the artificial eye and it would not let it allow to move. The arrow pointing towards mid-line is to assure the mediolateral positioning of the eye into the

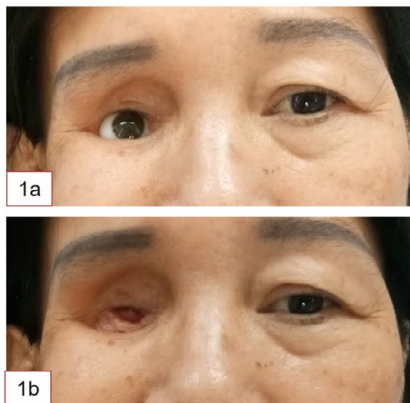


Figure 1: Pre-operative photograph of patient 1.

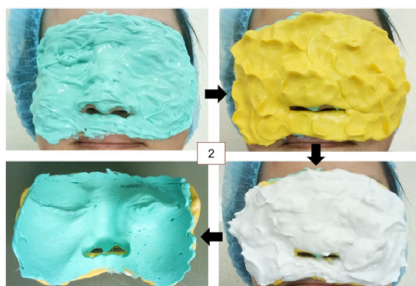


Figure 2: Facial moulage of the patient 1.

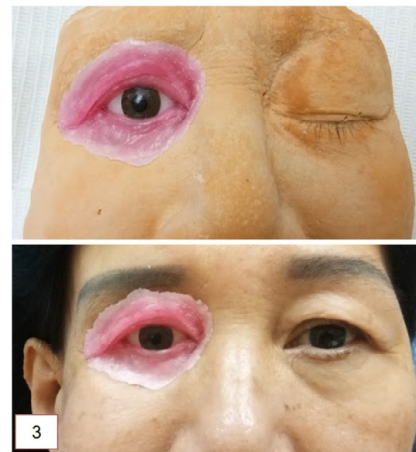

Figure 3: Completed wax-up try-in.

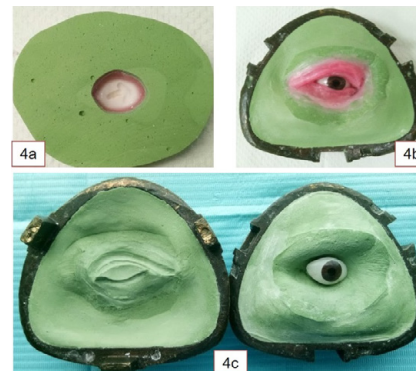


Figure 4: Arrow indentation on the rear side of the eye-shell.

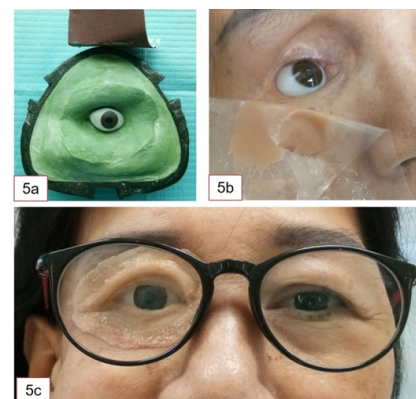


Figure 5: Mold retrieved after dewaxing procedure and final prosthesis in situ for patient 1.

silicone. The flasking and dewaxing procedures were performed (Figure 4b,4c). Now, the mold is ready to pack with the medical-grade silicone but before this, mold around the artificial eye was smoothed with sandpaper for the proper adaptation of the silicone in the patient (Figure 5a). The room- temperature vulcanized silicone A 2000 (Factor II Inc., Lakeside, AZ, USA) was mixed using an intrinsic color kit (Factor II Inc., Lakeside, AZ, USA) to achieve the tone of the natural skin color of the patient (Figure 5b). After the color is successfully matched with the skin tone, it was packed into the mold. The mold was left for curing as per manufacturer's instructions. After complete curing, the prosthesis was retrieved from the mold. The excess flash was cut-off. There was minimal need for the prosthesis to be extrinsically colored. After finishing and polishing, the prosthesis was ready for eyelashes weaving, later on, it was fixed using a medical-grade adhesive (Factor II Inc., Lakeside, AZ, USA) to the patient (Figure 5c). The patient was

highly satisfied with the aesthetics and found it to be comfortable.

Case report 2

An 80 years old female patient suffering from facial disfigurement with the loss of her left eye was referred to the AIMST University Dental Clinic for maxillofacial prostheses. History revealed an exenteration of orbit forty years ago, due to the eradication of squamous cell carcinoma on the left side. The examination of the patient showed shallow defect with no bony undercuts (Figure 6). The treatment planned for the patient was to rehabilitate with the solid orbital prosthesis so that the entire surface area is covered by the prosthesis to achieve sufficient retention. Impression, moulage fabrication, and try-in were performed similarly to the case report 1. An acrylic stem, projecting from the front surface of the eye shell, was fixed using cold cure repair acrylic (Kemdent, Kemdent works, Wiltshire, UK) and used as an indexing method to maintain the integrity of artificial eye and the silicone (Figure 7a). The rear surface of the eye had the same arrow as mentioned in the case of report 1 (Figure 7b); just to assure its orientation in the silicone. During flasking and dewaxing, the acrylic stem will maintain the position of the eye in place and would not let it move from its original position. The mold is ready to pack with silicone and after packing, it was left for curing as per manufacturer's instructions and deflasked (Figure 8a). There was a need for the prosthesis to be extrinsically colored. After finishing and polishing, the prosthesis was ready for eyelashes weaving, later on, it was fixed using medical-grade adhesive to the patient (Figure 8b). The patient was highly satisfied with the look and found it to be comfortable.

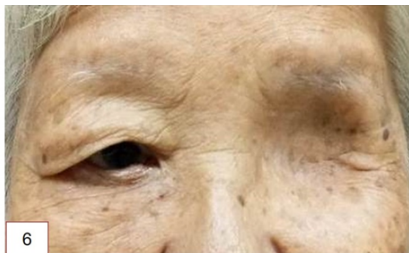

Figure 6: Pre-operative photograph of patient 2.



Figure 7: Acrylic stem projecting from the front surface of the eye shell.

DISCUSSION

Prosthetic rehabilitation is an alternative treatment option for surgical reconstruction for the orbital defects patients. These prostheses a.) simulate the patient's missing structures, b.) have acceptable aesthetic outlook c.) permit hygiene maintenance

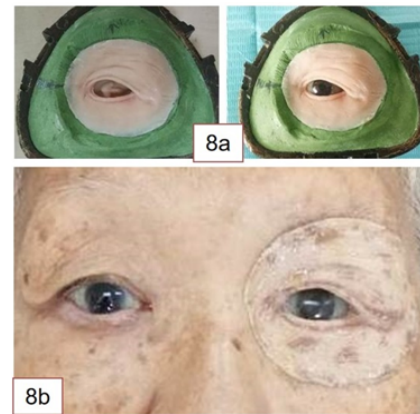


Figure 8: Mold retrieved after dewaxing procedure and final prosthesis in situ for patient 2.

around the defect and d.) observation for tumor recurrence [5]. The most difficult task in fabricating an orbital prosthesis is maintaining the position of the eye shell in the silicone without positional discrepancy during processing. The irony is that most articles published in the literature for prosthetic rehabilitation of orbital defects don't discuss this critical step [6,7]. In the present case report, the author discusses the indexing methods for proper and accurate orientation of the eye shell in the silicone through two case reports, which are simple to use. Kusugal P et al.(2019), used syringe needle cap which was placed above the eye shell and filled with auto cure clear auto polymerizing resin to aid in stabilization [8]. Bindhoo YA et al. (2011) used the posterior indexing method in which, a hole was made through the rear portion of the processing cast through which a needle cap filled with auto polymerizing resin was inserted to contact and index the posterior surface of the eye shell. The auto polymerizing resin once set indexed the eye shell in the correct position [4].

CONCLUSION

In the first case report, an arrow marking on the rear side of the eye shell provides orientation of the eye shell during processing as well as for the operator and patient to know the mediolateral positioning of the eye shell in the silicone. This technique can be used for the cases whereby hollow orbital prosthesis is planned. In the second case report, the combination of the acrylic stem from the front surface of the eye shell and arrow marking on the rear side of the eye shell provides orientation of the eye shell during processing as well as for the operator and patient to know the mediolateral positioning of the eye shell in the silicone. This technique can be used for the cases whereby solid orbital prosthesis is planned. Both techniques are easy to use and cost-effective for achieving an exceptional outcome.

DECLARATION OF CONFLICT OF INTERESTS

The author's declare that there is no conflict of interest.

REFERENCES

1. Mueller S, Hohlweg-Majert B, Buegers R. The functional and aesthetic reconstruction of midfacial and orbital defects by combining free flap transfer and craniofacial prosthesis. *Clin Oral Investig*. 2015; 19(2):413-419.
2. Beumer J, Curtis TA, Marunik MT. *Maxillofacial Rehabilitation: Prosthodontic and Surgical Consideration*. St. Louis: Ishiyaku Euro America. 1996:240-285.

3. Wolfaardt J, Gehl G, Farmand M, Wilkes G. Indications and methods of care for aspects of extraoralosseous integration. *Int J Oral Maxillofac Surg.* 2003; 32(2):124-131.
4. Bindhoo YA, Aruna U. Prosthetic Rehabilitation of an Orbital Defect: A Case Report. *J Indian Prosthodont Soc.* 2011; 11(4):258-264.
5. Taylor TD. *Clinical maxillofacial prosthetics.* Illinois: Quintessence. 2000:233-276.
6. Jamayet NB, Rahman AM, Nizami MU, Johari Y, Husein A. Combination of skin flap and silicone prosthesis for rehabilitation of a large orbital defect: A case report. *Indian J Dent Res.* 2018;29(6):840-843.
7. Shetty S, Mohammad F, Shetty R, Shenoy K. Prosthetic rehabilitation of an orbital defect for a patient with hemifacial atrophy. *J Indian Prosthodont Soc.* 2016(1);16:91-95.
8. Kusugal P, Kalaivani VN, Patil V, Sivakumar V. Prosthetic rehabilitation of an orbital defect: A clinical report. *J Interdiscip Dentistry.* 2019;9(3):135-138.