

Not Only Diabetic Retinopathy - Retinal Vascular Lesions and Signs in Diabetic Patients: Description and Associations

Janne P. Kytö^{1,2*}, Maritta Lindström-Karjalainen^{1,3} and Paula A. Summanen^{1,4}

¹Department of Ophthalmology, Helsinki University Central Hospital, Finland

²Folkhälsan Institute of Genetics, Folkhälsan Research Center, University of Helsinki, Finland

³Department of Oncology, Helsinki University Central Hospital, Finland

⁴Photographic Screening Unit, Herltoniemi Hospital, City of Helsinki, Finland

Abstract

Retinal vascular changes other than diabetic retinopathy (DRP) namely microaneurysms, intraretinal microvascular abnormalities so called IRMA, microinfarctions, hemorrhages, lipid exudates and edema, as well as venous beading and new vessels (NV) on the disk and/or on the retina and their sequelae pre-retinal and vitreous hemorrhages and fibrovascular proliferations and vitreoretinal tractions are common in diabetic patients. These changes are general or focal arteriolar narrowing or arteriolar or venous dilatation, arteriolar sinusoidal elongation or straightening, venous tortuosity, increased arteriolar wall reflex and arterio-venous crossing signs. They reflect cumulative response to aging, cardiovascular risk factors such as hyperglycemia, hypertension and dyslipidemia, as well as inflammation and endothelial dysfunction. Retinal vascular changes are under the influence of both systemic and environmental as well as genetic factors and serve as cardiovascular risk stratification indicator. Furthermore, these changes may cause as such ocular morbidity and threaten vision and influence the occurrence and progression of DRP. Many of these changes were recognized soon after the invention of ophthalmoscope by von Helmholtz in 1851 and have since been described in literature. Many of these changes can be accurately measured today.

Retinal Blood Flow: Anatomy and Physiology

The blood supply to the orbit arises primarily from the ophthalmic artery, the first and the only branch of the internal carotid artery outside the cranium. Smaller vascular contributions come from the external carotid artery via the internal maxillary artery and facial arteries. The major branches of the ophthalmic artery include branches to the extraocular muscles, the central retinal artery and the long and short posterior ciliary arteries. The central retinal artery branches off the ophthalmic artery to penetrate the optic nerve approximately 10 to 15mm behind the globe [1]. The central retinal artery courses adjacent to the central retinal vein within the optic nerve and within the globe, where it branches into four major trunks, each of which supplies a quadrant of the retina. The central retinal artery is an end artery that has no significant anastomoses. In up to 30% of people, one or more cilioretinal arteries may be present. It emerges from the temporal aspect of the optic nerve, extending laterally along the papillomacular bundle and supply a variably sized region of the retina. Since it is a direct branch of the ciliary or choroidal arteries, on fluorescein angiography it fills in the choroidal phase, before the central retinal artery. In the area of the lamina cribrosa, the lumen of the central retinal artery measures about 170µm in diameter [2]. The central retinal artery supplies the inner two-thirds of the retina, the most anterior portion of the optic nerve head, and to some extent the retrolaminar optic nerve. The deeper outer layers of retina, including photoreceptors and bipolar cells, are nourished by the uveal system, specifically the capillaries of the choroid called the choriocapillaris which are fenestrated to allow free diffusion of molecules [1]. The retinal pigment epithelium (RPE), a one cell layer, which separates the retina from the choroid, actively transports metabolites and waste to and from the deep layers of the retina to the choroid. The larger blood vessels lie within the nerve fiber and ganglion cell layer of the innermost portion of the retina. Smaller vessels, precapillary arterioles, postcapillary venules and capillaries are found between the nerve fiber and inner nuclear layers [2]. Retinal venous drainage occurs via the central retinal vein which drains into the superior ophthalmic vein or, rarely, directly into the cavernous sinus [1]. In youth, the retinal arteries are wide in caliber and rich in

hue. They course in wide sinuous curves over the fundus, branching at moderately wide angles, and have walls which are not visible [3]. In a normal retina, there are no arteriovenous shunts. The average number of foveal arterioles and venules is 16 [4]. Even if two similar vessels branch off very closely from a perifoveal arteriole or venule, a dissimilar vessel interposes itself between the two a brief distance after its origin, maintaining the correct sequence of arterioles: venules toward the foveola.

A true artery possesses an internal elastic lamina and a well-developed muscular coat, while an arteriole has no elastic lamina and the muscle layer is not continuous. The retinal arterial tree is arteriolar in nature except for the main central artery and some of its large branches near the disk [5]. Thus it begins to show marked alteration in its structure after passing through the lamina cribrosa of the sclera: the internal elastic lamina becomes rapidly reduced in thickness and disappears entirely at the first or second bifurcation, the muscular coat becomes thin and the muscle fibers lose continuity, and become separated from one another by small gaps [5]. By the first or second bifurcation, the retinal arterial tree has become arteriolar in nature. Branches of the central retinal artery near the disk have a luminal diameter of about 120µm and possess three to six layers of muscle cells in their walls [6]. The lumen is lined by a single layer of endothelial

*Corresponding author: Janne Kytö, MD, Department of Ophthalmology, Helsinki University Central Hospital, P.O. Box 220, FI-00029 HUS, Helsinki, Finland, Tel: +358505810384; E-mail: janne.kyto@helsinki.fi

Received November 23, 2011; Accepted January 15, 2012; Published January 20, 2012

Citation: Kytö JP, Lindström-Karjalainen M, Summanen PA (2012) Not Only Diabetic Retinopathy - Retinal Vascular Lesions and Signs in Diabetic Patients: Description and Associations. J Diabetes Metab S3:003. doi:10.4172/2155-6156.S3-003

Copyright: © 2012 Kytö JP, et al. This is an open-access article distributed under the terms of the Creative Commons Attribution License, which permits unrestricted use, distribution, and reproduction in any medium, provided the original author and source are credited.

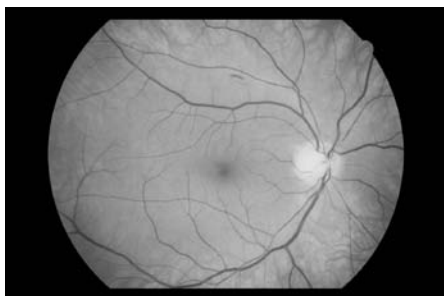


Figure 1: Retinal vascular remodeling. A male aged 52 years with recently diagnosed type 2 diabetes and hypertension for more than 10 years. Fundus image shows microaneurysms, one intraretinal hemorrhage, marked general and focal arteriolar narrowing, arteriovenous nickings. Venules dilated. Arteriolar sclerosis and grade 3 hypertensive retinopathy and or mild diabetic retinopathy.

cells which run parallel to the axis of the vessels [6]. Near the disk, the retinal veins are 150-200 μm in diameter [2,7]. The retinal capillary bed consists of vessels with a diameter varying from 15 to 150 μm arranged in two layers except in three in the radial peripapillary area, and a single layer in the perifoveal region around the foveal avascular zone and the peripheral retina [2]. Capillaries consist of one layer of endothelial cells and a surrounding layer of pericytes and the basal membrane [7]. The pericyte: endothelial ratio in the retina is 1:1, which is high compared with elsewhere in the central nervous system or body in general. Healthy capillaries are not visible in fundus photography without e.g. fluorescein.

The inner and outer blood-retinal barriers composed of the tight junctions of the vascular endothelium and RPE and to some extent of the basal membrane form the barriers, restrict intercellular movement of all water-soluble molecules and thus prevent these molecules from entering the retina with minimal extracellular space [7].

Ocular and optic nerve head blood flow is directly related to perfusion pressure and inversely related to the resistance to flow i.e. intraocular pressure. Autoregulation maintains a constant ocular blood flow -within normal limits - to tissues during changes in perfusion pressure [8]. Compared to the choroidal circulation (a high-flow, variable-rate system), the retinal circulation is a lower flow, constant-rate system supplying highly metabolically active tissue. The choroid receives 85% of the ocular circulation, compared to 15% to the retinal circulation. The autonomic nervous system controls vascular resistance in the choroid. Sympathetic nerves provide most of the regulation through the cranial cervical ganglion, involving neuropeptide Y and provoking vasoconstriction when stimulated. The parasympathetic system mediates poorly defined control. The autonomic nervous system contributes to retinobulbar and choroidal circulatory regulation, but it ends at the lamina cribrosa. Although retinal and optic nerve head vessels have alpha-adrenergic, beta-adrenergic, and cholinergic receptors, the role of these receptors in vascular control remains unclear. Consequently, retinal blood flow is autoregulated locally in response to variable blood oxygen content, with capillary recruitment and derecruitment providing oxygen delivery. Arterioles dilate when oxygen tension falls, for example when retinal capillaries become nonperfused [9-11]. Several soluble vasoactive molecules mediate retinal vascular autoregulation, including endothelial-derived nitric oxide (NO), endothelins (ETs), superoxide anions, renin-angiotensin, and vascular endothelial growth factor (VEGF). NO is produced by two endothelial enzymes, constitutive nitric oxide synthase (membrane

bound) and inducible nitric oxide synthase (cytosolic), both of which oxidize L-arginine to produce NO. Endothelial cell NO diffuses to the pericyte or smooth muscle cell surface, where it binds to guanylate cyclase, causing intracellular cGMP accumulation and vasodilation. NO production is directly stimulated by increased local shear force, bradykinins, insulin-like growth factor 1, acetylcholine, thrombin, and various platelet products. In addition to its vasodilatory actions, NO protects vessels by inhibiting platelet aggregation, platelet granule secretion, leukocyte adhesion, and possibly smooth muscle cell proliferation. ETs, are released by endothelial cells and bind to receptors on adjacent pericytes and smooth muscle cells. ET-1, ET-2, and ET-3, each with 21 amino acids, are the most potent vasoconstrictor agents currently known. Endothelin-dependent contraction is mediated by three receptor subtypes (ETR-A, ETR-B, and ETR-C). In addition to NO and ETs, superoxide anions play a role in retinal microvascular autoregulation. Superoxide anions inactivate NO, thereby inhibiting vasodilatory capacity. The vascular endothelium generates basal levels of superoxide anions and can be stimulated to produce deleterious amounts of these molecules during many pathologic conditions. Another component of the retinal microvascular autoregulatory system is the renin-angiotensin pathway. Angiotensin -converting enzyme (ACE) on the luminal endothelial cell surface rapidly converts angiotensin I to angiotensin II and ACE inactivates bradykinin. Angiotensin II stimulates retinal vasoconstriction via smooth muscle cells and pericytes [12].

Diabetic Retinopathy

Microaneurysms are the hallmark of DRP and often the first changes detected in either clinical examination or photographic screening of diabetic patients. In addition to intraretinal hemorrhages, lipid exudates and retinal edema, retinal microinfarctions, IRMA as well as venous beading they occur in various combinations and increase in number and disappear over the years. They result either from vascular leakage or from vaso-occlusion or both and may as such cause visual disturbance, namely macular edema which is the most common cause of visual impairment among diabetic patients. As the vaso-occlusion advances, NVs start to grow either from the venules or IRMA-areas towards the vaso-occlusion as VEGF causes the endothelial cells to proliferate and sprout and form new tubes through the cytokine induced break down of the basal membrane. Grading of non-proliferative retinopathy according to the classification of Early Treatment of Diabetic Retinopathy Study (ETDRS) helps to predict the onset of proliferative retinopathy and thus to plan laser treatment in the phase of severe non-proliferative retinopathy [13].

Changes in Arterioles

General arteriolar narrowing

Reduction in arteriolar caliber is called general arteriolar narrowing [14]. Arterioles and their branches i.e. the whole arterial tree appears narrow. Retinal arteriolar caliber becomes narrower with aging [15]. Thus, this is a common finding in elderly individuals. So called involution arteriosclerosis is almost universal and can be regarded to represent a normal fundus in old age. However, it shows a great variation from person to person. Arteriolar diameter has been expressed as arteriovenous ratio (AVR), normal AVR being 2/3. AVR as assessed from digital images is slightly higher, namely 0.84 [16]. Not surprisingly AVR has been found not to represent arteriolar narrowing accurately, since venous diameter affects the estimate [17]. Since retinal arteriolar and venular caliber seems to reflect different pathophysiology and systemic conditions, combining these two components into

AVR is not recommended, but rather to present the two separate measurements [17].

Already Friedenwald (1931) [14] stated that when the arteries are reduced to approximately one-half of their normal caliber, the diastolic blood-pressure will be 110mmHg or more [14]. Recent epidemiological studies including quantitative measurements of retinal vessel caliber have shown that narrower retinal arteriolar caliber is associated in addition to older age with higher levels of both past, current and future blood pressure as well as obesity [17]. Furthermore, general arteriolar narrowing predicts the incidence of diabetes and coronary heart disease [17]. Association with the latter was stronger in women than men. Individuals with a smaller AVR tend to have more white matter lesions, cerebral infarcts in magnetic resonance imaging and increased risk of incident clinical stroke [17]. A smaller AVR has also been shown to be associated with a greater change in serum creatinine level but not to the development of renal insufficiency [17]. Alcohol consumption has been associated with smaller AVR and smaller retinal arterioles in some studies [17] as well current estrogen replacement therapy with narrower retinal arterioles and venules independent of blood pressure and other vascular risk factors [17]. However, this finding seems to be influenced by the duration of hormone-replacement therapy, as women receiving this medication for longer than 10 years did not have narrower retinal arterioles. Combined use of aspirin and antihypertensive medication has also been shown to be associated with wider retinal arteriolar caliber, an effect possibly reflecting the anti-inflammatory effect of aspirin.

Sudden rise of blood pressure may cause narrowing of the retinal and choroidal arterioles due to vasospasm. On the other hand chronic hypertension leads to arteriosclerotic changes i.e. intimal thickening, media-wall hyperplasia and hyaline degeneration and thus to thickening of the arteriolar walls with luminal narrowing visible as general and focal arteriolar narrowing, increased arterial wall reflex and arteriovenous nicking. Arteriosclerotic changes due to aging modify the outcome [18]. In severe hypertension, arteriolar thickening in the choroidal vessels is more severe than in retinal arterioles and more closely resembles systemic arterial changes [19]. Focal occlusion of choriocapillaris leads to necrosis of RPE leading to a patchy yellow area, later with a pigmented center and a hypopigmented halo called Elschnig's spot [20]. In advanced hypertension only small segments or no arterioles at all are visible and thus predominantly venules remain visible. This is best seen in the vicinity of the fovea where arterioles seem to terminate at a greater distance than usual from the fovea (fovea hypertonica) [4,21].

Acute hypertension may cause disruption of the blood-retinal barriers leading to retinal edema, lipid exudation and intraretinal hemorrhages, findings similar to those seen in DRP. However, hemorrhages are typically located in the nerve fiber layer and often appear wedge shaped. Microaneurysms, the hallmark of DRP, are less common. Furthermore, deposition of lipids around the fovea in the outer plexiform layer appears as a star (so called macular star).

Hypertensive retinopathy represents a target organ damage described by Liebreich in 1859: a patient with central retinal vein occlusion [22]. Various fundus changes may be divided into three categories: hypertensive retinopathy, hypertensive choroidopathy and hypertensive optic neuropathy. Hypertensive retinopathy appears earlier and is the most common [8]. Vasospasm due to sudden high blood pressure has been an explanation of generalized reduction of caliber, and of localized constrictions of the arteries as well as of transient attacks of blindness [13] which may still occur in e.g. pre-

eclampsia [23]. Keith, Wagener and Barker (1939) proposed the first classification of hypertensive retinopathy and described the association between the retinal arteriolar changes and survival [24]. This classification is still used after minor modifications [25]. The first two grades include general and focal narrowing and the third in addition extravascular changes mentioned earlier and the fourth, optic disk edema. Today, disk edema is not any more associated with increased mortality when adequate medication is available [26].

Focal arteriolar narrowing

Gunn (1898) described that apparently normal size or generally narrowed arterioles may have stretches which seemed to have contracted and continue very narrow for some distance broadening again to its original breadth [27]. Focal arteriolar narrowing is considered definite if an arteriole estimated to be $\geq 50\mu\text{m}$ in diameter has a constricted area of two thirds or less the width of proximal and distal vessel segments [28]. In the peripapillary region with the highest density of nerve fibers, the sinking of an arteriole into the nerve fibers may mimic local narrowing. Furthermore, arterioles tend to be slightly narrowed on their crest or bottom of sinusoidal wave.

Raehlmann described proliferation of the intima, protruding into the lumen of the vessel often in the form of a small mound [14]. The varying - gradual or abrupt, single or multiple, and occupying short or long stretches, irregularly distributed narrowings chiefly in the larger first and second order branches of the retinal artery near arterial divisions, are called atheromas. Today, atheroma and medial calcification is not considered to occur in the retinal arteriolar tree, except in the vicinity of the optic disk where they would cause focal arteriolar narrowing [5].

In both general and focal arterial narrowing fibrinoid degeneration, fibrous thickening, fibro-hyalinoid thickening, and hyalinoid thickening occur in the arterial wall [29]. These changes resemble those found in intracerebral arterioles in patients with cerebrovascular disease. Arteriolar changes near the optic disk are associated with increased risk of cerebral hemorrhage and infarction [29]. Recently, focal arteriolar narrowing has been associated with hypertension [16] and cardiovascular morbidity and mortality [30].

Arteriolar dilatation

Arterioles may be dilated as caused by retinal capillary non-perfusion which leads to tissue hypoxia and autoregulatory dilatation of arterioles [9]. Arteriolar dilatation decreases the resistance to flow, creating a decreased pressure fall in the arterioles with a consequent increased hydrostatic pressure in the capillaries and venules [9,10]. Law of Poiseuille: $\Delta P = Q8hl/pr^4$, where ΔP is the pressure fall in vessel, Q is the blood flow, h is the blood viscosity, l the vessel length and r the vessel radius [9,10]. Increased vascular hydrostatic pressure leads to increased flow of fluid from the intravascular compartment into the interstitial tissue compartment according to Starling's law: $\Delta P - \Delta Q = 0$, where ΔP is the vascular transmural difference in hydrostatic pressure, ΔQ oncotic pressure difference between the interstitial matter and blood [9,10]. As the hydrostatic pressure within the capillaries and venules rises, the diameter of the vessels increases according to the law of Laplace: $T = \Delta Pr/e$, where T is the wall tension of the vessel, ΔP constitutes the transmural pressure difference, r is the vessel radius and e relates to the wall thickness and elasticity [9,10]. While in some studies smoking has been associated with lower AVR, in some it has been associated with larger arteriolar as well as venular calibers, the effect being greater on venules [17].

Focal arteriolar dilatation

Focal dilatation of the precapillary retinal arterioles may occur due to the autoregulatory disturbance resulting in abnormal permeability of the dilated segment to macromolecules into the wall of distended arteriolar segments, and into the adjacent retinal tissue [31]. This leads to focal accumulation of the plasmatic deposits in the retinal tissue giving rise to the ophthalmoscopically visible whitish at first pinpoint lesions that fuse together to form larger spots [31]. According to Hayreh et al. (1986) [31] as precapillary retinal arterioles lie in the retinal layers deeper than the nerve fiber layer this explains the location the focal intraretinal periarteriolar transudate in the deeper layers of the retina [31].

Arteriolar sinusoidal elongation

As the arteries increase in length, as well as thickness, they become increasingly tortuous [5] which is called sinusoidal elongation. An increased transmural pressure in a passive tube leads to an increase in the diameter and the length of the tube, causing tortuosity [9,10]. The fullness and tortuosity of the larger retinal arteriolar branches are associated with arteriolosclerosis [32].

Arteriolar tortuosity was first described by Gunn (1898). It may be a generalized finding or best seen in the small arterioles of the macular region called Salus sign [5,14]. It is not uncommon to meet with an excess of smooth curve tortuosity merely as a congenital condition. Gauss estimated that 15% of people have some congenital tortuosity of the arterioles and 6% of both arteries and veins [33]. Friedenwald (1931) [14] described it in congested fundi in patients with fever and eye-strain.

Arteriolar straightening

In elderly persons, retinal arterioles in involution sclerosis may either be tortuous or relatively straight [3]. Furthermore, the color of the blood column is diminished in intensity. Friedenwald (1931) [14] emphasized that hypertension but not aging caused straightening and arteriolar caliber variation. The straightness of the retinal arteries and their tendency to branch at acute angles are due to a longitudinal shrinkage in the central vessel, which draws the branches to the first and second order into the disk [14].

Changes in arteriolar branching

Chronic hypertension may cause disadvantageous branching geometry in the retinal vasculature, with reduced circulatory efficiency and microvascular rarefaction. Measurements of bifurcation angles and retinal arteriolar diameters in response to acute hyperoxic and hypercapnic stress have demonstrated diminished vascular reactivity.

Increased arteriolar wall reflex

Light streak is an increased wall reflex seen from arterioles. The secondary and tertiary branches of the central retinal artery are mainly affected. Some branches show it more markedly than others in an eye. The normal arterial reflex stripes originate on the anterior surfaces of the blood column [4]. It is affected by diameter and smoothness of the reflecting surfaces and the transparency of the overlying tissues [14]. Also the size of the pupil and the construction of the ophthalmoscope or camera influence the reflection from the convex cylindrical surfaces of the vessel wall.

Gunn (1898)[27] described increased wall reflex as that the entire breadth of such arterioles seems abnormally light in color, as if there

was an unusual reflection from their coats, and not merely an increased brightness of the central streak [27]. This gives the impression of unusual fullness and roundness of the contour of the arteriole. Sometimes this bright line is not uniform, but a series of brighter points at intervals [27]. Friedenwald (1931) [14] noted further the irregularity of the arterial reflex with spots of increased brightness to be associated with fine irregularities in the arteriolar caliber, called beading. In extreme constriction of the arterioles, the light streak may disappear entirely [14].

The increased arteriolar light reflex correlates with hyalinisation of the arteriolar wall. Hyaline material, often with considerable lipid, first is deposited just outside the endothelium. As the disease progresses, the muscularis becomes involved, and finally the entire thickness of the vessel wall. The arteriole becomes rigid and contractile power is diminished or lost [5]. In the pathophysiological changes of the vessel wall, the lamellar arrangement of the basement membrane substances and collagen fibers are an important factor for the vessel reflexes. Increased arterial wall reflex is associated with blood pressure, serum glucose as well as alcohol consumption [35].

When the arteries have an exceptionally bright reflex and the vessel has a metallic appearance like what would be presented by bright burnished copper wire it is called copper wire artery. The central light streak is very distinct and sharp, while the whole surface of the vessel is of a lighter color than usual [34] and the light reflex occupies most of the surface of the vessel [5]. In the extreme form of arteriolar sclerosis the vessel wall is so thickened, as a result of hyalinization and lipid infiltration, that the vessel wall obscures the blood column entirely which is called silver wire artery [5]. The artery appears as a white cord, even though blood is still circulating through it [5]. Very narrow arteries may be entirely occluded.

Macroaneurysm

Macroaneurysm is an acquired focal aneurysmal dilatation of an arteriole, usually occurring in the first three orders of the arteriolar tree and giving rise to star-shaped exudation and sometimes complicated by preretinal or intravitreal hemorrhage and macular edema when located in the temporal side. It may mimic wet age related macular degeneration. Spontaneous resolution with thrombosis within the macroaneurysm may occur. Its most common risk factors are aging and hypertension [36].

Arteriolar sheathing

Arteriolar walls that are partially opaque but a ribbon of blood can still be seen or with white lines on one or both sides of it are called arterial sheathing [37]. Silver-white lines of the arterioles on both sides of the vessel represent the proliferation of the perivascular glial cells that overlay the vessels as shown by electron microscope. These changes may be found in patients with advanced DRP, often years after panretinal photocoagulation.

Changes in Venules

General venular dilatation

Venules appear generally dilated. This may be caused either by impaired venous drainage or by increased blood flow in the retina. General venular dilatation is associated with younger age, impaired fasting glucose and diabetes, dyslipidemia, obesity, systemic markers of inflammation (e.g. higher white blood cell counts, erythrocyte counting rate and C-reactive protein) and cigarette smoking [17]. Association

with endothelial dysfunction has been less consistent. In some studies larger retinal venular caliber has been associated with an increased risk of clinical stroke, and sub-clinical changes such as cerebral infarction, MRI-defined white matter lesions and lacunar infarctions [17]. Furthermore, larger venular caliber predicts nephropathy in both type 1 and type 2 diabetes. Larger arteriolar and venular calibers have been found to be associated with smoking, the effect being greater on venules [17].

In hyperglycemia, increased retinal blood flow and vasodilation occur and appears as generally dilated venules. On the contrary, venous changes due to ischemia associated with capillary dropout which leads to a focal dilatation of adjacent venous segments resembling a string of beads is called venous beading [37]. Venous beading, an essential element of DRP together with IRMA and numerous microaneurysms and hemorrhages reflects permanent vaso-occlusion. Venous beading of these three changes has the strongest predictive value for occurrence of proliferative changes and thus has a central role in the classification of the severity of DRP [13].

Both retinal arteriolar and venular dilatation in diabetic subjects has been reported to be associated with incidence and progression of DRP. Furthermore, normalization of the caliber of venules is seen after improvement of blood sugar control as well as successful treatment of macular edema and proliferative retinopathy by laser or i.e. corticosteroids [38].

Localized venular narrowing

In the peripapillary region with the highest density of nerve fibers, the sinking of venule similar to that of an arteriole into the nerve fibers may mimic slight local narrowing as well as the venules may tend to be slightly narrowed on their crest or bottom of the sinusoidal waves which is neither a true focal venular narrowing. The etiology of a single localized venular narrowing is not known neither is its predictive value as clear as that of the focal arteriolar narrowing.

Venous tortuosity

Changes in configuration i.e. tortuosity of venules are not uncommon. Venous tortuosity may affect the main branches or smaller venules. Venous tortuosity in the macular area causing venules to appear zig-zag like, is called Guist sign [18]. Venous tortuosity may also occur as an isolated normal variant or as a congenital phenomenon which Gauss estimated to occur in 8% [33]. However, similar to arteriolar tortuosity, it may follow the increase in transmural pressure in venous circulation following dilatation and an increase in the diameter and the length of the venules. This occurs in hyperglycemia but especially in venous circulatory disturbances i.e. central retinal vein occlusion and hemi- and branch retinal vein occlusion. Furthermore, dilated and tortuous retinal veins may occur associated with blood dyscrasias e.g. polycythemia vera, lymphoma, leukemia, and sickle cell disease due to both widespread fundus ischemia and hyperviscosity [33].

Venous sheathing and perivenous exudates

White streaks or lines sometimes seen along the borders of the venules are due to the presence of wandering cells in the perivascular spaces, carrying off the detritus from retinal degeneration secondary to arterial disease [14]. It is called sheathing. The complete opacification of venous wall appearing as white threads may occur [37]. Hard exudates occurring immediately adjacent to one or both sides of retinal veins, simulating venous sheathing, are classified as perivenous exudates [37].

Arteriovenous Changes

Arterio-venous crossing sign

Arteriovenous crossing is a site where an artery, even its small branch, passes over a vein [34]. In health the underlying venule is dimly traceable underneath the arteriole. In histological findings, both the arteriole and the venule first run in the nerve fiber layer. Immediately before touching the arteriole, the venule dips down into the outer plexiform or outer nuclear layers [2]. Because of the common vascular adventitial sheath at the arteriovenous crossing sites, arterioles especially when sclerotic and with thickened walls reduce the internal caliber of the venules and tend to compress them. This may impair the venular circulation. When on the contrary the venule lies on the vitreous side of the arteriole at the crossing the venule may assume the appearance of an arch or a hump over a sclerotic arteriole due to vertical deflection [5]. This is called humping of a venule.

Arteriovenous crossing sign or nicking constitutes of local narrowing, banking and deflection or arching of the underlying venule. At first, the vein loses its central light streak on either side of the crossing, then the column of blood in the venule appear tapered on each side of the arteriovenous crossing because of compression [27,34]. In more advanced cases, the venule appears tapered as hourglass or the column of blood in the venule vanishes on each side of the arteriole [5]. The constrictions of the veins persist even when the blood pressure falls to normal because of structural changes in the vessel walls [39]. As at the crossing site the venous blood flow is impeded the venule becomes distended for some distance peripheral to the crossing site which is called distal dilatation, banking, Gunn's sign or Bonnet's sign [34]. Hemorrhages from a venule thus distended with blood are not uncommon as already described by Gunn (1892) [34].

The venule may also be displaced in direction of the arterial circulation [27] resulting in three dimensional: lateral, vertical and anteroposterior deflection of a venule from its normal course [5]. The points of crossing have been shifted laterally by the tortuous arterioles, or the arterial tree has shrunk longitudinally dragging the points of crossing toward the disk [14]. An apparent displacement of the underlying venule by the refraction of the overlying arterial coat is seen when the arteriole is thickened, the retinal surface over the arteriole is raised and sharply curved, the venule is a narrow one and the vessels cross at acute angles [14].

The arch or so called arching sign formed by the venule extends some part of vessel width to one side at the point of the arteriovenous crossing to return in its original direction [4]. The arteriole appears at approximately the center of the arch.

Degree of circulatory disturbance at the arteriovenous crossing-site depends on the compression, banking, as well as deviation or arching of the vein. Scheie's classification of arteriolosclerosis is based on the degree of the arteriovenous nickings and changes in the arteriolar wall reflex [5].

Thickening of the arterial wall within the space circumscribed by the common adventitia reduces the internal caliber of the vein. The sclerotic arterial wall penetrates into the wall of the venule, causing a phlebosclerosis. Thrombosis of the venous branches (i.e. branch retinal vein occlusion) rarely occurs except as a result of arteriovenous crossing sign [14]. Most often the superior temporal vein branch is occluded [14]. The pathological vascular crossing is caused by proliferation of the perivascular glial cells and swelling of the nerve fibers [6]. Nasal and sometimes even temporal branch retinal vein occlusion may remain

asymptomatic unless retinal neovascularization occurs and causes vitreous hemorrhage or preretinal fibrosis and traction to the retina.

Similar to general arteriolar narrowing, arteriovenous crossing sign has been found to be associated with hypertension [16], obesity, inflammation, endothelial dysfunction and smoking [40] and cerebro- and cardiovascular morbidity and mortality [30].

Arterio-venous anastomosis

Dilated and often slightly tortuous arteriolar and venous branches occur due to shunting of circulating blood directly from arteriolar side to the venular side due to capillary occlusion is called arterio-venous anastomosis. They occur after central or branch retinal vein occlusions. These changes may sometimes cause differential diagnosis problems whether they are IRMA or NV.

Conclusion

The retinal blood vessels are accessible for detailed visualization in a noninvasive manner during clinical examination of the ocular fundus and in conjunction to assessment of the ocular fundus while screening for the presence and severity of DRP. Architectural changes in the retinal vascular network reflect the state of the human microcirculation and may reveal pathological features. Recent measurements of retinal vascular caliber, in particular, have confirmed the earlier studies about the prognostic value of these changes [41]. Recognition of retinal vascular changes and recording them even without measurements is valuable. Many changes can be measured from digital images to gain quantitative data. Changes in the retinal arterioles include general or focal narrowing or dilatation, tortuosity i.e. sinusoidal elongation as well as increased arteriolar wall reflex including copper or silver wire arteries; and those in the retinal venules likewise dilatation, local narrowing and tortuosity overall or in the macular area. The presence and severity of the arteriovenous nickings can be assessed by grading the severity of compression, banking and deflection or arching. Relationship between the retinal vascular changes and DRP is manifold, some changes especially venous dilatation are obvious risk factors and indicators of DRP, while others may not e.g. slight narrowing of the arterioles. Practical classification of various retinal vascular changes as well as computer program for their quick quantitative assessment (e.g. AVR, arteriolar and venular diameter equivalents as well as aspects of tortuosity and branches) would be valuable for better utilization of their information and to discover further factors e.g. genetic ones influencing them.

Grants

The study was supported by grants from the Eye Foundation Finland, the Finnish Medical Foundation, the Folkhälsan Research Foundation, Kyllikki ja Uolevi Lehtikoinen Foundation, Mary and Georg C. Ehrnrooth Foundation, Ella and Georg C. Ehrnrooth Foundation and the Finnish Cultural Foundation.

References

- Harris A, Jonescu-Cuypers CP, Kagemann L, Ciulla TA, Kriegelstein GK (2003) Ocular vascular anatomy. In: Atlas of ocular blood flow - Vascular anatomy, pathophysiology and metabolism. Butterworth Heinemann, Pennsylvania, USA: 1-17.
- Wise GN, Dollery C T, Henkind P (eds) (1971) The Retinal Circulation. Harper & Row Publishers
- Leishman R (1957) The eye in general vascular disease: hypertension and arteriosclerosis. *Br J Ophthalmol* 41: 641-701.
- Salus R (1958) A contribution to the diagnosis of arteriosclerosis and hypertension. *Am J Ophthalmol* 45: 81-92.
- Scheie HG (1953) Evaluation of ophthalmoscopic changes of hypertension and arteriolar sclerosis. *AMA Arch Ophthalmol* 49: 117-138.
- Kimura T (1974) Arteriolar sclerosis of the human retina. *Eye Ear Nose Throat Mon* 53: 134-137.
- Roh S, Weiter JJ (2004) Retinal and choroidal circulation. In: M. Yanoff, J. S. Duker (eds) *Ophthalmology*. Mosby, MO, USA: pp 779-782.
- Hayreh SS (1989) Classification of hypertensive fundus changes and their order of appearance. *Ophthalmologica* 198: 247-260.
- Kristinsson JK (1997) Retinal vessel dilatation and elongation in diabetic macular edema. *Acta Ophthalmol Scand* 75: 52-60.
- Kristinsson JK, Gottfredsdottir MS, Stefansson E (1997) Retinal vessel dilatation and elongation precedes diabetic macular oedema. *Br J Ophthalmol* 81: 274-278.
- Kristinsson JK (1997) Diabetic retinopathy. Screening and prevention of blindness. A doctoral thesis. *Acta Ophthalmol Scand Suppl*: 1-76.
- Chakravarthy U, Gardiner TA (1999) Endothelium-derived agents in pericyte function/dysfunction. *Prog Retin Eye Res* 18: 511-527.
- Davis MD, Fisher MR, Gangnon RE, Barton F, Aiello LM, et al. (1998) Risk factors for high-risk proliferative diabetic retinopathy and severe visual loss: Early Treatment Diabetic Retinopathy Study Report #18. *Invest Ophthalmol Vis Sci* 39: 233-252.
- Friedenwald H (1931) The Doyné Memorial Lecture: Pathological changes in the retinal blood-vessels in arterio-sclerosis and hypertension. *Trans Ophth Soc U K* 50: 452-531.
- Leung H, Wang JJ, Rochtchina E, Tan AG, Wong TY, et al. (2003) Relationships between age, blood pressure, and retinal vessel diameters in an older population. *Invest Ophthalmol Vis Sci* 44: 2900-2904.
- Hubbard LD, Brothers RJ, King WN, Clegg LX, Klein R, et al. (1999) Methods for evaluation of retinal microvascular abnormalities associated with hypertension/sclerosis in the Atherosclerosis Risk in Communities Study. *Ophthalmology* 106: 2269-2280.
- Sun C, Wang JJ, Mackey DA, Wong TY (2009) Retinal vascular caliber: systemic, environmental, and genetic associations. *Surv Ophthalmol* 54: 74-95.
- Wong TY, Klein R, Klein BE, Tielsch JM, Hubbard L, et al. (2001) Retinal microvascular abnormalities and their relationship with hypertension, cardiovascular disease, and mortality. *Surv Ophthalmol* 46: 59-80.
- Rogers AH (2004) Hypertensive retinopathy. In: M. Yanoff, J. S. Duker (eds) *Ophthalmology*. Mosby, MO, USA: pp 849-853.
- Tso MO, Jampol LM (1982) Pathophysiology of hypertensive retinopathy. *Ophthalmology* 89: 1132-1145.
- Salus R (1939) Das Gefßsystem der fovea centralis. *Acta Ophthalmologica (Copenh)* 17: 279-296.
- Liebreich R (1859) Ophthalmoskopischer Befund bei Morbus Brightii. *Albrecht von Graefes Arch Ophthalmol* 5:265-268.
- Mylius K (1929) Spastische und tetanische Netzhautveränderungen bei der Eklampsie. Bericht über die Zusammenkunft. *Ophth Gesellsch Heidelberg*: 379-386.
- Keith NM, Wagener HP, Parker NW (1974) Some different types of essential hypertension: their course and prognosis. *Am J M Sci* 268: 336-345.
- Wong TY, Mitchell P (2004) Hypertensive retinopathy. *N Engl J Med* 351: 2310-2317.
- McGregor E, Isles CG, Jay JL, Lever AF, Murray GD (1986) Retinal changes in malignant hypertension. *Br Med J (Clin Res Ed)* 292: 233-234.
- Gunn M (1898) On ophthalmoscopic evidence of general arterial disease. *Trans Ophth Soc UK* 18: 356-381.
- Klein R, Klein BE, Moss SE, Wong TY, Hubbard L, et al. (2003) Retinal vascular abnormalities in persons with type 1 diabetes: the Wisconsin Epidemiologic Study of Diabetic Retinopathy: XVIII. *Ophthalmology* 110: 2118-2125.
- Goto I, Katsuki S, Ikui H, Kimoto K, Mimatsu T (1975) Pathological studies on the intracerebral and retinal arteries in cerebrovascular and noncerebrovascular diseases. *Stroke* 6: 263-269.

30. Wong TY, Klein R, Nieto FJ, Klein BE, Sharrett AR, et al. (2003) Retinal microvascular abnormalities and 10-year cardiovascular mortality: a population-based case-control study. *Ophthalmology* 110: 933-940.
31. Hayreh SS, Servais GE, Virdi PS (1986) Fundus lesions in malignant hypertension. IV. Focal intraretinal periarteriolar transudates. *Ophthalmology* 93: 60-73.
32. Cheung CY, Tay WT, Mitchell P, Wang JJ, Hsu W, et al. (2011) Quantitative and qualitative retinal microvascular characteristics and blood pressure. *J Hypertens* 29: 1380-1391.
33. Lee KA, Johnson MW (1999) Familial retinal venous tortuosity. *Ann Ophthalmol* 31: 313-317.
34. Gunn R (1892) Ophthalmoscopic evidence of (1) arterial changes associated with chronic renal disease, and (2) of increased arterial tension. *Trans Ophth Soc UK* 12: 124.
35. Kaushik S, Tan AG, Mitchell P, Wang JJ (2007) Prevalence and associations of enhanced retinal arteriolar light reflex: a new look at an old sign. *Ophthalmology* 114: 113-120.
36. Moser LA, Simpson DE, Young DD (1989) Retinal macroaneurysms: the natural history in four patients. *Optom Vis Sci* 66: 877-883.
37. (1991) Grading diabetic retinopathy from stereoscopic color fundus photographs--an extension of the modified Airlie House classification. ETDRS report number 10. Early Treatment Diabetic Retinopathy Study Research Group. *Ophthalmology* 98: 786-806.
38. Gottfredsdottir MS, Stefansson E, Jonasson F, Gislason I (1993) Retinal vasoconstriction after laser treatment for diabetic macular edema. *Am J Ophthalmol* 115: 64-67.
39. Masugata H, Senda S, Hoshikawa J, Okuyama H, Inukai M, et al. (2010) Differences between hypertensive and atherosclerotic lesions in retinal arteries assessed by Scheie's classification in hypertensive patients following stroke. *Clin Exp Hypertens* 32: 335-340.
40. Klein R, Sharrett AR, Klein BE, Chambless LE, Cooper LS, et al. (2000) Are retinal arteriolar abnormalities related to atherosclerosis?: The Atherosclerosis Risk in Communities Study. *Arterioscler Thromb Vasc Biol* 20: 1644-1650.
41. Gudmundsdottir H, Taarnhoj NC, Strand AH, Kjeldsen SE, Hoiegggen A, et al. (2010) Blood pressure development and hypertensive retinopathy: 20-year follow-up of middle-aged normotensive and hypertensive men. *J Hum Hypertens* 24: 505-513.

This article was originally published in a special issue, [Diabetic Retinopathy](#) handled by Editor(s). Dr. Caroline J Magri, Mater Dei Hospital, Malta