

## Rifampicin Induced Pigment Nephropathy: A Rare Case Report

Shetty M<sup>1</sup>, Chetan CS<sup>1\*</sup>, Prasad S<sup>1</sup>, Kiran KK<sup>1</sup>, Manoj C<sup>1</sup>, Shastry V<sup>2</sup>, Ranugha PSS<sup>2</sup>, Suchitha S<sup>3</sup>, and Vani K<sup>3</sup>

<sup>1</sup>Department of Nephrology, JSSAHER, India; <sup>2</sup>Department of Dermatology, JSSAHER, India; <sup>3</sup>Department of Pathology, JSSAHER, India

### ABSTRACT

**Introduction:** Rifampicin is one of the first lines drugs and forms the backbone for the treatment of tuberculosis and Hansen's disease. Although decreasing in incidence and prevalence, India still has a high burden of both the diseases necessitating the use of rifampicin. Major adverse effects of rifampicin are rare and renal involvement is even rare.

**Case report:** We report a thirty-seven-year-old lady who was on Directly observed therapy (DOT) therapy for borderline tuberculoid leprosy (bt) presenting with rapidly worsening renal failure due to rifampicin. Patient was supported by dialysis, renal functions improved in two weeks and patient had uneventful recovery.

**Conclusion:** Rifampicin induced nephrotoxicity should always be in our differential diagnosis when someone presents with renal failure while on rifampicin. Nephrotoxicity is more common while on intermittent rifampicin therapy. Early diagnosis and drug withdrawal are important for complete renal recovery.

**Keywords:** Rifampicin; Tuberculosis; Nephropathy

### INTRODUCTION

Rifampicin is one of the first lines drugs and forms the backbone for the treatment of Tuberculosis, Hansen's disease, atypical Mycobacteria and Staphylococcus infections. Rifampicin can cause adverse effects most of which are minor, very rarely it causes serious adverse events like hepatotoxicity, hemolysis, thrombocytopenia and AKI. One should have a high index of suspicion when renal failure develops in the context of using Rifampicin.

Renal manifestations are seen in patients who take Rifampicin intermittently or restart the drug after a long interval, rarely it is seen in those who are on daily rifampicin. AKI occurs in 0.1% patients using the drug, the common findings on renal biopsy are Acute interstitial nephritis, Acute tubular necrosis, Diffuse proliferative and Crescentic glomerulonephritis. We present a rare case of rifampicin induced Pigment Nephropathy.

### CASE REPORT

A thirty-Seven-year-old lady from rural India presented with an annular hypo- aesthetic plaque with central hypopigmentation of size 6 × 6 cm on the left forearm. She was diagnosed to have Hansen's-Borderline Tuberculoid. She was started on Paucibacillary multidrug therapy for Leprosy (PBMDT, Monthly Rifampicin 600 mg, 100 mg Dapsone daily). She was referred to Nephrology department after three months in view of passing reddish urine of one day duration which had already settled by the time, she came to us. This did not appear on the day following Rifampicin. On

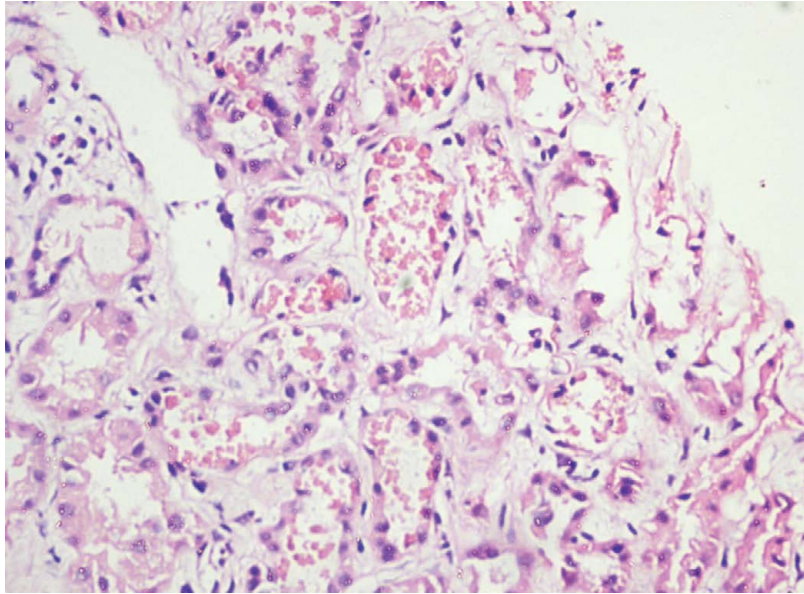
evaluation she had a Serum Creatinine of 0.9, No Urine albumin, Dipstick for blood Negative and microscopy was normal. Two weeks later she had recurrence of passing high colored urine but this time she complained of decreased appetite, Nausea, decreased urine output, edema and shortness of breath. On evaluation she had Blood Pressure 160/90 mmHg, Chest auscultation bilateral crackles, Urine showed Albumin 1+, Microscopy 15-20 RBC/hpf, 5-6 Pus cells, Urine blood Negative, Blood Urea 126 mg/dl, Serum Creatinine 5.5 mg/dl, Hb 10.0 G/dl (earlier Hb 11.5), TC 6890/μL, Platelet count 1.08 lakhs/μL, LDH 488( 135-214 U/L), SGOT 14 U/L, SGPT 18 U/L. Ultra-Sound Abdomen Normal. Patient was on intermittent Rifampicin which was restarted after a gap of two months, Other medication included clofazimine, although she was prescribed Dapsone patient had not been taking it. included daily clofazimine and Dapsone. The probable diagnosis was Acute Interstitial Nephritis and patient started on Hemodialysis followed by renal biopsy. It was an adequate specimen, All the glomeruli were normal, Tubules showed features of Acute Tubular Injury with heme pigment casts which appeared as coarse globular granules in chains and aggregates, there was mild interstitial edema, Immuno-Florescence was negative (Figures 1-3). Final diagnosis was Acute Kidney Injury- Pigment Nephropathy probably secondary to Rifampicin. Patient required dialysis for Ten days followed by improvement in the urine output and renal functions. Follow up after one-month patient was normotensive, Urine Nil Albumin and normal microscopy, Creatinine 0.9 mg/dl.

**Correspondence to:** Chetan CS, Department of Nephrology, JSSAHER, Mysore, India, E-mail: cshetan\_med@yahoo.co.in

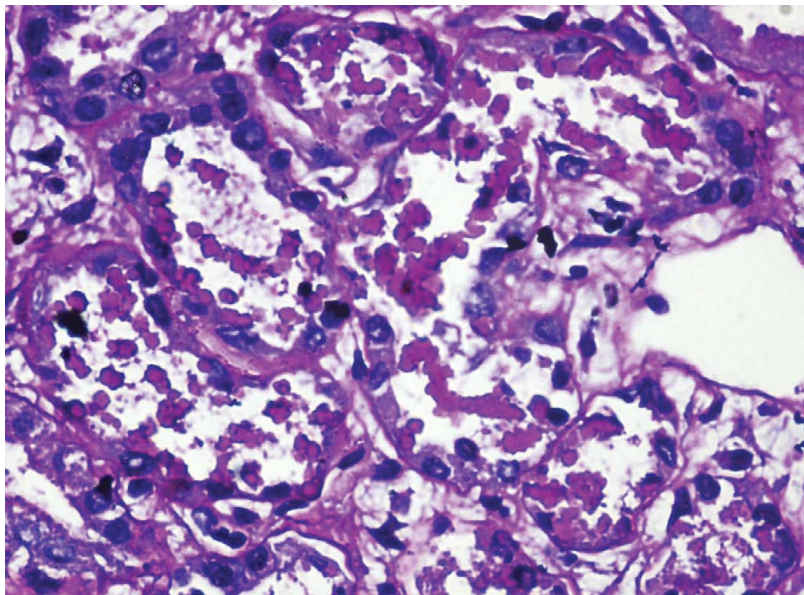
**Received:** January 15, 2020; **Accepted:** January 30, 2020; **Published:** February 06, 2020

**Citation:** Shetty M, Chetan CS, Prasad S, Kiran KK, Manoj C, Shastry V, et al. (2020) Rifampicin Induced Pigment Nephropathy: A Rare Case Report. J Kidney 6:178. doi-10.35248/2472-1220.20.6.178

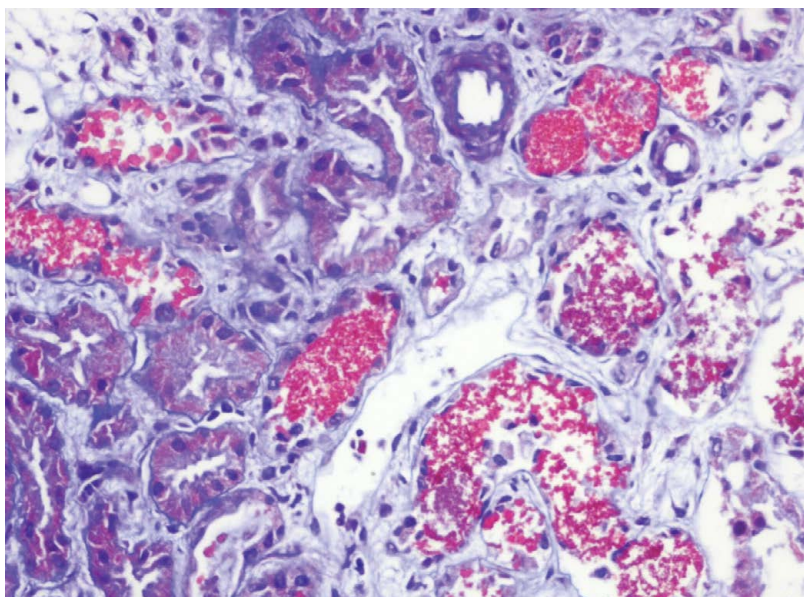
**Copyright:** ©2020 Shetty M, et al. This is an open-access article distributed under the terms of the Creative Commons Attribution License, which permits unrestricted use, distribution, and reproduction in any medium, provided the original author and source are credited.



**Figure 1:** Hematoxylin eosin stain 400X: pink to red colored casts.



**Figure 2:** PAS stain 400X: Casts seen as globules arranged in chain.



**Figure 3:** Mason's trichrome stain: Bright red casts in clusters and chain form.

## DISCUSSION

Rifampicin the most commonly used first line drug for the treatment of Tuberculosis and Leprosy has few adverse effects but serious adverse events like renal failure are rare [1]. It begins with flu-like illness after a median of 4 hours followed by Gastro-Intestinal symptoms. Anemia, Thrombocytopenia, Hepatitis and renal failure occur in severe cases. Renal toxicity include Acute Kidney Injury (usually due to Acute Interstitial Nephritis in 58%), other less common pathologic types include Acute Tubular Necrosis, Minimal change disease, Mesangial proliferative glomerulonephritis, Crescentic glomerulonephritis. A high index of suspicion is required when somebody on rifampicin develop renal manifestation, because many a times extra-renal features of drug toxicity are mild. Renal adverse effects like acute tubulointerstitial nephritis are typically seen with intermittent use or following re-introduction of the drug after a gap which can be 10 days to 6 years [2] rarely its seen with daily use of the drug for 8 days to 18 months [3]. In this patient rifampicin was started after a gap of two months. Adverse effects are hypothesized to the drugs immune-allergic effects [4] which may be type II or III hypersensitivity reaction in which anti-rifampicin antibodies forms immune complexes which deposit in the renal vessels, glomerular endothelium and interstitium [1,5]. Acute interstitial infiltrate and acute tubular necrosis can be the direct effects of this immune response. Rifampicin dependent IgG and IgM antibodies can cause red cell lysis through interaction with the I antigen on the erythrocyte surface. They also develop Thrombocytopenia and AKI due to intravascular hemolysis and Hemoglobinuria. The I antigen is also expressed on the tubular epithelial cells and anti-I antibodies can cause renal tubular cell destruction [6]. Most patients with AKI recover upon withdrawal of the drug [7], some may end up with proximal tubular defects leading to malabsorption of glucose, phosphorous, amino acids, potassium. There is evidence that steroids hasten renal recovery in drug induced acute interstitial nephritis [8]. Our case probably is Rifampicin induced intravascular hemolysis leading to Hemoglobinuria and renal failure. Rifampicin and its metabolites are chromogens and they normally cause orange reddish discoloration of urine and body fluids and this can be confused with Hemoglobinuria. where also the urine is discolored Dasone can also cause hemolysis but our patient had not been on dapson although it was advised by dermatologist.

[9]. Although Serum Haptoglobin, anti-rifampicin antibodies and immuoperoxide stain for Hemoglobin in biopsy specimen was not done, evidence favoring this is mild Anemia, thrombocytopenia and mildly elevated LDH. Our patient presented late with fully established acute renal failure.

## CONCLUSION

Rifampicin causes a wide range of renal adverse events especially when used as intermittent therapy and a high index of suspicion is required for early diagnosis and prompt initiation of therapy.

## REFERENCES

1. Manika K, Tasiopoulou K, Vlogiaris L, Lada M, Papaemmanouil S, Zarogoulidis K, et al. Rifampicin-associated acute renal failure and hemolysis: A rather uncommon but severe complication. *Ren Fail.* 2013;35(8):1179-1181.
2. Muthukumar T, Jayakumar M, Fernando EM, Muthusethupathi MA. Acute renal failure due to rifampicin: A study of 25 patients. *Am J Kidney Dis.* 2002;40(4):690-696.
3. Rosati S, Cherubini C, Iacomi F, Giannakakis K, Vincenzi L, Ippolito G, et al. Acute rifampicin-associated interstitial tubulopathy in a patient with pulmonary tuberculosis: A case report. *J Med Case Rep.* 2013 Dec;7(1):106.
4. Grosset J, Leventis S. Adverse effects of rifampin. *Rev Infect Dis.* 1983;5:440-446.
5. Rudraraju M, Parvathagiri V, Dugar M. Rifampin induced acute tubulo-interstitial nephritis: Rare event of commonly used drug. *J Case Rep.* 2017;7(2):133-135.
6. De Vriese AS, Robbrecht DL, Van holder RC, Vogelaers DP, Lameire NH. Rifampicin-associated acute renal failure: pathophysiologic, immunologic, and clinical features. *Am J Kidney Dis.* 1998;31(1):108-115.
7. Beebe A, Seaworth B, Patil N. Rifampicin-induced nephrotoxicity in a tuberculosis patient. *J Clin Tuberc Mycobact Dis.* 2015;1:13-5.
8. González E, Gutiérrez E, Galeano C, Chevia C, Sequera DP, Bernis C, et al. Early steroid treatment improves the recovery of renal function in patients with drug-induced acute interstitial nephritis. *Kidney Int.* 2008;73(8):940-946.
9. Morgan JR, Clarke KW, Brear SG. Phenomenon of rifampicin-induced discolouration of body fluids. *Respir Med.* 1993;87(4):320.