

Updates in Abdominal Wall Reconstruction

Garrido DE, Aponte YM, Behnam AB, Keeshin T, Sinha V, Evans KK and Salgado CJ*

Department of Plastic Surgery, University of Miami Miller School of Medicine, Miami, USA

Abstract

A wide variety of surgical options exist for abdominal wall reconstruction. Part of the key to success, however, consist on choosing the operation that will give the most functional and aesthetic result while focusing on measures to decrease the incidence of catastrophic complications and need for reoperation. In this article, we review reconstructive modalities for abdominal wall defects, with special attention to complex ventral hernias and components separation techniques. Our description of recent scientific advances and the emphasis on a multidisciplinary approach to patient care reflects current trend and going forward to the use of bioprosthetic materials.

Keywords: Bioprosthetic materials

Introduction

Revolutionary advances have been developed in the past 20 years with respect to abdominal wall reconstruction. Innovative Surgical approaches and new biological and prosthetic materials have become an integral part of the surgical arsenal. Patients with complex abdominal wall defects must be evaluated on an individual basis; interventions can vary from simple coverage and contouring to reconstruction of a dynamic functional abdominal wall. This article reviews abdominal wall reconstruction, with particular attention to ventral hernias, the components separation procedure, and use of bioprosthetic materials.

Abdominal Wall Embryology, Anatomy, and Function

The abdomen originates from the mesoderm of paravertebral region as bilateral sheets that migrate anteriorly and envelop the future abdominal [1]. Along with the rectus muscles, the external and internal oblique muscles and transverse muscles start to develop in the 6th to 7th week of gestation and their fascia encase the rectus abdominis muscles before these fuse in the midline. The leading edges of this sheet develop into the rectus abdominis muscles, which eventually meet in the midline anteriorly by week 12th.

Superiorly the abdomen is bound by the costal margins, inferiorly by the symphysis pubis and pelvic bones, and posteriorly by the vertebral column. Anatomic layers superficial to deep include: the subcutaneous tissue, superficial fat layer (Camper's fascia), deep fat layer (Scarpa's fascia), external oblique, internal oblique and transversus abdominis muscles, preperitoneal fat layer and peritoneum.

The anterior and lateral abdominal wall comprises a set of four paired muscles: the rectus abdominis, the external oblique, the internal oblique, and the transversus abdominis muscles. They are involved in the most obvious functions of the trunk: flexion, extension and rotation of the trunk and the pelvis; increase the intra-abdominal pressure for the aid of respiration, defecation, micturition, parturition and mechanisms of the inguinal canal and protect abdominal and retroperitoneal structures.

Rectus abdominis muscle fibers are arranged vertically and are encased within anterior and posterior leaves of an aponeurotic sheath, which are fused in the midline to form the *linea alba*. The rectus abdominis inserts on the symphysis and pubis crest inferiorly, and superiorly on the anteroinferior aspects of the fifth and sixth ribs and the seventh costal cartilages and the xiphoid process. The lateral border of the rectus muscles assumes a convex shape that gives rise to the *linea semilunaris*.

The external oblique muscle is the most superficial and largest of the anterolateral aspect of the abdominal wall. It originates in the lower eight ribs where it interdigitates with the serratus anterior and latissimus dorsi muscles; its fascicles originate superolaterally and are directed inferomedially inserting on the anterior half of the iliac crest. At its inferior-most aspect, the external oblique aponeurosis reflects posteriorly in between the anterosuperior iliac spine and pubic tubercle forming the inguinal ligament. Its aponeurosis passes anterior to the rectus abdominis muscle.

The internal oblique muscle lies immediately deep to the external oblique muscle and arises from the lateral aspect of the inguinal ligament, the iliac crest, and the thoracolumbar fascia. Its aponeurosis splits above the arcuate line to envelope the rectus abdominis. Below the arcuate line it passes anterior to the rectus abdominis. The lower fibers join those of the transverse abdominis muscle to form the conjoined tendon, which inserts on the pubic crest and spine and on the iliopectineal line. The inferior-most fibers of the internal oblique muscle are contiguous with the cremasteric muscle in the inguinal canal.

The *transversus abdominis muscle* is located deep in the internal oblique muscle. It is the deepest and smallest of the muscles of the lateral abdominal wall. It originates from the lower six ribs, lumbodorsal fascia, anterior two thirds of the iliac crest, and lateral third of the inguinal ligament. It inserts on the linea alba, contributes to the conjoined tendon, and inserts on the pubic spine and iliopectineal line.

The *pyramidalis muscle* is present in 80% to 90% of patients. It is a small triangular muscle that lies superficial to the rectus muscle. It arises from the front of the pubis and inserts on the linea alba halfway between the symphysis and umbilicus.

The blood supply to the abdominal wall is better described in relation to the area that is irrigated as described by Huger et al. [2] (Table 1).

***Corresponding author:** Christopher J. Salgado, Department of Plastic Surgery, University of Miami Miller School of Medicine, Miami, USA, E-mail: christophersalgado@med.miami.edu

Received January 16, 2013; **Accepted** January 29, 2013; **Published** January 31, 2013

Citation: Garrido DE, Aponte YM, Behnam AB, Keeshin T, Sinha V, et al. (2013) Updates in Abdominal Wall Reconstruction. Anaplastology 2: 104. doi: 10.4172/2161-1173.1000104

Copyright: © 2013 Garrido DE, et al. This is an open-access article distributed under the terms of the Creative Commons Attribution License, which permits unrestricted use, distribution, and reproduction in any medium, provided the original author and source are credited.

Zones	Territory	Supply
I	Midcentral abdominal wall above the umbilicus.	Deep epigastric arcade.
II	Lower abdominal wall below umbilicus.	Epigastric arcade, superficial inferior epigastric, superficial external pudendal and superficial circumflex.
III	Lateral abdominal wall.	Intercostal, subcostal, and lumbar arteries.

Table 1: Blood Supply to Abdominal Wall.

Abdominal Wall Defects

Abdominal wall defects may be congenital or acquired. This review focuses on the latter. Often, such defects manifest themselves as massive ventral hernias and result from prior abdominal operations, trauma or edema related loss of domain, massive infection, radiation necrosis, or tumor resection.

Prevention of evisceration, creation of a tension free abdominal wall repair with dynamic muscle support and stable soft tissue coverage are the goals of abdominal wall reconstruction.

Decisions regarding technique are based on an assessment of the overall clinical status of the patient, the location and size of the defect and well as extension of layers involved, and etiology.

Open primary tissue closure, open or laparoscopic prosthetic mesh placement, local advancement or regional flaps including the components separation technique, distant flaps, and combined flap and mesh techniques are the surgical approaches currently used. The choice of one approach over the other varies on a case-by-case basis as well as surgeon preference.

Ventral Hernias

The incidence of ventral hernias as a complication of abdominal operations has been reported as high as 20% [3].

Several conditions contribute to the development of incisional hernias such as: suture type, repair technique and tension, poor wound healing (often associated with poor patient nutrition), infection, increased intrabdominal pressure (e.g. due to COPD), and metabolic connective tissue disorder [4].

The most common indications for repair of abdominal wall hernias are generalized pain (68.7%) and cosmesis (54.6%). Other indications include the concern with risk of incarceration or strangulation and a massive or enlarging hernia.

Open techniques may range from simple herniorrhaphy, fascial plication, components separation, and mesh placement as an underlay, retrorectus or overlay.

Component Separation Techniques

Donald Young first described the release of the external oblique in 1960 [5]. Thirty years later, Ramirez et al. introduced the components separation technique (CST) which involved the release of the posterior rectus sheath in addition to the external oblique fascia [6]. This method uses bilateral, innervated, bipedicle, muscle flaps advanced medially to reconstruct the central abdominal wall defects. The components separation technique represents a landmark for the tissue transfer techniques used to repair complex abdominal midline defects [7].

The technique as described first exposes the anterior sheath of the rectus abdominis muscle and the aponeurosis of the external oblique muscle and the intervening linea semilunaris. The external oblique

aponeurosis is longitudinally transected lateral to the rectus sheath in a line extending from the costal margin to the pubis. The plane between the external oblique muscle and the internal oblique muscle is developed and the dissection is carried out laterally as far as possible. If needed, the posterior rectus sheath is also incised longitudinally, particularly beneficial in retrorectus placement of mesh (Figure 1). The fascia may be closed at the *linea alba* with a running or interrupted absorbable or non-absorbable suture [6,8].

Ideal candidates are those who have no pre-existing flank hernia, no prior injury to deeper fascial layers and existing rectus abdominis muscles.

In the first randomized control trial comparing wound complication and recurrence rates of intraperitoneal prosthetic mesh repair versus component separation technique, de Vries Reilingh et al., reported similar recurrence rates, hematoma, seroma and skin necrosis [9]. No superior results were reported for the mesh group in regards to wound infection requiring reoperation. However, less catastrophic complications, such as fistula formation, were reported in the CST group (Figure 2).

It is thought that such wound complications carried by CST are related to the division of rectus muscle perforator arteries that supply the overlying skin in the creation of the skin flap to find the

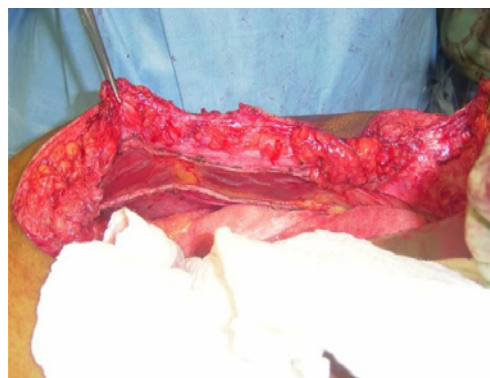

Figure 1: Posterior rectus sheath release used for retro rectus implantation of mesh and to obtain additional length in advancement of the rectus in conjunction with the external oblique release.

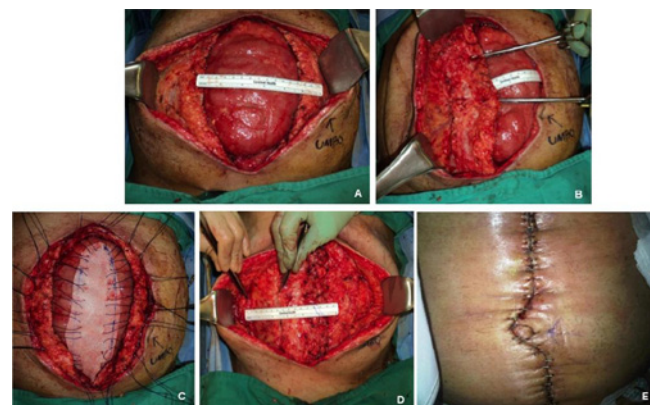


Figure 2: Case of a 42 year old male with an open abdomen due to large ventral hernia after an atypical lipoma resection. A. Large ventral hernia. B. Unilateral right side component separation was done giving a 7 cm release to the midline. C. Biologic porcine skin mesh. D. Tension free fascial closure. E. Final closure.

linea semilunaris. Therefore improvement of the blood supply to the abdominal skin flaps is fundamental to primary midline wound healing [10] and only those perforators that are absolutely necessary for exposure are ligated.

Subsequently, Saulis and Dumanian described a technique that preserved the periumbilical rectus abdominis perforators to the overlying skin flaps. In their retrospective review they observed a decreased in overall wound complications to 7% when compared to the 31% of the conventional approach [11].

Endoscopic separation of components has been described, where, based on the same concept of preserving the perforators, the external oblique aponeurosis is released with the aid of an endoscope and balloon dissector via small separate anterolateral cut down incisions [12].

Supplemental mesh placement is under the discretion of the surgeon, however in another study by Dumanian primary components separation (n=158) yielded a 22.8% recurrence rate. Closure of the midline tissues with augmentation of the repair using acellular dermis underlay (n=18) had 0% recurrence (p=0.04) [13].

More recently, further modification of perforator sparing concept on CST has been described for patients with complex and large defects as well: The minimally invasive component separation technique with inlay bioprosthetic mesh [14]. In this interesting repair, the external oblique is released via the same midline incision after being exposed and incised through a limited skin flap over the rectus. Using a suction head, the external oblique is elevated from the internal oblique and then incision is extended caudally and cranially via that limited window. The repair was described with a placement of inlay bioprosthetic mesh. A retrospective comparison of this technique compared with the conventional CST resulted in fewer wound related complications (14% over 32%) and similar recurrence rate. However this review has its flaws such as longer follow up time in the CST group and potential selection bias [14].

Mesh

The primary choice of repair of these hernias whether open or laparoscopic with or without mesh is a topic of debate, however most surgeons believe prosthetic mesh repair is the standard of care for the non complex hernia patient with a fascial defect greater than 2 cm.

There are a limited number of randomized control trials that support the use of prosthetic mesh over primary repair. The literature suggests that prosthetic mesh repair has been associated with less recurrence rates but with higher incidences of wound infection when compared to primary repair for non complex hernias with defects sizing 6 cm or less [8,15]. Moreover, there is no evidence which type of mesh is superior for the repair [8]. Types of mesh are covered below.

Prosthetic material is commonly used for structural support of the abdominal wall or as a bridge to definite treatment in a planned open abdomen or in light of an infected wound. The use of prosthetic material is relatively contraindicated in cases of wound infection. Also, the inability to interpose omentum between mesh and bowel also makes the use of prosthetic mesh unfavorable [9].

Ideally, this prosthetic material should meet certain criteria prior to its use. They should be resistant to mechanical forces and durable. As any other foreign materials to be utilized in the body, it should be chemically inert in order to reduce inflammatory response and be capable of host tissue incorporation. It should also be shapeable.

The two most commonly used prosthetic materials are polypropylene and expanded polytetrafluoroethylene (ePTFE).

Expanded polytetrafluoroethylene (Gore-Tex, W.L. Gore and Associates, Flagstaff, Arizona) has a microporous structure that minimizes cellular infiltration and tissue incorporation. It is equivalent to polypropylene in terms of suture retention strength. As a result of its flexibility, conforming nature, and minimal tissue ingrowth, ePTFE can be placed directly on bowel. The material is virtually impenetrable, preventing host tissue ingrowth and often leading to seroma formation.

Synthetic mesh offers high tensile strength, however it is associated with chronic inflammatory response and scar formation that subsequently promotes visceral tissue ingrowth into mesh porosities that can lead to complications such as adhesions to the mesh, bowel obstruction, and enterocutaneous fistula [16].

Therefore in clinical situations such as acute repair of incarcerated hernias with spillage of enteric contents, or mesh infections prosthetic mesh use is not advised [14,16].

Dual characteristic with absorbable and nonabsorbable prosthesis have been developed in order to reduce the above mentioned prosthesis related complications, however there is not enough data to support their use over the traditional ones.

In the past decade, the use of acellular dermal matrix for soft tissue reinforcement has been popularized for the use of abdominal wall reconstruction as a substitute for flaps, failed prosthetic repair and complex hernias where prosthesis is not advised. These products consist of human (allograft) and animal (xenograft) products in the form of acellular dermal matrix and submucosa [16].

Among bioprosthesis characteristics are resistance to infection, biocompatibility to human tissue, tolerance to cutaneous exposure, and mechanical stability. Furthermore these products have less potential for bowel adherence and infection development and are ideal alternatives to prosthetic mesh implants in recurrent or complicated repairs. For such reasons they have become a popular and reliable option for hernia repair over the recent years (Figure 3). Due to lack of

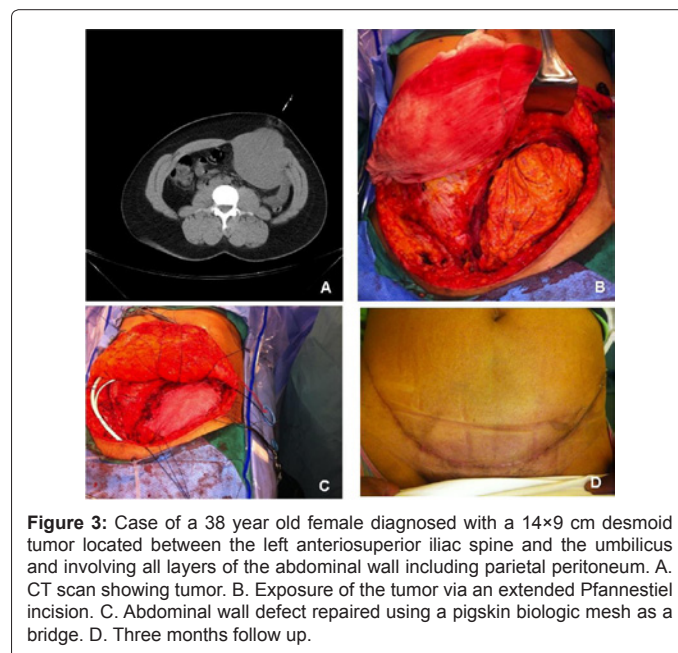


Figure 3: Case of a 38 year old female diagnosed with a 14x9 cm desmoid tumor located between the left anterosuperior iliac spine and the umbilicus and involving all layers of the abdominal wall including parietal peritoneum. A. CT scan showing tumor. B. Exposure of the tumor via an extended Pfannenstiel incision. C. Abdominal wall defect repaired using a pigskin biologic mesh as a bridge. D. Three months follow up.

Product	Properties
Porcine	
Permacol Covidien	Chemically-cross-linked. Large sizes; no refrigeration or rehydration; large reported clinical experience. Concern for increased foreign body reaction due to heavy cross-linking.
Strattice LifeCell	Non-cross-linked; Terminally sterilized. Few clinical experiences.
BioDesign Cook	Modified intestinal submucosal matrix; Non-cross-linked. No refrigeration. Reports of enzymatic degradation.
Xenmatrix Bard/Davol	Non-cross-linked; Electron beam sterilized. No rehydration; Few clinical experiences.

Table 2: Commonly Used Biomaterials for Abdominal Wall Reconstruction.

Muscle flaps
Rectus abdominis
Rectus femoris
Mutton chop flap (rectus femoris + fascia of the thigh)
Tensor fascia lata
Internal oblique
External oblique
Vastus lateralis
Fasciocutaneous Flaps
Anterolateral thigh flap
Deep inferior epigastric – based (island)
Groin flap

Table 3: Common Tissue flaps.

larger comparative trials there is no evidence that one mesh is better than the other [16].

These products consist of an acellular collagen matrix that promotes host tissue remodeling while maintaining mechanical integrity. They differ in that they heal by a regenerative process rather than by scar tissue formation. Disadvantages are their high cost and the lack of long-term follow-up studies validating their use.

Xenografts have larger and thicker available sizes and the favorable viscoelastic properties in these products and the trend has shifted to use products for abdominal wall reconstruction *in lieu* of allografts [16]. Moreover, abdominal wall reconstructions with allograft have been found to have a very unacceptable degree of bulging and recurrence at long term as compared with the ones where prosthetic mesh is used [17,18].

Materials such as human acellular dermis (AlloDerm, LifeCell, Branchburg, New Jersey), porcine acellular dermis (Permacol, Covidien), and Strattice, (LifeCell), and porcine small intestinal submucosa (BioDesign, Cook Surgical Incorporated, Bloomington, Indiana) are commonly used biomaterials, however, xenografts are at this point the only validated options for abdominal wall reconstruction [19] (Table 2).

Types of Flaps

Table 3 summarizes the type of flaps:

The rectus femoris is a large and reliable flap with consistent anatomy and a broad arc of rotation. It is ideal for low anterior pelvic reconstruction when other options are not feasible. When pedicled, there is no need for microvascular anastomosis as this flap has a robust blood supply [20]. Donor site has minimal morbidity.

Extended rectus femoris myocutaneous flap (the mutton chop flap) allows for reconstruction of large full-thickness epigastric abdominal wall defects as described initially, or the entire sacral and perineal area, without prosthetic material [21,22].

The tensor fascia lata (TFL) has been extensively described for not only is an ideal reconstructive option for abdominal wall defects that can also be used as musculocutaneous flap. The flap can be used to resurface the entire suprapubic region, lower abdominal quadrants, or ipsilateral abdomen with minimal donor deficit. Donor site from narrow flaps can be closed primarily; larger than 8 cm may need skin grafting (Figure 4). The transverse branch of the lateral femoral circumflex vessels arising from the profunda femoris, pierces the medial aspect of the flap 8 to 10 cm below the anterosuperior iliac spine as the vascular pedicle.

The omentum can also be used as a flap to cover the entire abdominal wall and perineal areas. It can be used with mesh and provides a good bed for a skin graft.

Contouring Procedures in Combination with Hernia Repair

More often than not larger ventral hernias cause the overabundance of or sagging overlying skin, stretch marks, scar and on extremes cases necrosis. Abdominal wall contouring procedures can be performed additionally at the time of the hernia repair, as the goal is to restore an aesthetic shape to the wall.

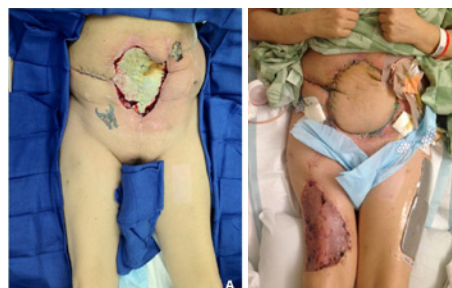

Figure 4: Anterolateral thigh flap used in patient for combined fascial and skin coverage in this patient with multiply recurrent ventral hernias after failed prosthetic, CST and biologic mesh.

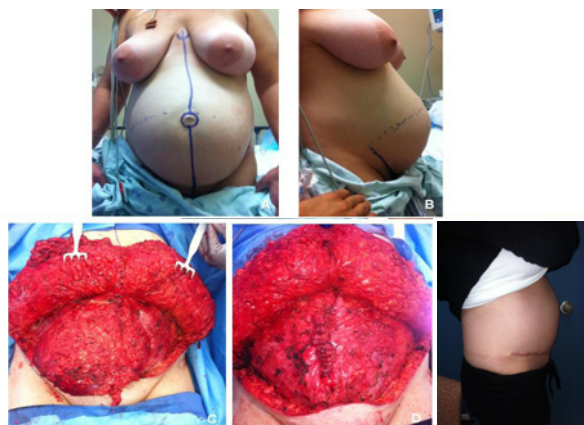

Figure 5: Case of a 36 years old female a year after postpartum with development of rectus diastasis. A and B. Anterior and lateral views. C. Exposure via extended Pfannestiel incision. D. Repair using a rectus plication technique. E. Procedure completed with and abdominoplasty.

Small evidence from morbid obese patients that have lost significant amount of weight after undergoing bariatric procedure, and concomitantly have an incisional hernia, suggest that hernia repair and abdominoplasty can be performed simultaneously with acceptable outcomes [23]. This procedure is most appropriate for patients who are already at their ideal sustainable weight. It also eliminates the need of a second surgery and the risk of anesthesia (Figure 5).

Adding to the advantage of performing abdominoplasty to the ventral hernia repair is that the exposure obtained through an extended Pfannestiel incision is superior to the standard midline incision [24]. After flaps are elevated, a thorough examination of the entire abdominal wall can be performed, including component separation technique as described by Mazzocchi et al. [25]. Decreased tension is placed on the repair as a result of the removal of the heavy weight of the pannus and this may decrease the recurrent rate for this hernias.

Complications associated with abdominoplasty occur primarily in patients who are smokers, morbid obese, frail, diabetics. In addition to the general postoperative complications such as bleeding, wound infection, delayed wound healing, skin or fat necrosis, numbness to abdominal region or thighs can occur.

References

1. Sadler TW (2010) The embryologic origin of ventral body wall defects. *Semin Pediatr Surg* 19: 209-214.
2. Huger WE Jr (1979) The anatomic rationale for abdominal lipectomy. *Am Surg* 45: 612-617.
3. Höer J, Lawong G, Klinge U, Schumpelick V (2002) Factors influencing the development of incisional hernia. A retrospective study of 2,983 laparotomy patients over a period of 10 years. *Chirurg* 73: 474-480.
4. Klinge U, Si ZY, Zheng H, Schumpelick V, Bhardwaj RS, et al. (2000) Abnormal collagen I to III distribution in the skin of patients with incisional hernia. *Eur Surg Res* 32: 43-48.
5. Young D (1961) Repair of epigastric incisional hernia. *Br J Surg* 48: 514-516.
6. Ramirez OM, Ruas E, Dellon AL (1990) "Components separation" method for closure of abdominal-wall defects: an anatomic and clinical study. *Plast Reconstr Surg* 86: 519-526.
7. Shestak KC, Edington HJ, Johnson RR (2000) The separation of anatomic components technique for the reconstruction of massive midline abdominal wall defects: anatomy, surgical technique, applications, and limitations revisited. *Plast Reconstr Surg* 105: 731-738.
8. den Hartog D, Dur AH, Tuinebreijer WE, Kreis RW (2008) Open surgical procedures for incisional hernias. *Cochrane Database Syst Rev*: CD006438.
9. de Vries Reilingh TS, van Goor H, Charbon JA, Rosman C, Hesselink EJ, et al. (2007) Repair of giant midline abdominal wall hernias: "components separation technique" versus prosthetic repair. *World J Surg* 31: 756-763.
10. Ghali S, Turza KC, Baumann DP, Butler CE (2012) Minimally invasive component separation results in fewer wound-healing complications than open component separation for large ventral hernia repairs. *J Am Coll Surg* 214: 981-989.
11. Saulis AS, Dumanian GA (2002) Periumbilical rectus abdominis perforator preservation significantly reduces superficial wound complications in "separation of parts" hernia repairs. *Plast Reconstr Surg* 109: 2275-2280.
12. Rosen MJ, Jin J, McGee MF, Williams C, Marks J, et al. (2007) Laparoscopic component separation in the single-stage treatment of infected abdominal wall prosthetic removal. *Hernia* 11: 435-440.
13. Ko JH, Wang EC, Salvay DM, Paul BC, Dumanian GA (2009) Abdominal wall reconstruction: lessons learned from 200 "components separation" procedures. *Arch Surg* 144: 1047-1055.
14. Butler CE, Campbell KT (2011) Minimally invasive component separation with inlay bioprosthetic mesh (MICSIB) for complex abdominal wall reconstruction. *Plast Reconstr Surg* 128: 698-709.
15. Burger JW, Luijendijk RW, Hop WC, Halm JA, Verdaasdonk EG, et al. (2004) Long-term follow-up of a randomized controlled trial of suture versus mesh repair of incisional hernia. *Ann Surg* 240: 578-583.
16. Beale EW, Hoxworth RE, Livingston EH, Trussler AP (2012) The role of biologic mesh in abdominal wall reconstruction: a systematic review of the current literature. *Am J Surg* 204: 510-517.
17. Blatnik J, Jin J, Rosen M (2008) Abdominal hernia repair with bridging acellular dermal matrix—an expensive hernia sac. *Am J Surg* 196: 47-50.
18. Smart NJ, Marshall M, Daniels IR (2012) Biological meshes: a review of their use in abdominal wall hernia repairs. *Surgeon* 10: 159-171.
19. Hsu PW, Salgado CJ, Kent K, Finnegan M, Pello M, et al. (2009) Evaluation of porcine dermal collagen (Permacol) used in abdominal wall reconstruction. *J Plast Reconstr Aesthet Surg* 62: 1484-1489.
20. Flurry MD, Michelotti BF, Moyer KE (2011) Pedicled rectus femoris flap for coverage of complex open pelvic fractures. *J Plast Reconstr Aesthet Surg* 64: 1490-1494.
21. Dibbell DG Jr, Mixer RC, Dibbell DG Sr (1991) Abdominal wall reconstruction (the "mutton chop" flap). *Plast Reconstr Surg* 87: 60-65.
22. Vogt PM, Kall S, Lahoda LU, Spies M, Muehlberger T (2004) The free "mutton chop" flap: a fascio-musculocutaneous flap for the reconstruction of the entire sacral and perineal area. *Plast Reconstr Surg* 114: 1220-1224.
23. Shermak MA (2006) Hernia repair and abdominoplasty in gastric bypass patients. *Plast Reconstr Surg* 117: 1145-1150.
24. Berhane C, Salgado CJ, Avashia Y, Villadolid D, Moller M (2012) Abdominal Desmoid Tumor Excision through an Extended Pfannenstiel Incision. *Am Surg* 78: 541-543.
25. Mazzocchi M, Dessy LA, Ranno R, Carlesimo B, Rubino C (2011) "Component separation" technique and panniculectomy for repair of incisional hernia. *Am J Surg* 201: 776-783.